
**U.S. ARMY MEDICAL DEPARTMENT CENTER AND SCHOOL
FORT SAM HOUSTON, TEXAS 78234-6100**



PARASITOLOGY II

SUBCOURSE MD0842 EDITION 200

DEVELOPMENT

This subcourse is approved for resident and correspondence course instruction. It reflects the current thought of the Academy of Health Sciences and conforms to printed Department of the Army doctrine as closely as currently possible. Development and progress render such doctrine continuously subject to change.

ADMINISTRATION

For comments or questions regarding enrollment, student records, or shipments, contact the Nonresident Instruction Section at DSN 471-5877, commercial (210) 221-5877, toll-free 1-800-344-2380; fax: 210-221-4012 or DSN 471-4012, e-mail accp@amedd.army.mil, or write to:

COMMANDER
AMEDDC&S
ATTN MCCS HSN
2105 11TH STREET SUITE 4192
FORT SAM HOUSTON TX 78234-5064

Approved students whose enrollments remain in good standing may apply to the Nonresident Instruction Section for subsequent courses by telephone, letter, or e-mail.

Be sure your social security number is on all correspondence sent to the Academy of Health Sciences.

CLARIFICATION OF TRAINING LITERATURE TERMINOLOGY

When used in this publication, words such as "he," "him," "his," and "men" are intended to include both the masculine and feminine genders, unless specifically stated otherwise or when obvious in context.

USE OF PROPRIETARY NAMES

The initial letters of the names of some products are capitalized in this subcourse. Such names are proprietary names, that is, brand names or trademarks. Proprietary names have been used in this subcourse only to make it a more effective learning aid. The use of any name, proprietary or otherwise, should not be interpreted as an endorsement, deprecation, or criticism of a product; nor should such use be considered to interpret the validity of proprietary rights in a name, whether it is registered or not.

TABLE OF CONTENTS

<u>Lesson</u>		<u>Paragraphs</u>
	INTRODUCTION	
1	PHYLUM PROTOZOO: RHIZOPODA AND ZOOMASTIGOPHORA	
	Section I. Overview of Protozoo	1-1--1-4
	Section II. Class Rhizopoda	1-5--1-8
	Section III. Class Zoomastigophora.....	1-9--1-11
	Exercises	
2	PHYLUM PROTOZOO: CILIATA, PIROPLASMASIDA, AND SPOROZOA	
	Section I. Class Ciliata	2-1--2-3
	Section II. Class Piroplasmiasida	2-4--2-6
	Section III. Class Sporozoa	2-7--2-12
	Exercises	
3	PHYLUM PLATYHELMINTHES	
	Section I. Overview of Platyhelminthes	3-1--3-4
	Section II. Class Trematoda	3-5--3-7
	Section III. Class Cestoda	3-8--3-10
	Exercises	
4	PHYLUM ASCHELMINTHES: PHYLUM ACANTHOCEPHAHELMINTHES: ARTHROPODS AND VECTORS	
	Section I. Phylum Aschelminthes	4-1--4-3
	Section II. Phylum Acanthocephalhelminthes	4-4--4-5
	Section III. Arthropods and Vectors.....	4-6--4-7
	Exercises	
	APPENDIX A: Clinical Manifestations and Treatment of the Common Parasitic Diseases	
	APPENDIX B: References	
	APPENDIX C: Medical Parasitology	

**CORRESPONDENCE COURSE OF
THE U.S. ARMY MEDICAL DEPARTMENT CENTER AND SCHOOL**

SUBCOURSE MD0842

PARASITOLOGY II

INTRODUCTION

The focus of this subcourse is the identification forms and life cycles of parasites which infect humans. Organisms which will be discussed include parasitic members of Phylum Protozoo, Platyhelminthes, Aschelminthes, and Acanthocephahelminthes. You will be provided with descriptions of the general characteristics of the phylum and detailed illustrations of the cycle forms of significant members of the phylum.

This subcourse is the second of two subcourses which discuss parasitology. In Parasitology I, an overview of parasitology and information for the collection, preservation, and processing of clinical specimens were presented. The material provided in this subcourse will build on that information. It contains information that will help you gain knowledge and skill in the identification of human parasites. It does not attempt to cover parasitology in depth but is only intended to guide you toward becoming competent in the field. For your further learning a bibliography of supplemental sources of parasitology information is included in Appendix B.

Subcourse Components:

The subcourse instructional material consists of four lessons and three appendixes as follows:

- Lesson 1, Phylum Protozoo: Rhizopoda and Zoomastigophora.
- Lesson 2, Phylum Protozoo: Ciliata, Piroplasmaida, and Sporozoa.
- Lesson 3, Phylum Platyhelminthes.
- Lesson 4, Phylum Aschelminthes; Phylum Acanthocephahelminthes; Arthropods and Vectors.
- Appendix A, Clinical Manifestations and Treatment of the Common Parasitic Diseases.
- Appendix B, References
- Appendix C, Medical Parasitology

--Complete the subcourse lesson by lesson. After completing each lesson, work the exercises at the end of the lesson

--After completing each set of lesson exercises, compare your answers with those on the solution sheet that follows the exercises. If you have answered an exercise incorrectly, check the reference cited after the answer on the solution sheet to determine why your response was not the correct one.

Credit Awarded:

Upon successful completion of the examination for this subcourse, you will be awarded 12 credit hours.

To receive credit hours, you must be officially enrolled and complete an examination furnished by the Nonresident Instruction Section at Fort Sam Houston, Texas.

You can enroll by going to the web site <http://atrrs.army.mil> and enrolling under "Self Development" (School Code 555).

LESSON ASSIGNMENT

LESSON 1

Phylum Protozoo: Rhizopoda and Zoomastigophora.

LESSON ASSIGNMENT

Paragraphs 1-1 through 1-11.

LESSON OBJECTIVES

After completing this lesson, you should be able to:

- 1-1. Identify the general characteristics of protozoans.
- 1-2. Identify the organism characteristics of parasitic members of Class Rhizopoda.
- 1-3. Select a statement that best describes the life cycle of a member of Class Rhizopoda.
- 1-4. Identify the organism characteristics of parasitic members of Class Zoomastigophora.
- 1-5. Select a statement that best describes the life cycle of a member of Class Zoomastigophora.
- 1-6. Identify the specimen of choice for recovery of specific protozoan organisms.
- 1-7. Identify the special technique required for recovery of specific protozoan organisms.

SUGGESTION

After completing the assignment, complete the exercises of this lesson. These exercises will help you to achieve the lesson objectives.

LESSON 1

PHYLUM PROTOZOO: RHIZOPODA AND ZOOMASTIGOPHORA

Section I. OVERVIEW OF PROTOZOO

1-1. GENERAL COMMENTS

Protozoans are unicellular (one-celled) organisms which belong to the subkingdom Eucaryota. They vary in size from almost submicroscopic to 120 micrometers (μ) in diameter. Each protozoan is a complete organism capable of carrying out the same physiological functions performed by many cells in a more complex organism. There are specialized and complex organelles found in protozoans which perform the functions of locomotion, metabolism, and reproduction. It has been suggested that instead of unicellular, the protozoan organisms should be termed acellular because of the intricacy of their functions and also because some of these organisms have more than one nuclei. The members of this phylum which are parasitic to humans, while preserving the general characteristics of their free living counterparts, are capable of survival in the adverse system of the host.

1-2. HISTORY

Some protozoans are beneficial to mankind by being part of the food chain and by serving as experimental subjects. Others have adapted well to a parasitic existence causing many diseases in humans. Much has been discovered about protozoans since Anton van Leeuwenhoek first saw the cysts of *Giardia lamblia* from his own stool and reported them to the Royal Academy in his treatise "Wee besties." His discoveries occurred in the late 1600's.

1-3. STRUCTURE

The various forms and functions of protozoan cells are truly amazing for what we consider as simple single-celled organisms. Whether they are amoeba, flagellates, or ciliates, they contain ultramicroscopic organelles that enable them to perform many of the activities observed in higher animals. However, the most easily recognized and identifiable structure within the protozoan cell is the nucleus. Nuclei among the protozoa usually are of two types, the vesicular nucleus with a clearly defined internal space, and the compact nucleus which appears to be a solid mass. Most of the protozoa which parasitize humans exhibit the vesicular type. Because nuclear chromatin components can be stained and easily observed within the vesicular nucleus, the arrangement of the chromatin, whether dispersed or condensed, is helpful in differentiation of the species within certain classes of the Protozoo. See figures 1-1 and 1-2.

1-4. PARASITIC PROTOZOO

Within the phylum Protozoo, there are five classes which contain organisms parasitic to man. The classes are: Rhizopoda, Zoomastigophorai Ciliata, Piroplasmaida, and Sporozoa. The identification forms and life cycles of Rhizopoda and Zoomastigophora will be described in this lesson. Ciliata, Piroplasmaida, and Sporozoa will be described in Lesson 2.

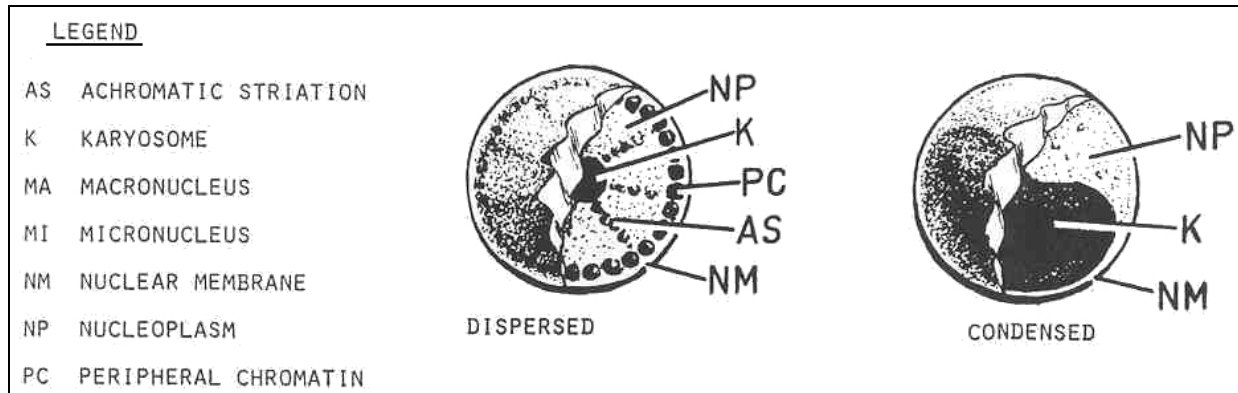


Figure 1-1. Vesicular nucleus.

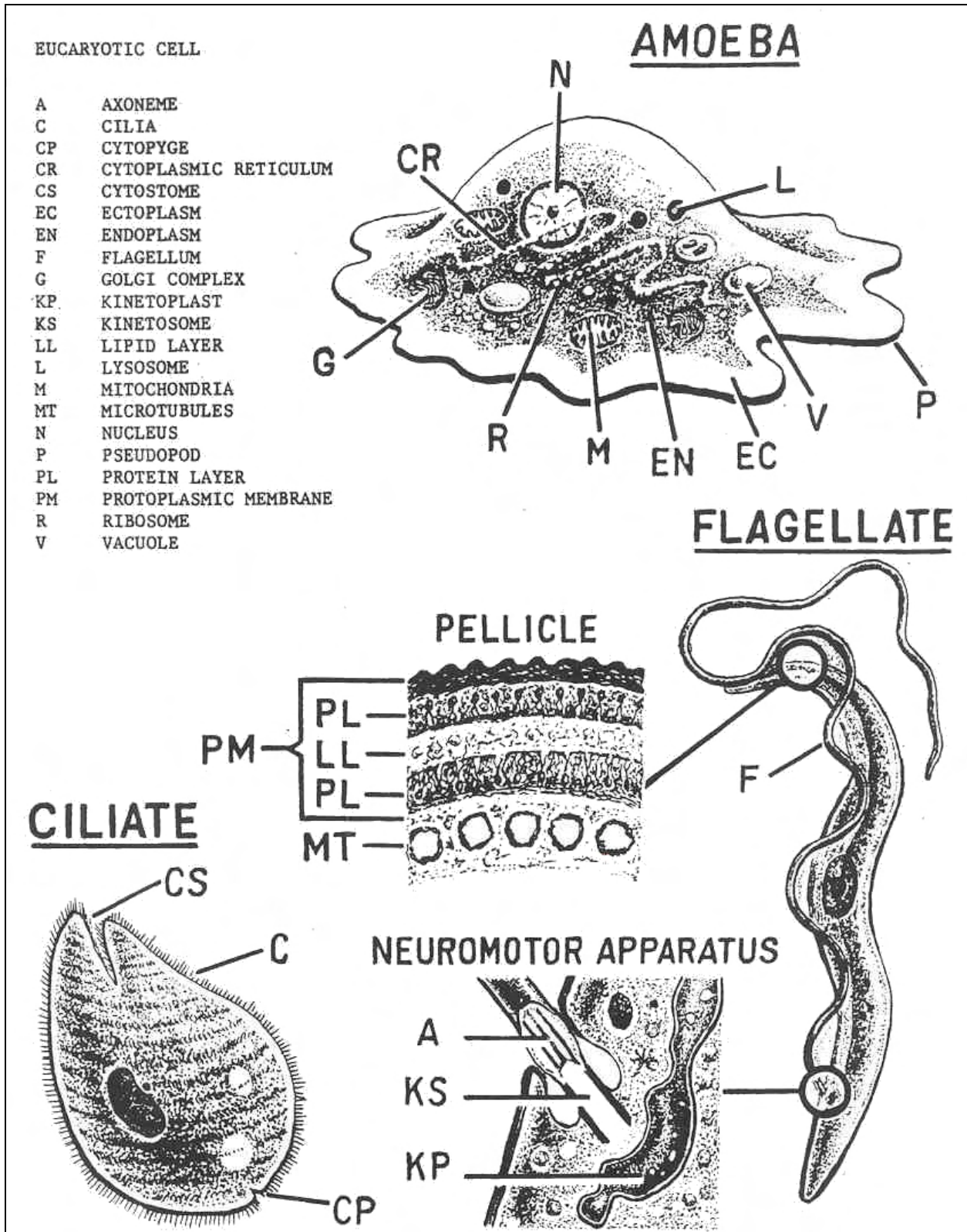


Figure 1-2. Typical protozoan organisms.

Section II. CLASS RHIZOPODA

1-5. GENERAL DESCRIPTION

Members of this class include protozoans which use pseudopodia (false feet) for locomotion. There are many species of this class that are free living and therefore will not be discussed here. The attention is focused instead on those organisms which are parasites of man. There are six genera recognized as human parasites. These include the pathogens: *Entamoeba histolytica* and *Naegleria fowleri*, and some species of the genera *Acanthamoeba* and *Hartmannella*, as well as commensal organisms from the genera: *Entamoeba*, *Endolimax*, and *Iodamoeba*. One commensal amoeba, *Entamoeba gingivalis*, is found in the mouth of mammals.

1-6. LOCOMOTION AND DIGESTION

Locomotion and ingestion are accomplished by the use of the pseudopodia. Once the food substance is contained within the cell, the organism goes through the processes of enzymatically breaking down and absorbing the nutrients. Egestion of unused residue is performed by the expulsion of the vacuole out of the cell.

1-7. RESPIRATION AND REPRODUCTION

Respiration is performed by simple absorption of dissolved oxygen from the liquid environment. Excretion of gases and waste is performed by diffusion out of the organism through the cell membrane. Liquid regulation inside the body is controlled by contractile vacuoles which serve as two-way pumps that control the hydrostasis between the organism and the environment. These organisms reproduce through asexual reproduction consisting of simple cell division.

1-8. AMOEBIC STATES

The amoebic organisms exist in two states. The vegetative state is called the trophozoite. This is the metabolic stage of the protozoan which is very sensitive to the changes of the environment. As unfavorable conditions set in, the organisms go through a process called encystation. The cyst is the resistant state or stage of the amoebic organisms. Excystation takes place with the return of favorable conditions. Some species in this class also use the encystation process for the purpose of reproduction. In this case one cyst yields more than one organism. See figure 1-3.

NOTE: See figures 1-4 through 1-24 for information on specific organisms.

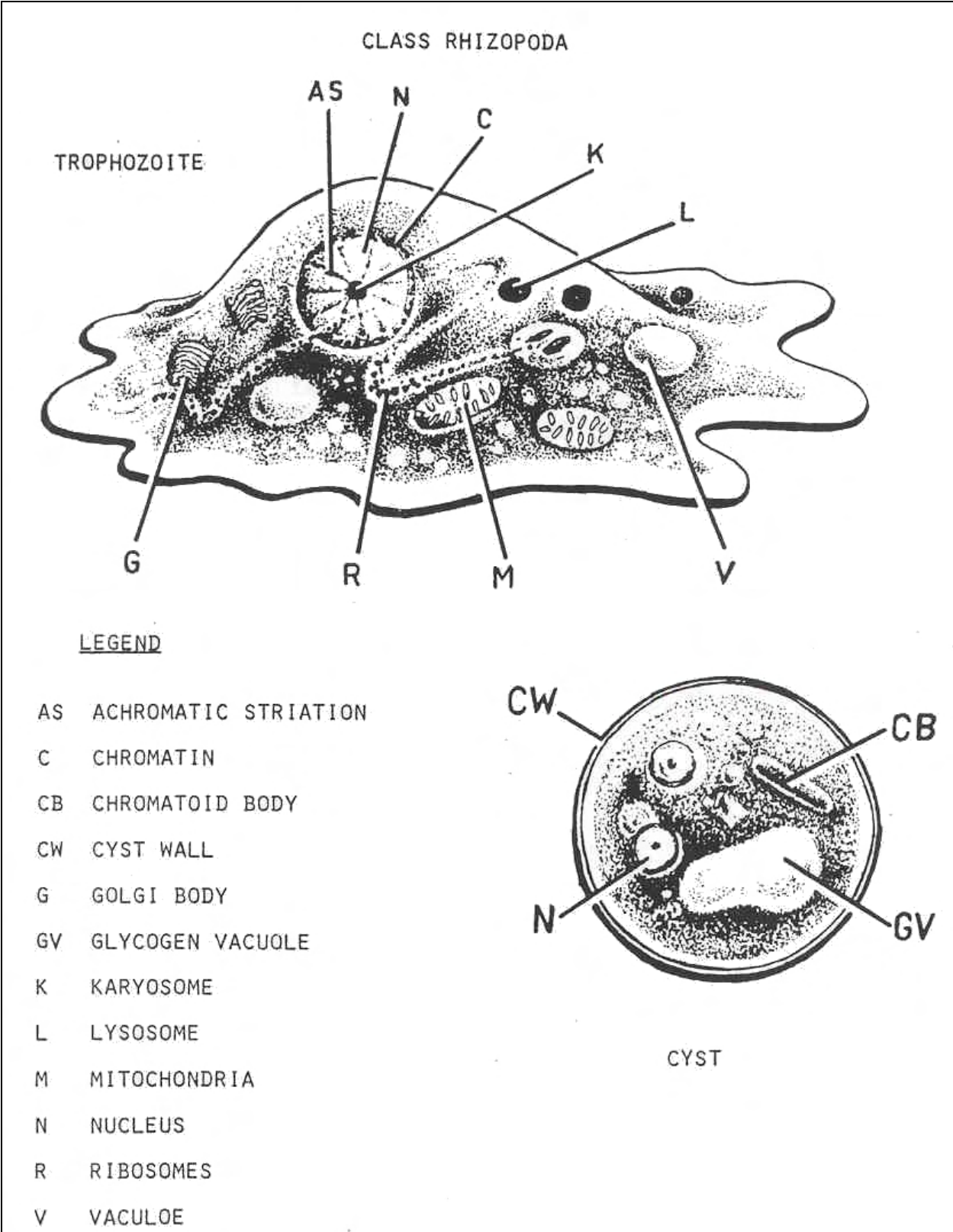


Figure 1-3. Rhizopadan stages.

ORGANISM 1 -- Entamoeba histolytica

GENERAL CHARACTERISTICS

COMMON NAME: Montezuma's revenge.

GEOGRAPHICAL DISTRIBUTION: Cosmopolitan prevalent in the tropics and subtropics.

PATHOGENESIS: Pathogenic.

HABITAT

Primary Site: Intestinal mucosa (colon).

Secondary Site: Liver, lungs, brain.

INTERMEDIATE HOST: None.

RESERVOIR HOST: Other mammals.

INFECTED FORM: Mature quadrinucleated cyst.

MODE OF INFECTION: Ingestion.

LABORATORY IDENTIFICATION:

SPECIMEN SOURCE: Feces.

Figure 1-4. Information on Entamoeba histolytica.

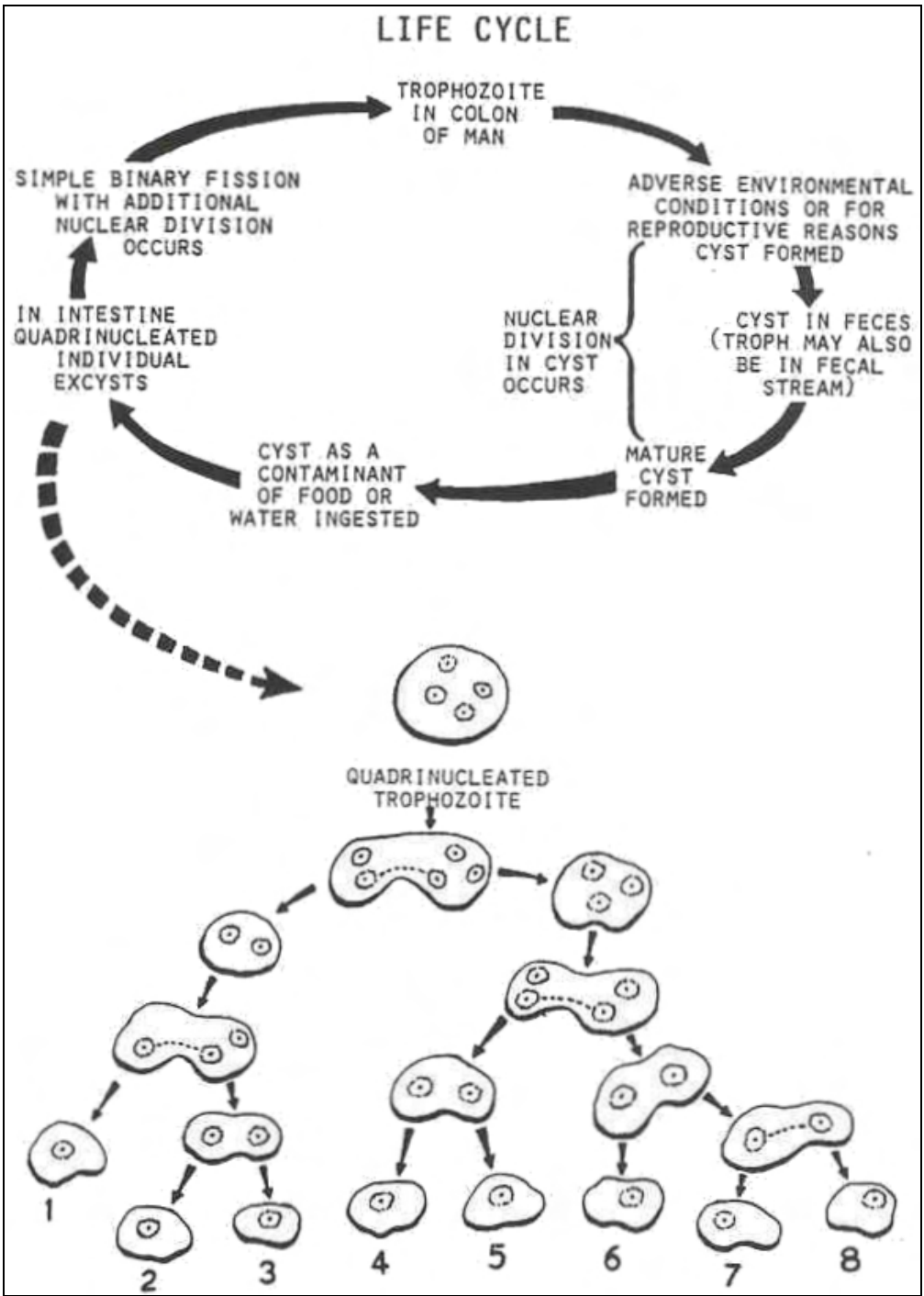


Figure 1-5. Life cycle of Entamoeba histolytica.

Entamoeba histolytica

TROPHOZOITE

SIZE: 11 to 60 μ .

SHAPE : Irregular.

NUCLEUS: Vesicular, dispersed.

NUMBER: One.

PERIPHERAL CHROMATIN: Finely granular and evenly distributed.

KARYOSOME: Small, discrete, and usually centrally located.

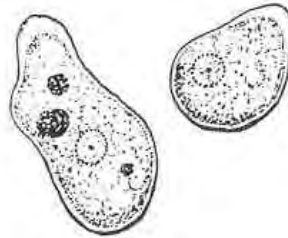
NUCLEOPLASM Clean.

CYTOPLASM: Clean.

APPEARANCE: Finely granular.

INCLUSIONS: Occasional RBCs.

MOBILITY: Directional and progressive with finger-like pseudopodia.



CYST

SIZE: 11 to 20 μ .

SHAPE : Spherical.

NUCLEUS:

NUMBER: One to four; the mature cyst has four.

PERIPHERAL CHROMATIN: Finely granular and evenly distributed.

KARYOSOME: Small, discrete, and usually centrally located.

NUCLEOPLASM Clean.

CYTOPLASM: Finely granular.

CHROMATOID BODIES: If present, cigar-shaped, rounded ends; diagnostic feature.

GLYCOGEN: Diffused, in vacuoles for young cysts.

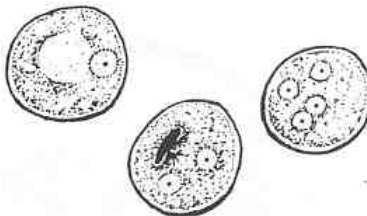


Figure 1-6. Stages of E. histolytica.

ORGANISM 2 -- Entamoeba hartmanii

GENERAL CHARACTERISTICS

COMMON NAME: None.

GEOGRAPHICAL DISTRIBUTION: Cosmopolitan.

PATHOGENESIS: Nonpathogenic.

LABORATORY IDENTIFICATION: Morphologically identical to E. histolytica except for the size and inclusions in the trophozoite.

SPECIMEN SOURCE: Feces.

Figure 1-7. Information on Entamoeba hartmanii.

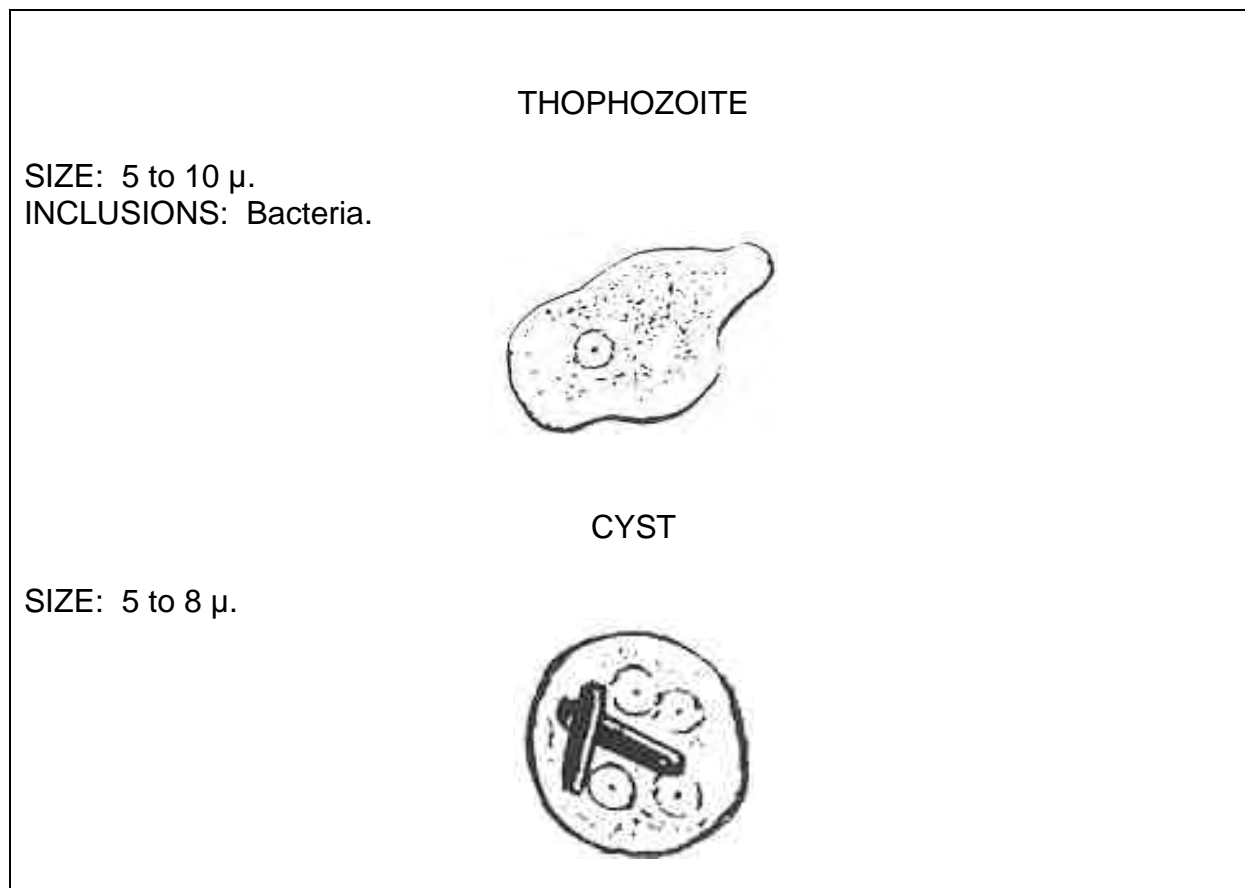


Figure 1-8. Stages of Entamoeba hartmanii

ORGANISM 3 -- Entamoeba coli

GENERAL CHARACTERISTICS

COMMON NAME: None.

GEOGRAPHICAL DISTRIBUTION: Cosmopolitan.

PATHOGENESIS: Nonpathogenic, often confused with E. histolytica.

HABITAT: Large intestine (colon).

INTERMEDIATE HOST: None.

RESERVOIR HOST: Primates.

INFECTED FORM: Mature cyst with eight nuclei.

MODE OF INFECTION: Ingestion.

LABORATORY IDENTIFICATION:

SPECIMEN SOURCE: Feces.

Figure 1-9. Information on Entamoeba coli.

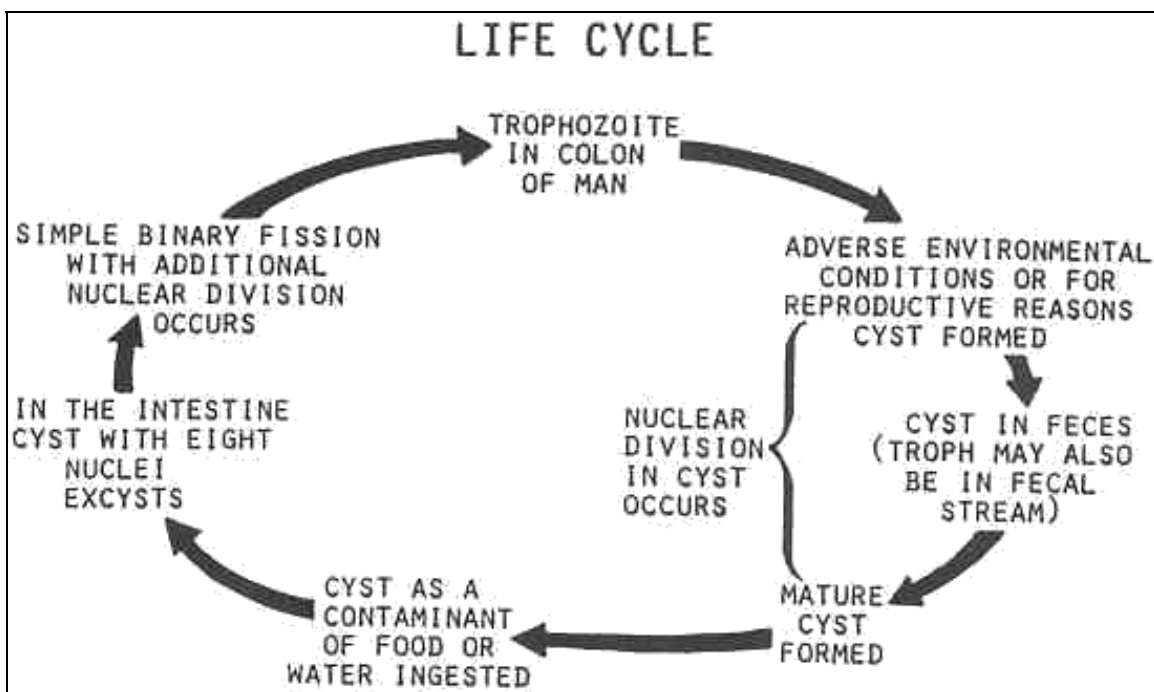


Figure 1-10. Life cycle of Entamoeba coli.

TROPHOZOITE

SIZE: 10 to 50 μ .

SHAPE : Irregular.

NUCLEUS: Vesicular, dispersed.

NUMBER: One.

PERIPHERAL CHROMATIN: Course granules; irregular size and distribution

KARYOSOME: Small but larger than *e. histolytica* and usually eccentric.

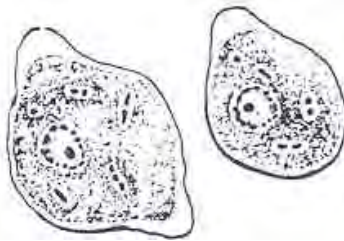
NUCUEOPLASM: Not as clean as *E. histolytica*.

CYTOPLASM:

APPEARANCE: Dirty, vaculoated, coarsely granular.

INCLUSIONS: Yeasts, molds, bacteria.

MOBILITY: Nondirectional with blunt pseudopodia.



CYST

SIZE: 10 to 35 μ .

SHAPE : Spherical.

NUCLEUS: Vesicular, dispersed.

NUMBER: 1-8; mature cyst has 8.

PERIPHERAL CHROMATIN: Course granules; irregular size and distribution

KARYOSOME: Small but larger than *e. histolytica* and usually eccentric.

NUCUEOPLASM: Not as clean as *E. histolytica*.

CYTOPLASM: Dirty.

CHROMATOID BODIES: Splintered-ends; uneven; pointed ends; resembles shock of wheat.

GLYCOGEN: Diffused.

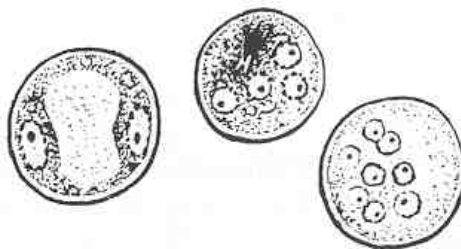


Figure 1-11. Stages of *E. coli*.

ORGANISM 4 -- Entamoeba polecki

GENERAL CHARACTERISTICS

COMMON NAME: None.

GEOGRAPHICAL DISTRIBUTION: Papua, New Guinea.

PATHOGENESIS: Occasional parasite of man.

HABITAT: Intestines.

INTERMEDIATE HOST: None.

RESERVOIR HOST: Pigs and monkeys.

INFECTED FORM: Mature, uninucleated cyst.

MODE OF INFECTION: Ingestion.

LABORATORY IDENTIFICATION:

SPECIMEN SOURCE: Feces.

Figure 1-12. Information on Entamoeba polecki.

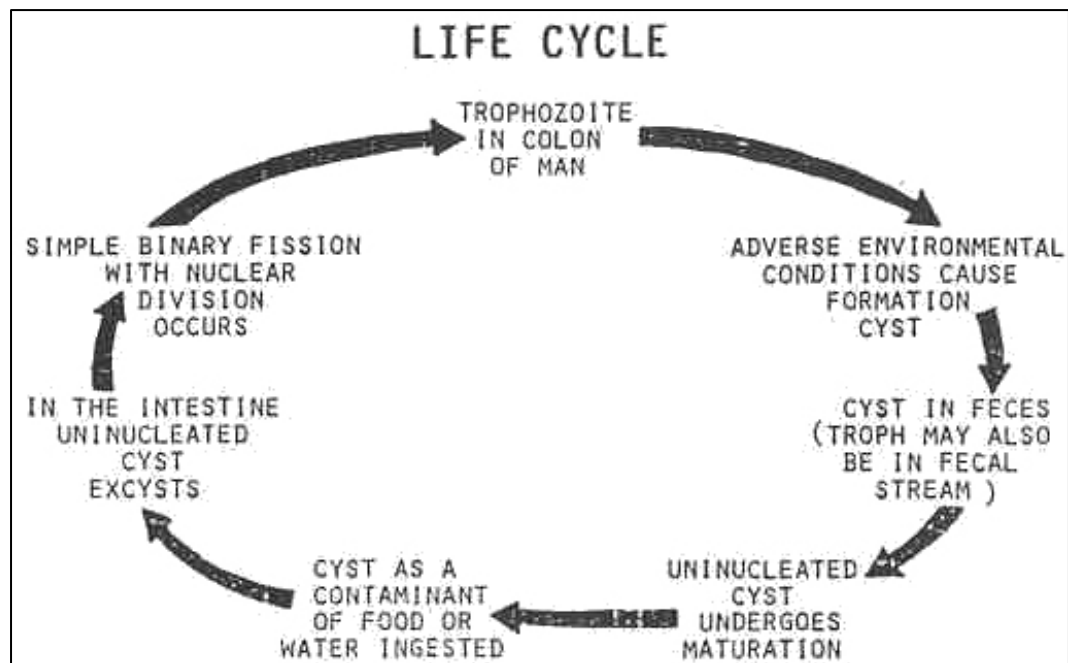


Figure 1-13. Life cycle of Entamoeba polecki.

Entamoeba polecki

TROPHOZOITE

SIZE: 10 to 25 μ .

SHAPE : Irregular.

NUCLEUS: Vesicular, dispersed.

NUMBER: One.

PERIPHERAL CHROMATIN: Fine and coarse granules; may be even or uneven; could be masses at one end.

KARYOSOME: Small; discrete; usually eccentric; may be fragmented.

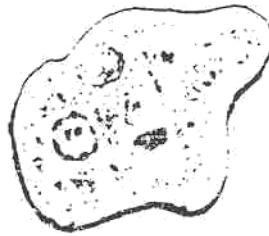NUCLEOPLASM: Usually dirty.

CYTOPLASM:

APPEARANCE: Very dirty and vacuolated.

INCLUSIONS: Bacteria.

MOBILITY: Nondirectional (occasionally directional).



CYST

SIZE: 9 to 18 μ .

SHAPE : Spherical to oval.

NUCLEUS: Vesicular, dispersed.

NUMBER: One.

PERIPHERAL CHROMATIN: Fine and coarse granules; may be even or uneven; could be masses at one end.

KARYOSOME: Small; discrete; usually eccentric; may be fragmented.

NUCLEOPLASM: Usually dirty.

CYTOPLASM:

CHROMATOID BODIES: Many; irregular shape with pointed ends..

GLYCOGEN: Diffused.

INCLUSION MASS: Unknown nature but typical of the organism.




Figure 1-14. Stages of E. polecki.

ORGANISM 5 -- Naeqleria fowleri

GENERAL CHARACTERISTICS

COMMON NAME: None.

GEOGRAPHICAL DISTRIBUTION: Australia, Europe, and America.

PATHOGENESIS: Primary amebic meningoencepha (PAM).

HABITAT: Usually free living; the meninges in man.

INTERMEDIATE HOST: None.

RESERVOIR HOST: None known.

INFECTED FORM: Biflagellated trophozoite.

MODE OF INFECTION: Active penetration through the nostrils.

LABORATORY IDENTIFICATION:

SPECIMEN SOURCE: Cerebral spinal fluid.

Figure 1-15. Information on Naeqleria fowleri.

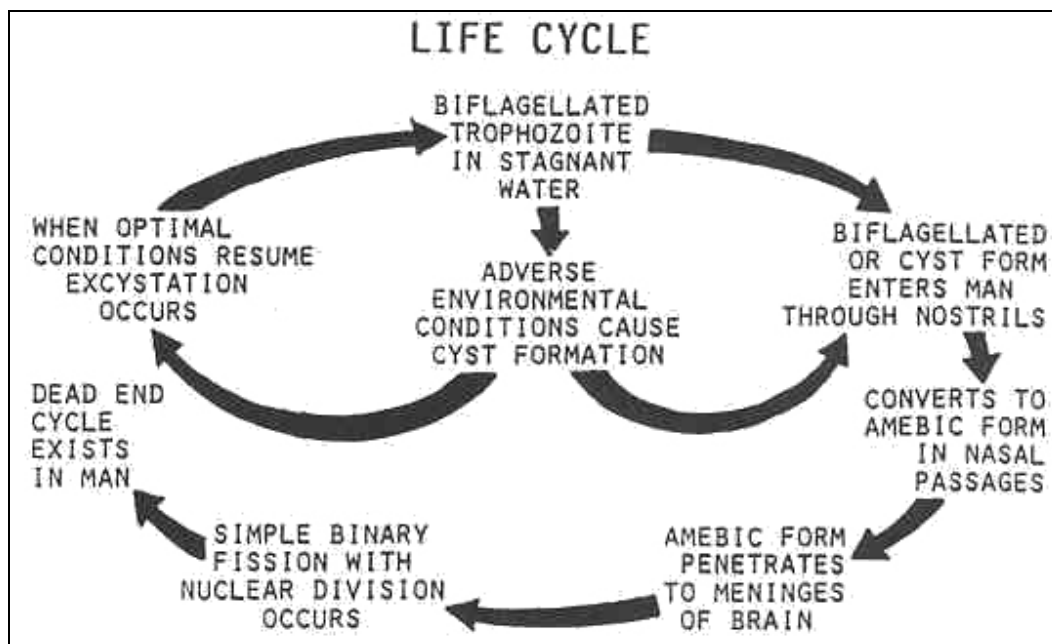


Figure 1-16. Life cycle of Naeqleria fowleri.

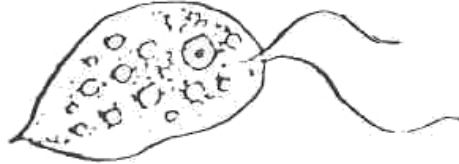
Naegleria fowleri

FREE-LIVING TROPHOZOITE

Indistinguishable from *N. gruberi*, a free living organism isolated from soil.

SHAPE: Pear shape.

FLAGELLA--ANTERIOR: 2 to 4.



AMOEBIC TROPHOZOITE

SIZE: 10 to 25 μ .

SHAPE : Elongated to oval,

NUCLEUS: Vesicular, dispersed.

NUMBER: One.

PERIPHERAL CHROMATIN: Finely granular and evenly distributed.

KARYOSOME: Some small but larger than *E. histolytica*.

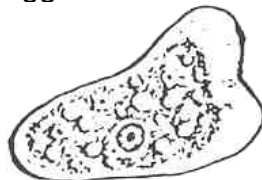
NUCLEOPLASM: Clean to dirty.

CYTOPLASM:

APPEARANCE: Finely granular.

INCLUSIONS: Cellular debris.

MOBILITY: Nondirectional and sluggish.



SIZE: 8 to 12 μ .

SHAPE : Oval to spherical.

NUCLEUS: Vesicular, dispersed.

NUMBER: One.

PERIPHERAL CHROMATIN: Finely granular and evenly distributed.

KARYOSOME: Some small but larger than *E. histolytica*.

NUCLEOPLASM: Clean to dirty.

CYTOPLASM:

CHROMATOID BODIES: None detected.

GLYCOGEN: Diffuse

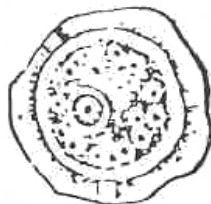


Figure 1-17. Stages of *N. fowleri*.

Hartmanella and Acanthamoeba species

GENERAL CHARACTERISTICS

Pathogenesis--(mild disease process). At one time, the disease caused by N. fowleri was thought to be caused by these two genera. At present, it is believed that there is no pathogenicity caused by Hartmanella species, but Acanthamoeba species are still believed to produce infection in man.

Laboratory identification--same as N. fowleri except for the absence of the flagellated stage.

Figure 1-18. Information on Hartmanella and Acanthamoeba species.

ORGANISM 6 -- Ensolimax nana

GENERAL CHARACTERISTICS

COMMON NAME: None.

GEOGRAPHICAL DISTRIBUTION: Cosmopolitan.

PATHOGENESIS: Nonpathogenic.

HABITAT: Intestines (colon).

INTERMEDIATE HOST: None.

RESERVOIR HOST: None.

INFECTED FORM: Mature, quadrinucleated cyst.

MODE OF INFECTION: Ingestion.

LABORATORY IDENTIFICATION:

SPECIMEN SOURCE: Feces.

Figure 1-19. Information on Ensolimax nana.

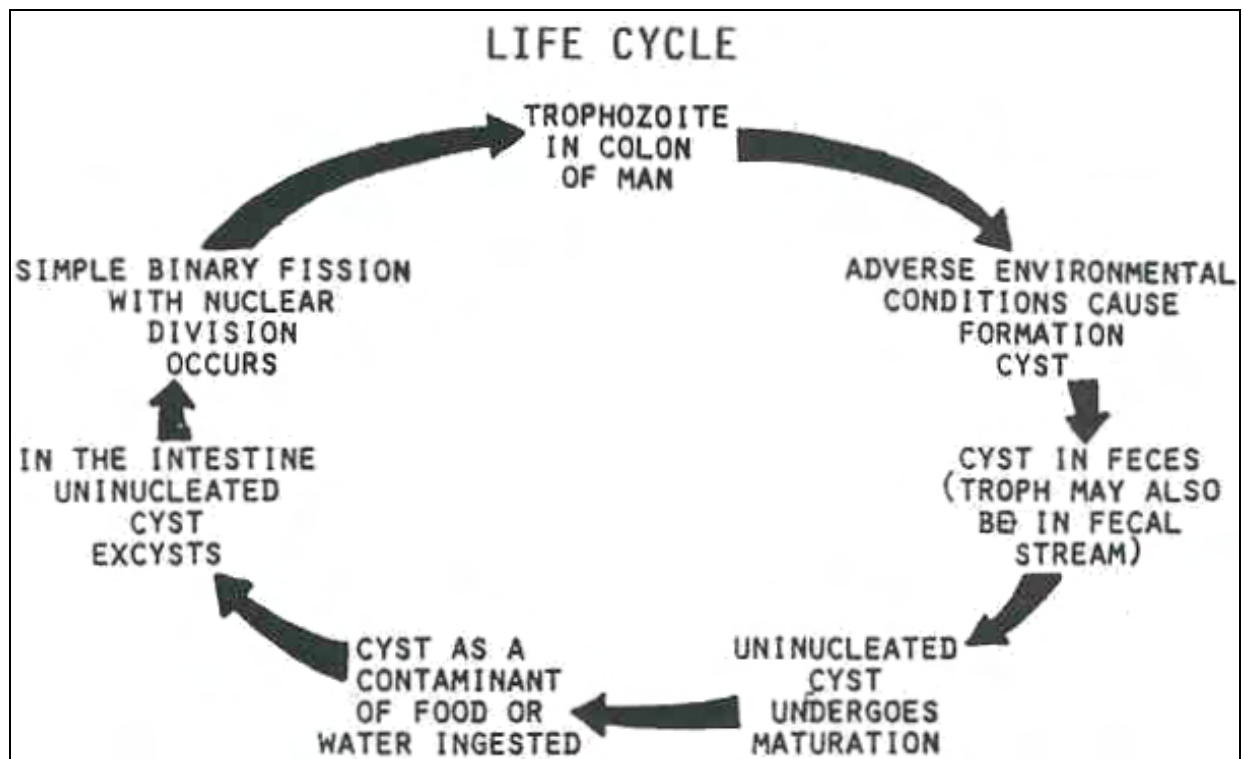


Figure 1-20. Life cycle of Endolimax nana.

Ensolimax nana

TROPHOZOITE

SIZE: 6 to 12 μ .

SHAPE : Irregular to oval,

NUCLEUS: Vesicular, condensed.

NUMBER: One.

PERIPHERAL CHROMATIN: Absent.

KARYOSOME: Large; irregular; usually centrally located than E. histolytica.

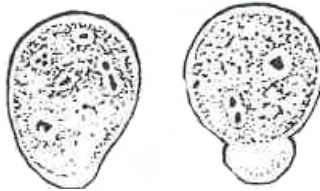
NUCLEOPLASM: Relatively clean but dirtier than E. histolytica.

CYTOPLASM:

APPEARANCE: Relatively clean but dirtier than E. histolytica.

INCLUSIONS: Bacteria.

MOBILITY: Nondirectional with blunt pseudopodia.



CYST

SIZE: 5 to 10 μ .

SHAPE : Oval to elliptical.

NUCLEUS: Smaller than the trophozoite.

NUMBER: One to four.

PERIPHERAL CHROMATIN: Absent.

KARYOSOME: Large; irregular; usually centrally located than E. histolytica.

NUCLEOPLASM: Relatively clean but dirtier than E. histolytica.

CYTOPLASM:

CHROMATOID BODIES: Rarely present as granules.

GLYCOGEN: Usually diffused.




Figure 1-21. Stages of E. nana.

ORGANISM 7 -- Iodamoeba butschlii

GENERAL CHARACTERISTICS

COMMON NAME: None.

GEOGRAPHICAL DISTRIBUTION: Cosmopolitan.

PATHOGENESIS: Nonpathogenic; considered to be a possible pathogen in severe physical stress (malnutrition).

HABITAT: Large intestines.

INTERMEDIATE HOST: None.

RESERVOIR HOST: Pigs.

INFECTED FORM: Mature, uninucleated cyst.

MODE OF INFECTION: Ingestion.

LABORATORY IDENTIFICATION:

SPECIMEN SOURCE: Feces.

Figure 1-22. Information on Iodamoeba butschlii.

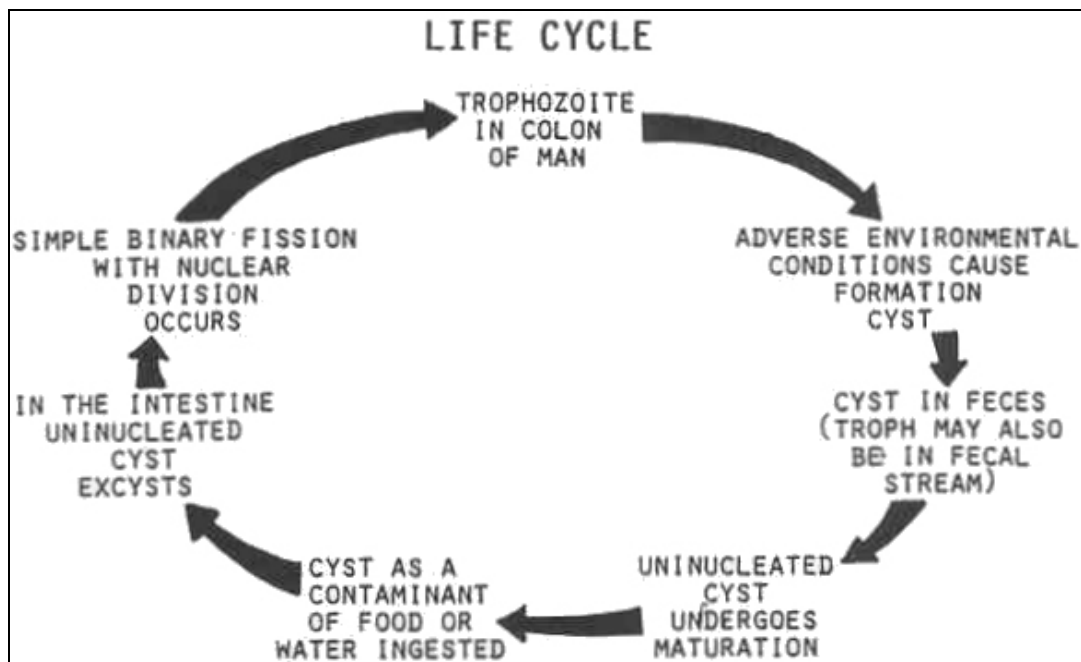


Figure 1-23. Life cycle of Iodamoeba butschlii.

Iodamoeba butschlii

TROPHOZOITE

SIZE: 8 to 20 μ .

SHAPE : Irregular to round; most oval.

NUCLEUS: Vesicular, condensed.

NUMBER: One.

PERIPHERAL CHROMATIN: Absent; achromatic granules surrounding the karyosome.

KARYOSOME: Large and eccentric due to achromatic granules.

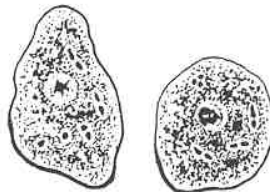
NUCLEOPLASM: Dirty.

CYTOPLASM:

APPEARANCE: Coarse; very dirty.

INCLUSIONS: Bacteria, molds and yeasts

MOBILITY: Nondirectional with blunt pseudopodia.



CYST

SIZE: 5 to 20 μ .

SHAPE : Irregular; most are oval.

NUMBER: One.

PERIPHERAL CHROMATIN: Absent; achromatic granules surrounding the karyosome.

KARYOSOME: Large and eccentric due to achromatic granules.

NUCLEOPLASM: Dirty.

CYTOPLASM:

CHROMATOID BODIES: None seen.

GLYCOGEN: Discrete; compact; well defined; large mass (vacuole).

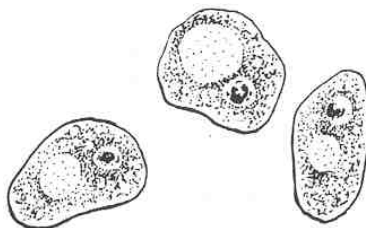


Figure 1-24. Stages of I. butschlii.

Section III. CLASS ZOOMASTIGOPHORA

1-9. GENERAL DESCRIPTION

These organisms move by means of rotation of a whip-like organelle called a flagellum (plural: flagella) (see figure 1-25). The flagella can also be used for gathering and sorting food. Respiration, food absorption, and excretion can be performed by osmosis and active transport across the cell membrane. Some species have organelles for the purpose of food ingestion (gullet or cytostome), and for excretion (cytopyge). Encystation may be used by these organisms in response to adverse environment and/or for reproduction. The parasitic members of this class are divided into two groups: the lumen flagellates, which inhabit the body orifices, the intestines and the bladder; and the blood and tissue flagellates. There are many members of this class which are pathogenic to man. These include lumen flagellates such as Giardia lamblia and members of the Trichomonas species and blood and tissue flagellates from the Trypanosoma and Leishmania species. See figures 1-26 through 1-44 for information on specific organisms.

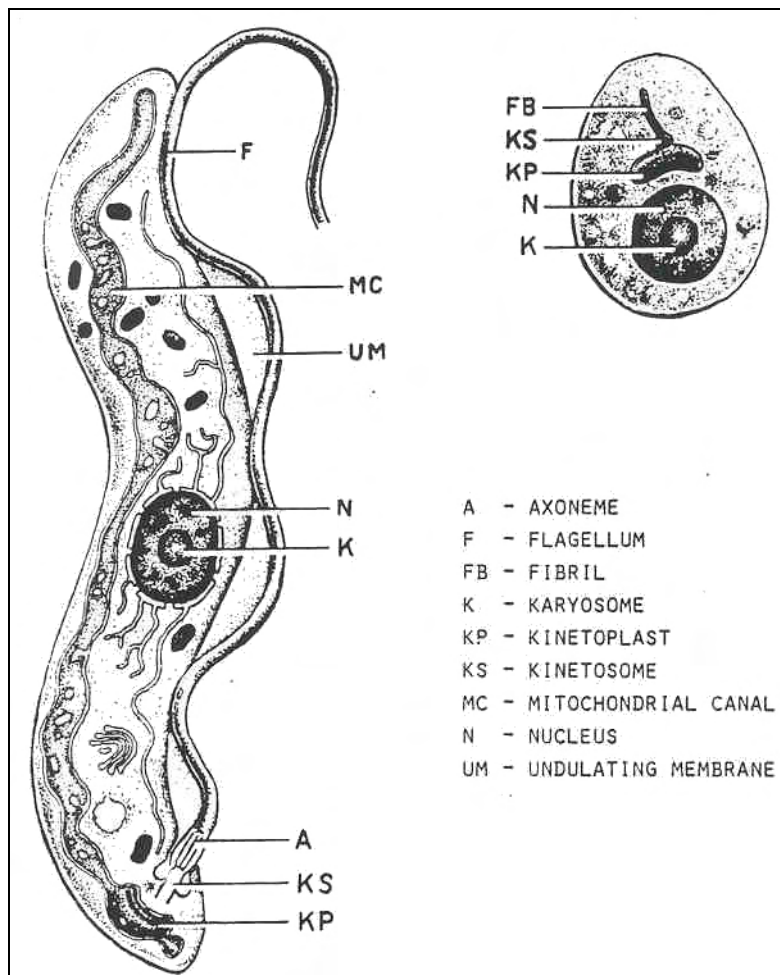


Figure 1-25. Typical flagellate.

1-10. LUMEN FLAGELLATES

The lumen flagellates pathogenic to men are Giardia lamblia, Trichomonas vaginalis, and Trichomonas hominis.

ORGANISM 1 -- Giardia lamblia

GENERAL CHARACTERISTICS

COMMON NAME: None.

GEOGRAPHICAL DISTRIBUTION: Cosmopolitan; pocket of endemic behavior in Colorado.

PATHOGENESIS: Giardiasis.

SEROLOGICAL DIAGNOSIS: Agglutination test, fluorescent antibody, enzyme linked-immunosorbant assay (ELISA).

HABITAT: Small intestines.

INTERMEDIATE HOST: None.

RESERVOIR HOST: None.

INFECTED FORM: Mature, quadrinucleated cyst.

MODE OF INFECTION: Ingestion.

LABORATORY IDENTIFICATION:

SPECIMEN SOURCE: Feces, duodenal aspirates.

Figure 1-26. Information on Giardia lamblia.

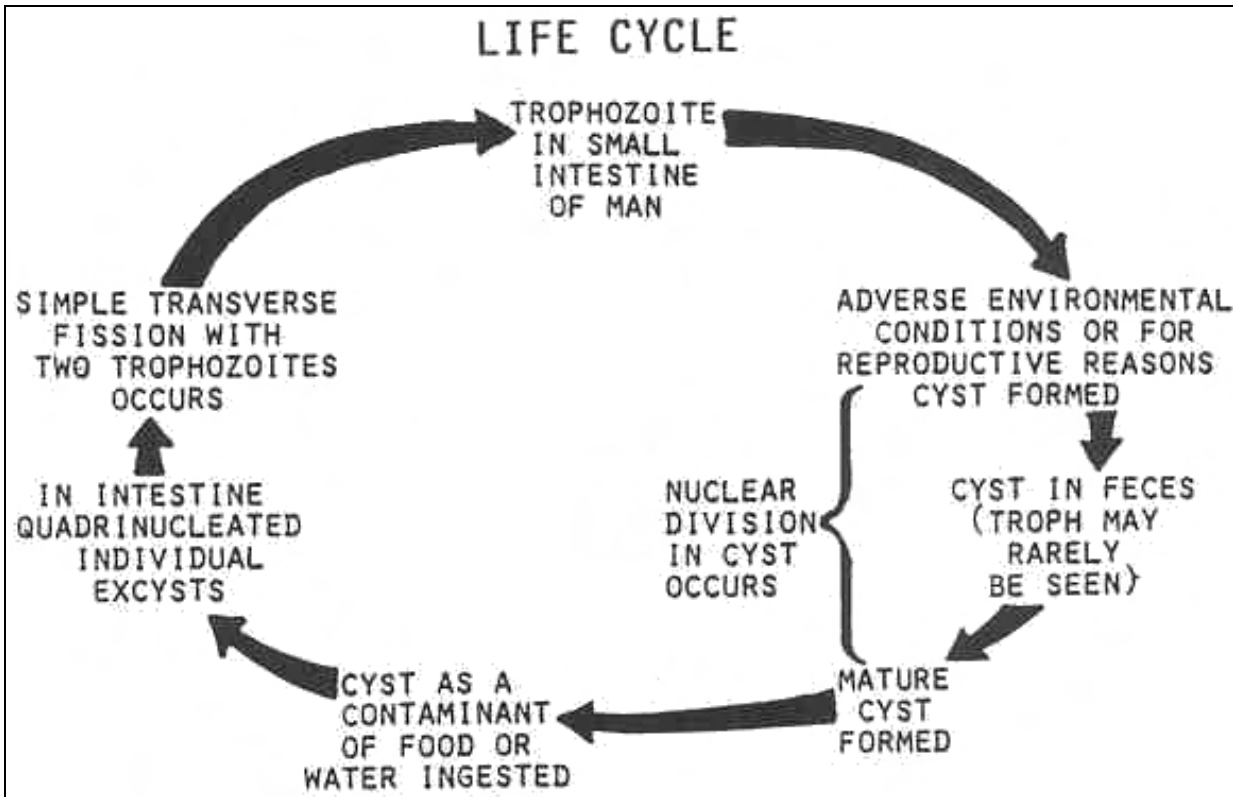


Figure 1-27. Life cycle of Giardia lamblia.

Giardia lamblia

TROPHOZOITE

SIZE: 9 to 20 μ .

SHAPE : Pear-shape; sucking disc; "Wry little face."

DORSAL SURFACE: Convex.

VENTRAL SURFACE: Concave.

NUCLEUS: Two.

CYTOPLASM:

FLAGELLA: 8.

ANTERIOR: 4.

VENTRAL: 2.

CAUDAL: 2.

KINETOSOMES: Give rise to the flagella; located between the anterior portion of the nuclei.

AXONEMES: Interior portion of the flagella; transverse the cytoplasm before emerging; the two caudal axonemes divide the body longitudinally into halves.

MEDIUM BODIES: Large curved, dark-stained.

FUNCTION: Unknown; support or energy production.

PREVIOUS IDEOLOGY: Parabasal bodies, kinetoplasts, or chromatoid bodies.

AXOSTYLES: There are none; what was believed to be axostyles are structures formed by the axonemes of the ventral flagella and the associated groups of microtubules.

MOBILITY: Like a falling leaf.

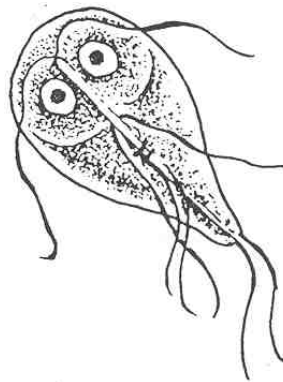


Figure 1-28. Stages of G. lamblia (cotinued).

Giardia lamblia

CYST

SIZE: 8 to 14 μ .

SHAPE: Ovoid to ellipsoidal.

NUCLEUS: 2 to 4.

CYTOPLASM: Remnants of flagella, kinetosomes, axonemes, and median bodies; cytoplasm is detached from the cyst wall.

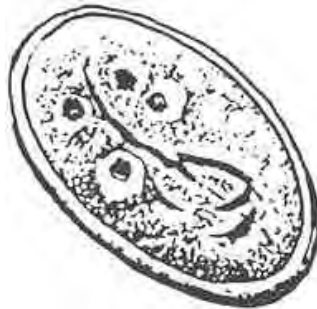


Figure 1-29. Stages of G. lamblia (concluded).

ORGANISM 2 -- Chilomastix mesnili

GENERAL CHARACTERISTICS

COMMON NAME: None.

GEOGRAPHICAL DISTRIBUTION: Cosmopolitan.

PATHOGENESIS: Nonpathogenic.

HABITAT: Colon.

INTERMEDIATE HOST: None.

RESERVOIR HOST: None.

INFECTED FORM: Mature.

MODE OF INFECTION: Ingestion.

LABORATORY IDENTIFICATION:

SPECIMEN SOURCE: Feces.

Figure 1-30. Information on Chilomastix mesnili.

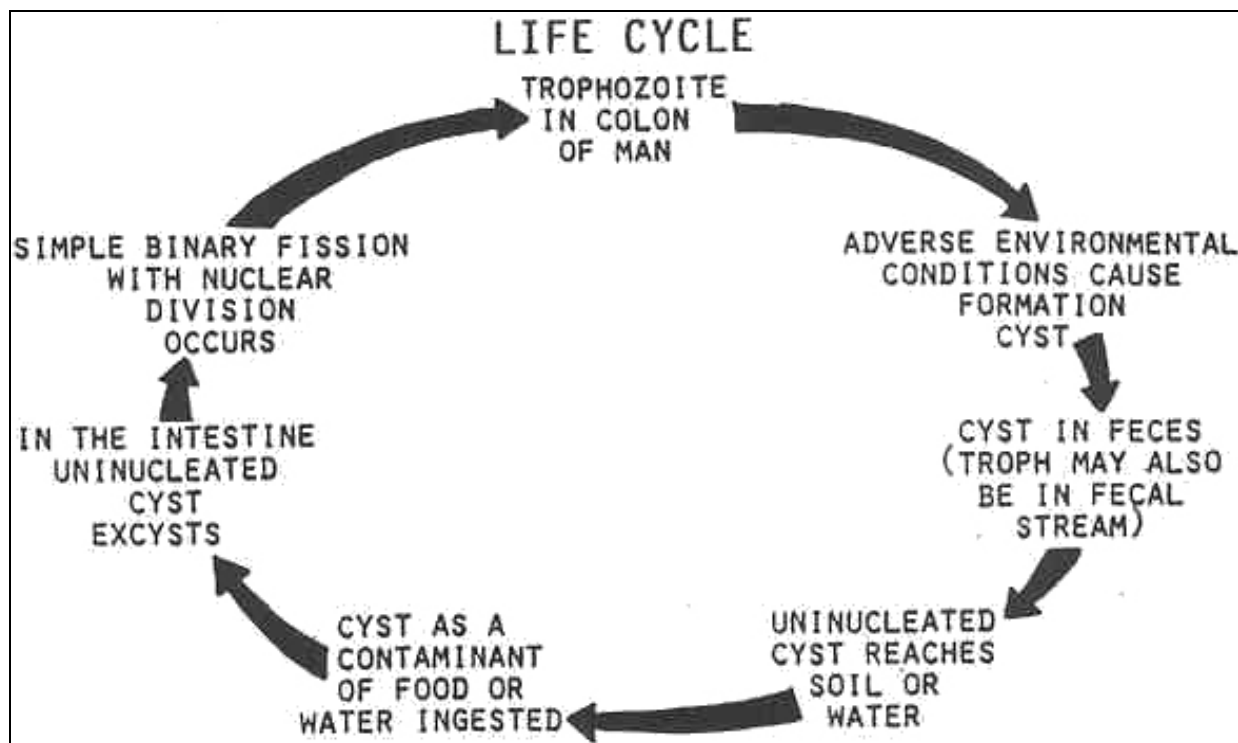


Figure 1-31. Life cycle of Chilomastic mesnili.

Chilomastix mesnili

TROPHOZOITE

SIZE: 6 to 24 μ .

SHAPE : Pyriform; asymmetrical; with a longitudinal spiral torsion.

NUCLEUS: One; relatively big; large nucleus to cytoplasm ratio; usually found at the anterior portion of the organism, by the cytoplasmic membrane.

CYTOPLASM:

FLAGELLA:

EXTERNAL: three; anterior.

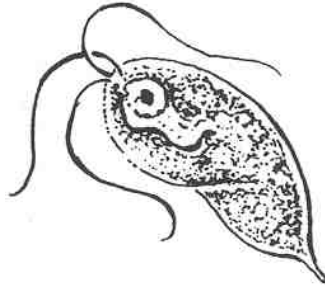
INTERNAL: One; cytostomal.

KINETOSOMES: Anterior; connected by microfibrils.

CYTOSTOMAL GROOVE: Prominent; near the anterior end; hour-glass shape.

CYTOSTOMAL FIBRIL: Support; along each side of the cytostomal groove.

MOBILITY: Stiff and rotary.



CYST

SIZE: 6 to 10 μ .

SHAPE : Lemon-shape, ovoid.

NUCLEUS: One.

CYTOPLASM: Remnants of flagella, kinetosomes, and cytostomal groove (hour-glass shape); hyaline anterior nipple.

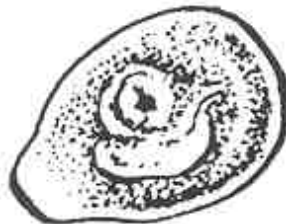


Figure 1-32. Stages of C. mesnili.

ORGANISM 3 -- Trichomonas species

GENERAL CHARACTERISTICS

COMMON NAME: None.

PATHOGENESIS:

Trichomonas vaginalis:

Females: Vaginitis, pruritis; strawberry cervix.

Males: Urethritis; prostatovesiculitis.

Trichomonas hominis: Questionable pathogenicity; intestinal disorders; endemic problem in homosexual communities.

Trichomonas tenax: opportunistic pathogen.

HABITAT:

Trichomonas vaginalis: Genitourinary tract.

Trichomonas hominis: Colon.

Trichomonas tenax: Mouth.

INTERMEDIATE HOST: None.

RESERVOIR HOST: None.

INFECTED FORM: Trophozoite.

MODE OF INFECTION:

Trichomonas vaginalis: Sexual contact.

Trichomonas hominis: Ingestion.

Trichomonas tenax: Direct contact.

LABORATORY IDENTIFICATION:

SPECIMEN SOURCE:

Trichomonas vaginalis: Vaginal and urethral discharges; prostate exudates.

Trichomonas hominis: Feces.

Trichomonas tenax: Gingival scrapings.

Figure 1-33. Information on Trichomonas species.

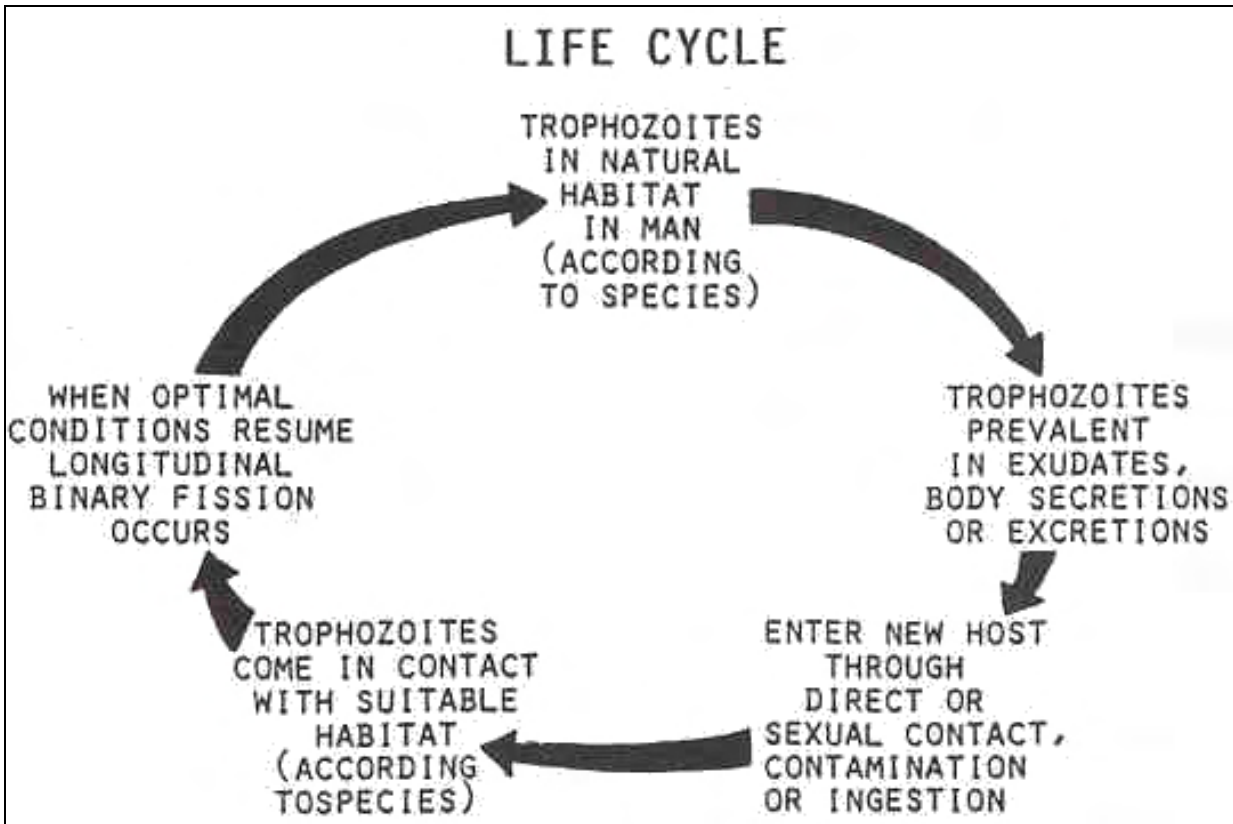


Figure 1-34. Life cycle of Trichomonas species.

TROPHOZOITE

SIZE:

Trichomonas vaginalis: 8 to 30 μ .

Trichomonas hominis: 8 to 20 μ .

Trichomonas tenax: 6 to 17 μ .

SHAPE : Pyriform to oval

NUCLEUS: One (eye spot).

FLAGELLA:

Trichomonas vaginalis: 4 anterior.

Trichomonas hominis: 5 anterior and 1 posterior.

Trichomonas tenax: 4 anterior.

UNDULATING MEMBRANE:

Trichomonas vaginalis: 1/3 to 1/2 the length of the organism.

Trichomonas hominis: Full length of the body.

Trichomonas tenax: 1/2 to 2/3 the length of the body.

COSTA: Arises at the kinetostome and travels beneath and parallel to the undulating membrane.

ACCESSORY FILAMENT: Lamellar structure located just inside the undulating membrane and courses along its length.

PARABASAL BODY: Golgi apparatus; near the nucleus

AXOSTYLES: Formed by a sheet of microtubules

CYTOSTOME: Absent.

MOBILITY: Vibrates; nervous; jerky.

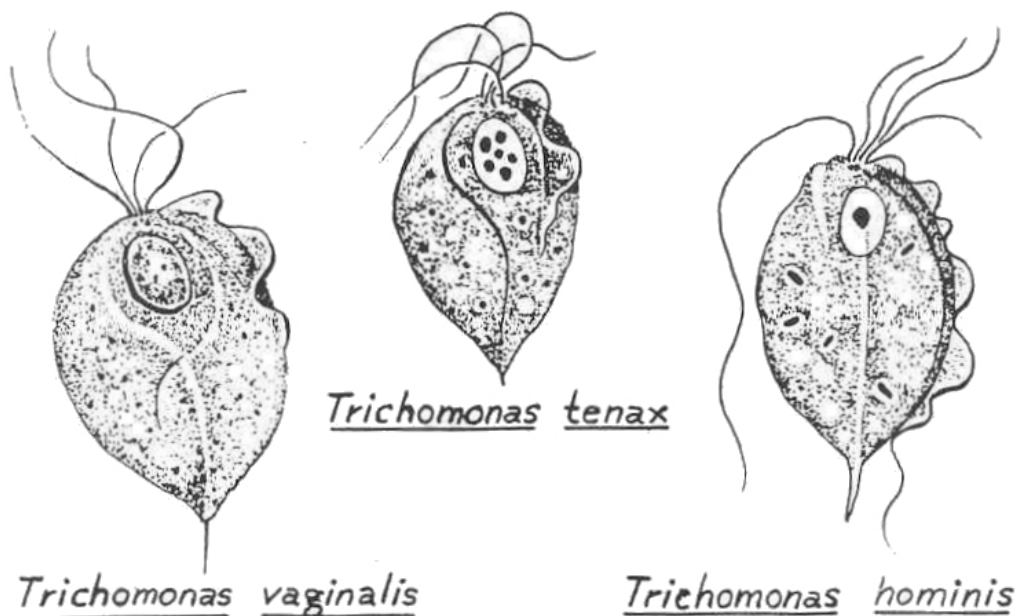


Figure 1-35. Trichomonas pathogens.

ORGANISM 4 -- Dientamoeba fragilis

GENERAL CHARACTERISTICS

COMMON NAME: None.

GEOGRAPHICAL DISTRIBUTION: Cosmopolitan.

PATHOGENESIS: Questionable pathogen, mild diarrhea.

HABITAT: Colon and cecum.

INTERMEDIATE HOST: None.

RESERVOIR HOST: None.

INFECTED FORM: Trophozoite.

MODE OF INFECTION: Unknown; with the ova of pinworms.

LABORATORY IDENTIFICATION:

SPECIMEN SOURCE: Feces.

Figure 1-36. Information on Dientamoeba fragilis.

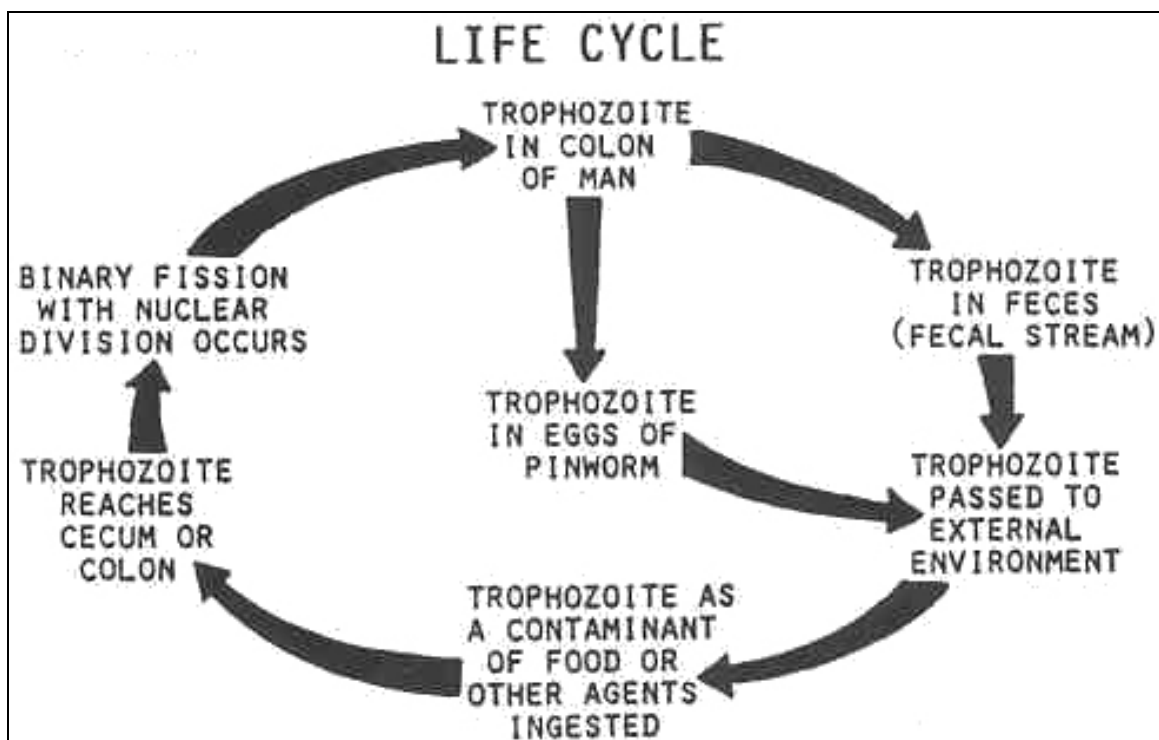


Figure 1-37. Life cycle of Dientamoeba fragilis.

Dientamoeba fragilis

TROPHOZOITE

SIZE: 8 to 9 μ .

SHAPE : Round to oval.

NUCLEUS: Vesicular; condensed.

NUMBER: Two

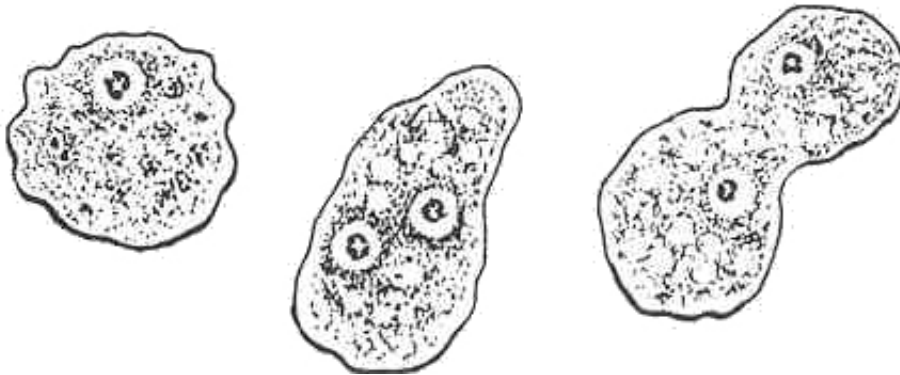KARYOSOME: Broken; "lumps of coal".

PERIPHERAL CHROMATIN: Absent.

CYTOPLASM:

APPEARANCE: Granular; vacuolated.

ORGANELLES: Vacuoles; bacteria, yeast; pseudopodia; broad, often serrated, hyaline.



CYST

No cystic stage known.

Figure 1-38. Stages of Dientamoeba fragilis.

ORGANISM 5 -- Retortamonas intestinalis (Embadamonas)

GENERAL CHARACTERISTICS

COMMON NAME: None.

GEOGRAPHICAL DISTRIBUTION: Cosmopolitan.

PATHOGENESIS: Nonpathogenic.

HABITAT: Colon.

INTERMEDIATE HOST: None.

RESERVOIR HOST: Rats, guinea, pigs, simians.

INFECTED FORM: Cyst.

MODE OF INFECTION: Ingestion.

LABORATORY IDENTIFICATION:

SPECIMEN SOURCE: Feces.

Figure 1-39. Information on Retortamonas intestinalis.

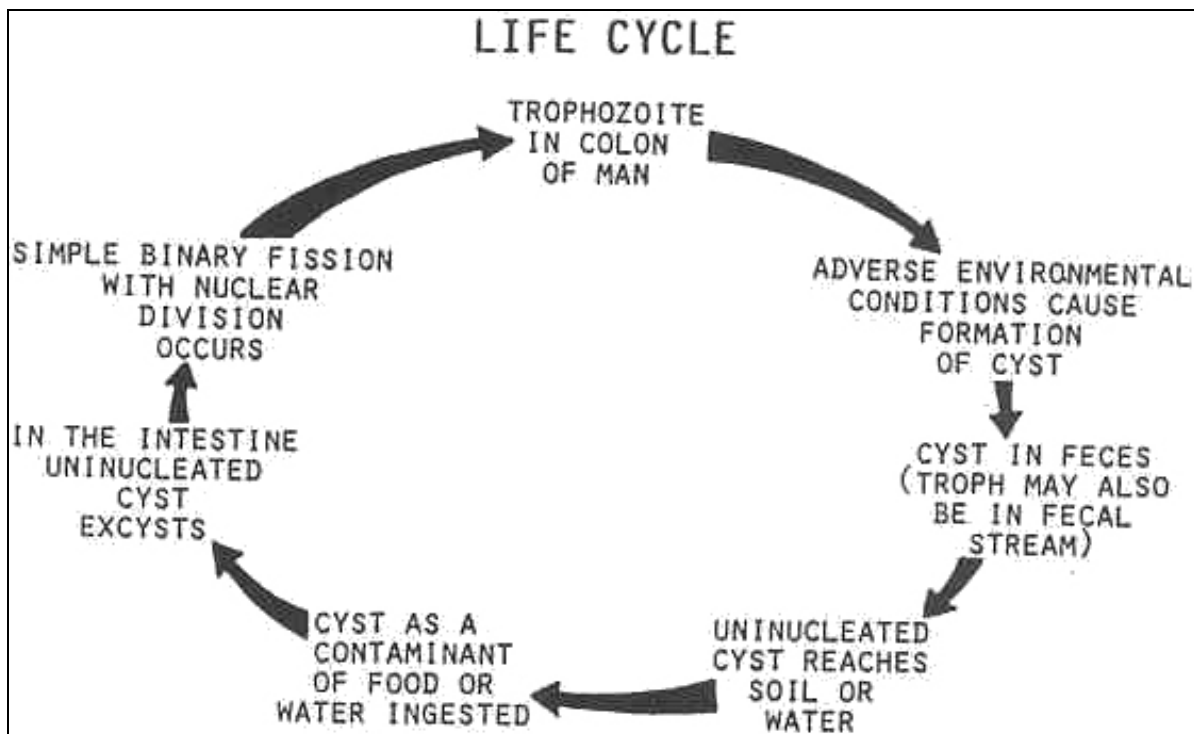


Figure 1-40. Life cycle of Retortamonas intestinalis.

Retortamonas intestinalis (Embadamonas)

TROPHOZOITE

Similar to C. mesnili.

SIZE: 4 to 9 μ .

SHAPE : Pyriform.

NUCLEUS: Single.

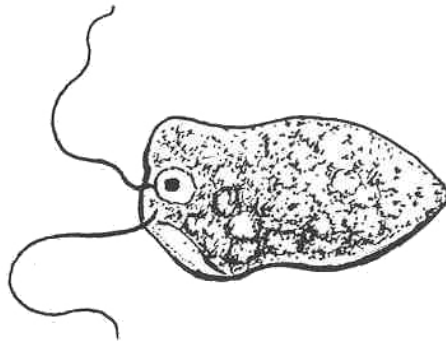
CYTOPLASM:

 APPEARANCE: Granular.

 ORGANELLES: Cytostomal groove.

 FLAGELLA: One anterior and one cystostomal.

MOBILITY: Rapid and jerky.



CYST

Similar to C. mesnili.

SIZE: 4 to 6 μ .

SHAPE : Ovoid.

NUCLEUS: One; indistinct

CYTOPLASM: Two fibrils; suggest "bird's beak."

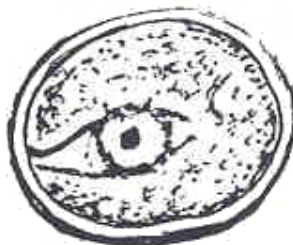


Figure 1-41. Stages of Retortamonas intestinalis.

ORGANISM 6 -- Enteromonas hominis (Octomitus)

GENERAL CHARACTERISTICS

COMMON NAME: None.

GEOGRAPHICAL DISTRIBUTION: Cosmopolitan.

PATHOGENESIS: Nonpathogenic.

HABITAT: Intestines.

INTERMEDIATE HOST: None.

RESERVOIR HOST: Rabbits, guinea pigs, pigs.

INFECTED FORM: Cyst.

MODE OF INFECTION: Ingestion.

LABORATORY IDENTIFICATION:

SPECIMEN SOURCE: Feces.

Figure 1-42. Information on Enteromonas hominis.

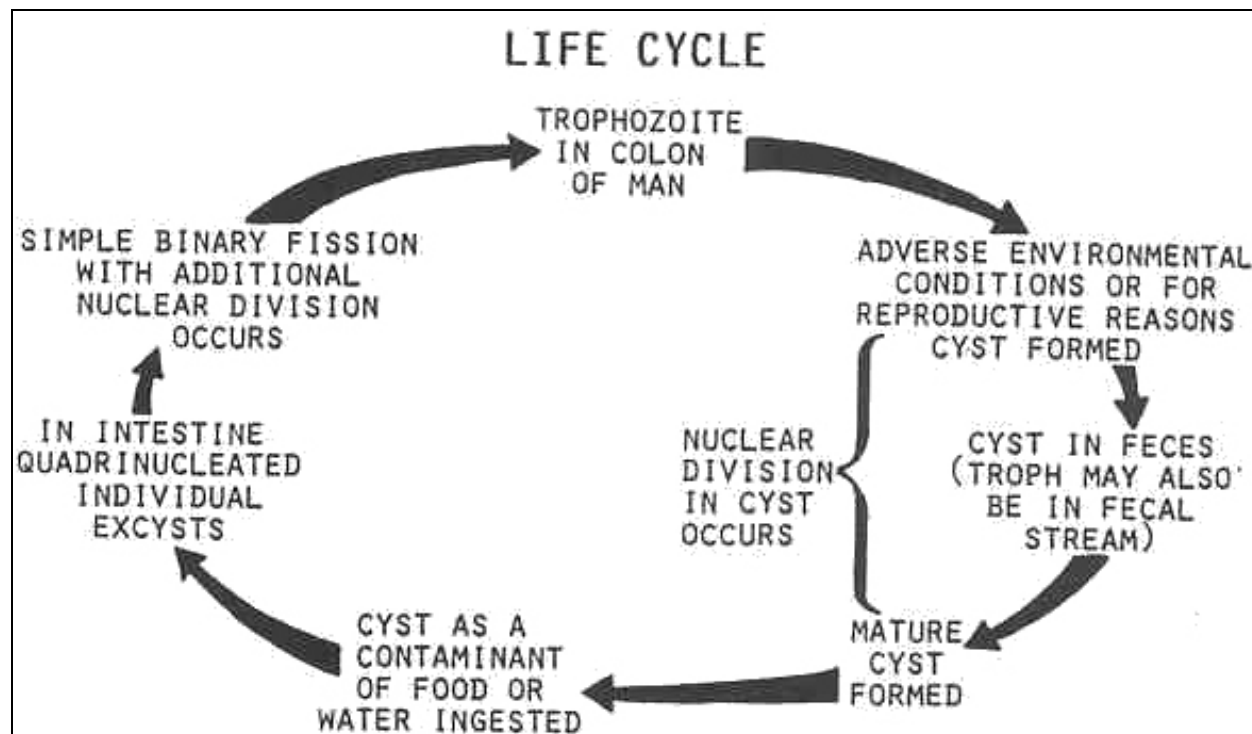


Figure 1-43. Life cycle of Enteromonas hominis.

Enteromonas hominis (Octomitus)

TROPHOZOITE

SIZE: 4 to 10 μ .

SHAPE : Pyriform.

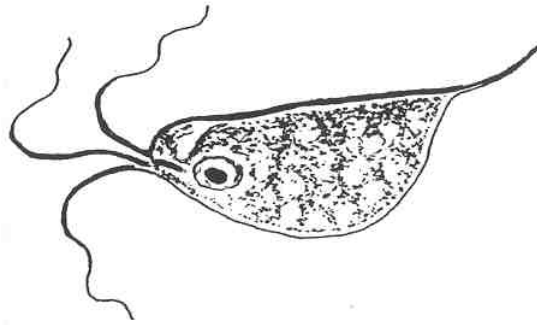
NUCLEUS: Single, distinct nuclear membrane; large, central karyosome.

CYTOPLASM:

 APPEARANCE: Granular.

 ORGANELLES: Flagella (one anterior and one posterior), no cytostomal groove.

MOBILITY: Rapid and jerky.



CYST

Similar to Endolimax nana.

SIZE: 6 to 8 μ .

SHAPE : Oval.

NUCLEUS:

 NUMBER: 1 to 4, (predominant: binucleate form).

CYTOPLASM: Finely granular.

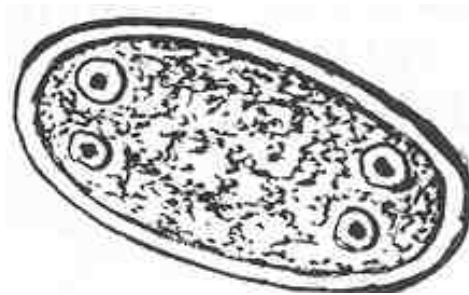


Figure 1-44. Stages of Enteromonas hominis.

1-11. BLOOD AND TISSUE FLAGELLATES

The pathogenic hemoflagellates belong to the family Trypanosomatidae. They are Trypanosoma species and Leishmania species. See figures 1-45 through 1-54).

Family Trypanosomatidae--THE HEMOFLAGELLATES

GENERAL CHARACTERISTICS

TWO GENERA--Leishmania, Trypanosoma.

ORGANELLES OF LOCOMOTION

KINETOPLAST: Position varies with organism and morphological forms;
location correlates with structural forms.

FLAGELLUM: Free, absent in some structural forms.

UNDULATING MEMBRANE--Found in some structural forms.

KINETOSOME--Indistinct

Figure 1-45. Information on hemoflagellates.

STRUCTURAL STAGES

AMASTIGOTE

"L-0 body," Leishman-Donovan bodies, found intracellular in reticuloendothelial cells, identification form for Leishmania.

SIZE--2 to 5 μ .

SHAPE--Oval.

NUCLEUS: Large, spherical.

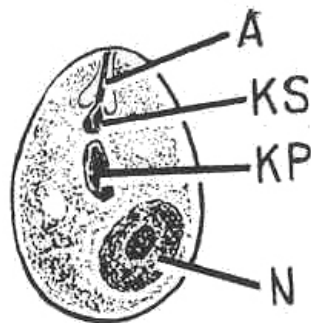
KINETOPLAST: Large, rod shaped.

FLAGELLUM: Absent

PRESENCE IN THE HUMAN HOST: Yes.

AXONEME: Rarely seen as short, internal stem,

GIEMSA STAIN: Red nucleus, light blue cytoplasm.



LEGEND

A	AXONEME
F	FLAGELLUM
KP	KINETOPLAST
KS	KINETOSOME
N	NUCLEUS
UM	UNDULATING MEMBRANE
VG	VOLUTIN GRANULES

Figure 1-46. Structural stages of hemoflagellates. (continued)

PROMASTIGOTE

Found in the mid gut of the insect host. Infective form of Leishmania.

SIZE--3 to 15 μ .

SHAPE--Elongate.

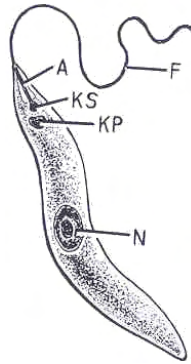
NUCLEUS: Central.

KINETOPLAST: Anterior to nucleus.

UNDULATING MEMBRANE: Absent.

FLAGELLUM: Short at anterior end.

PRESENCE IN THE HUMAN HOST: Yes.



EPIMASTIGOTE

Found in the mid gut of the insect host.

SIZE--15 to 20 μ in length.

SHAPE--Elongate.

NUCLEUS: Generally centrally located.

KINETOPLAST: Immediately anterior to nucleus.

UNDULATING MEMBRANE: Present.

FLAGELLUM: Free, anterior.

PRESENCE IN THE HUMAN HOST: Yes.

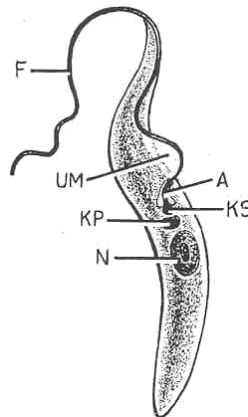


Figure 1-46. Structural stages of hemoflagellates. (continued)

METACYCLIC TRYPOMASTIOGOTE

Found in the hindgut of the insect host. Infective form of Leishmania.

SIZE--16 to 40 μ .

SHAPE--Elongate.

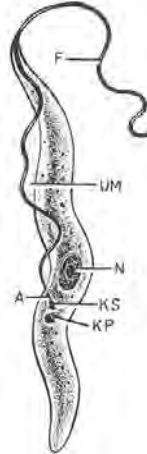
NUCLEUS: Centrally located.

KINETOPLAST: Posterior to nucleus.

UNDULATING MEMBRANE: Present.

FLAGELLUM: Free, anterior.

PRESENCE IN THE HUMAN HOST: Yes.



TRYPOMASTIGOTE

Found in the circulatory system. Definitive stage of Trypanosoma in man..

SIZE--16 to 36 μ .

SHAPE--"S" shaped common with T. brucei, "C" or "U" shape common with T. cruzi.

NUCLEUS: Generally central in located.

KINETOPLAST: At posterior end.

UNDULATING MEMBRANE: Present.

FLAGELLUM: Free.

PRESENCE IN THE HUMAN HOST: Yes.

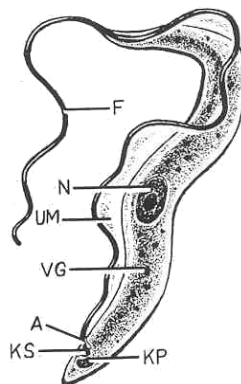


Figure 1-46. Structural stages of hemoflagellates. (concluded)

ORGANISM 1 -- Leishmania species

GENERAL CHARACTERISTICS

COMMON NAME

Leishmania donovani--Kala-azar: visceral leishmaniasis

Leishmania donovani infantum: infantile visceral leishmaniasis Leishmania donovani archibaldi--visceral leishmaniasis

Leishmania donovani chagasi: American visceral leishmaniasis

Leishmania tropica major: cutaneous leishmaniasis, Oriental sore

Leishmania tropica tropica: oriental sore, cutaneous leishmaniasis, urban Leishmania aethiopica--cutaneous leishmaniasis

Leishmania mexicana mexicana: chiclero ulcer, cutaneous leishmaniasis Leishmania peruviana--uta, cutaneous leishmaniasis

Leishmania braziliensis braziliensis: espundia, American leishmaniasis, mucocutaneous leishmaniasis

PATHOGENESIS

Viscera I leishmaniasis: destroys reticulo-endothelial cells (R-E cells); decreases production of RBC'S; hepatosplenomegaly; frequently fatal; immunity: gamma globulins, only after recovery from the first infection.

Cutaneous leishmaniasis: shallow, dry scaly sore; "wet-sore": "punched out" appearance; facial disfiguring; seldom fatal; immunity; vaccination is available; parents intentionally infect their children in an unexposed area thereby allowing acquired immunity and preventing facial disfigurement.

Mucocutaneous leishmaniasis: sores with moist centers, masses of necrotic tissue; marked deformities; frequently fatal.

GEOGRAPHICAL DISTRIBUTION

L. donovani donovani: India, Burma

L. donovani infantum: Mediterranean shoreline

L. donovani archibaldi: Africa: Kenya, Gold & Ivory Coasts

L. donovani chagasi: Latin America

L. tropica major: Africa, Asia, Europe

L. tropica tropica: Africa, Asia, Europe L. aethiopica--Ethiopia, Kenya

L. mexicana mexicana: Mexico to Panama

L. peruviana: Peruvian Andes (3000 m.)

L. braziliensis braziliensis: Central & Northern South America

(continued)

Figure 1-47. Information on Leishmania species (continued).

(Organism 1--Leishmania species continued)

HABITAT: Phagocytic R-E cells and macrophages.

INTERMEDIATE HOST: Sandfly, Phlebotomus species.

RESERVOIR HOST: Cats, dogs, horses, sheep, and others.

INFECTED FORM: Promastigote.

MODE OF INFECTION: Bite of the vector (injection).

LABORATORY IDENTIFICATION:

SPECIMEN SOURCE: Tissue biopsy, bone marrow, skin.

AMASTIGOTE

Intracellular (Donovan bodies in Giemsa or Wright stain).

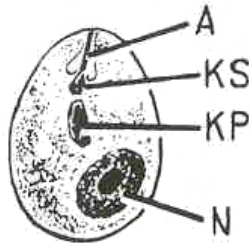


Figure 1-47. Information on Leishmania species (concluded).

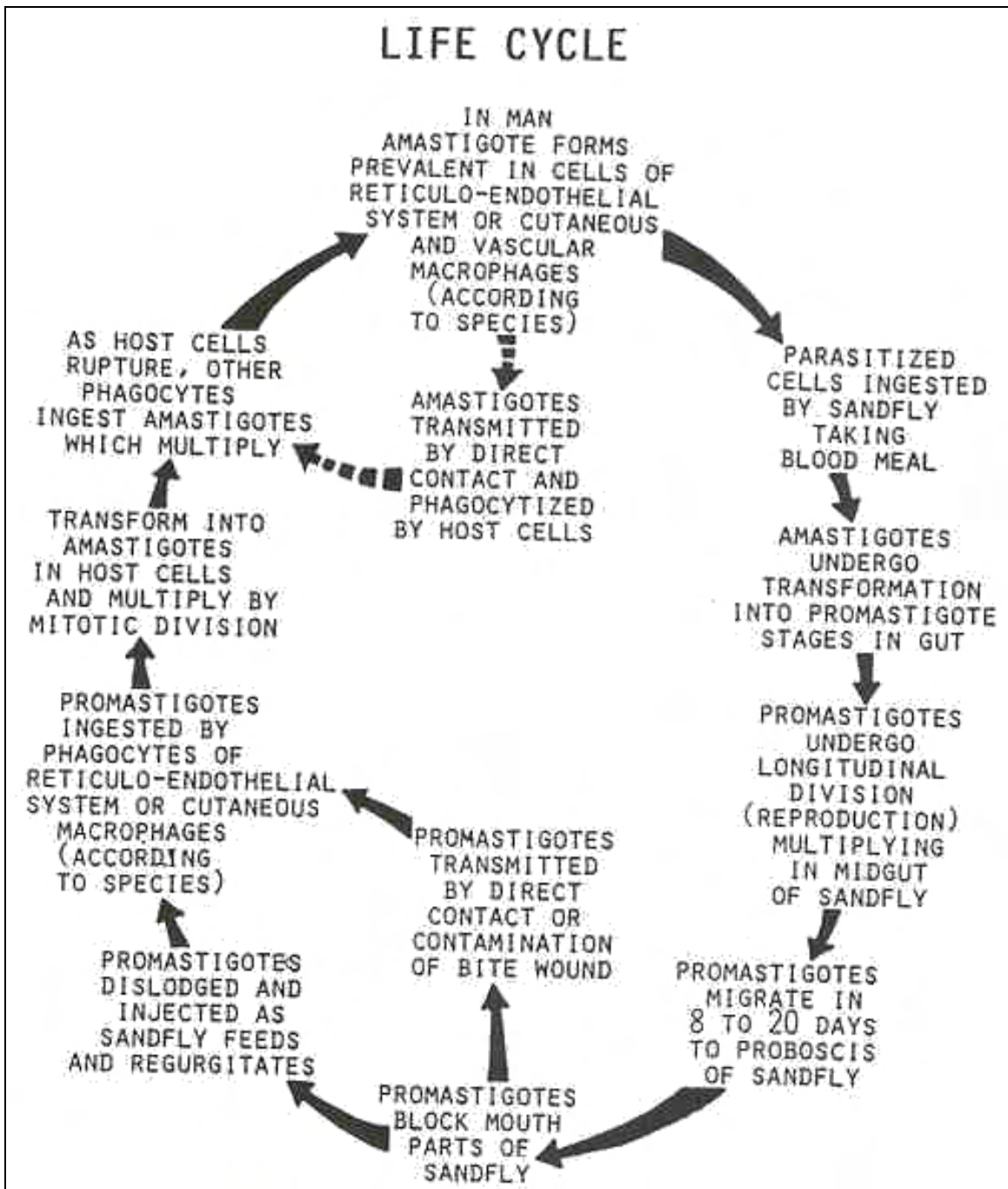


Figure 1-48. Life cycle of *Leishmania* species.

ORGANISM 2 -- Trypanosoma brucei

GENERAL CHARACTERISTICS

COMMON NAME

T. brucei gambiense: West African sleeping sickness.

T. brucei rhodesiense: East African sleeping sickness.

PATHOGENESIS

T. brucei gambiense: chronic, lasts for years.

T. brucei rhodesiense: easily cured at circulatory stage; fatal in three to nine months.

GEOGRAPHICAL DISTRIBUTION

T. brucei gambiense: western and central Africa.

T. brucei rhodesiense: eastern and central Africa; very seldom overlap; one may replace the other in an area.

HABITAT: Central nervous system, lymph nodes, spleen, and other internal organs.

INTERMEDIATE HOST: Tse-Tse fly, Glossina species.

RESERVOIR HOST: T. brucei gambiense: domestic animals

T. brucei rhodesiense: Game animals.

INFECTIVE FORM: Metacyclic trypomastigote.

MODE OF INFECTION: Bite of Tse-Tse fly.

Figure 1-49. Information on Trypanosoma brucei.

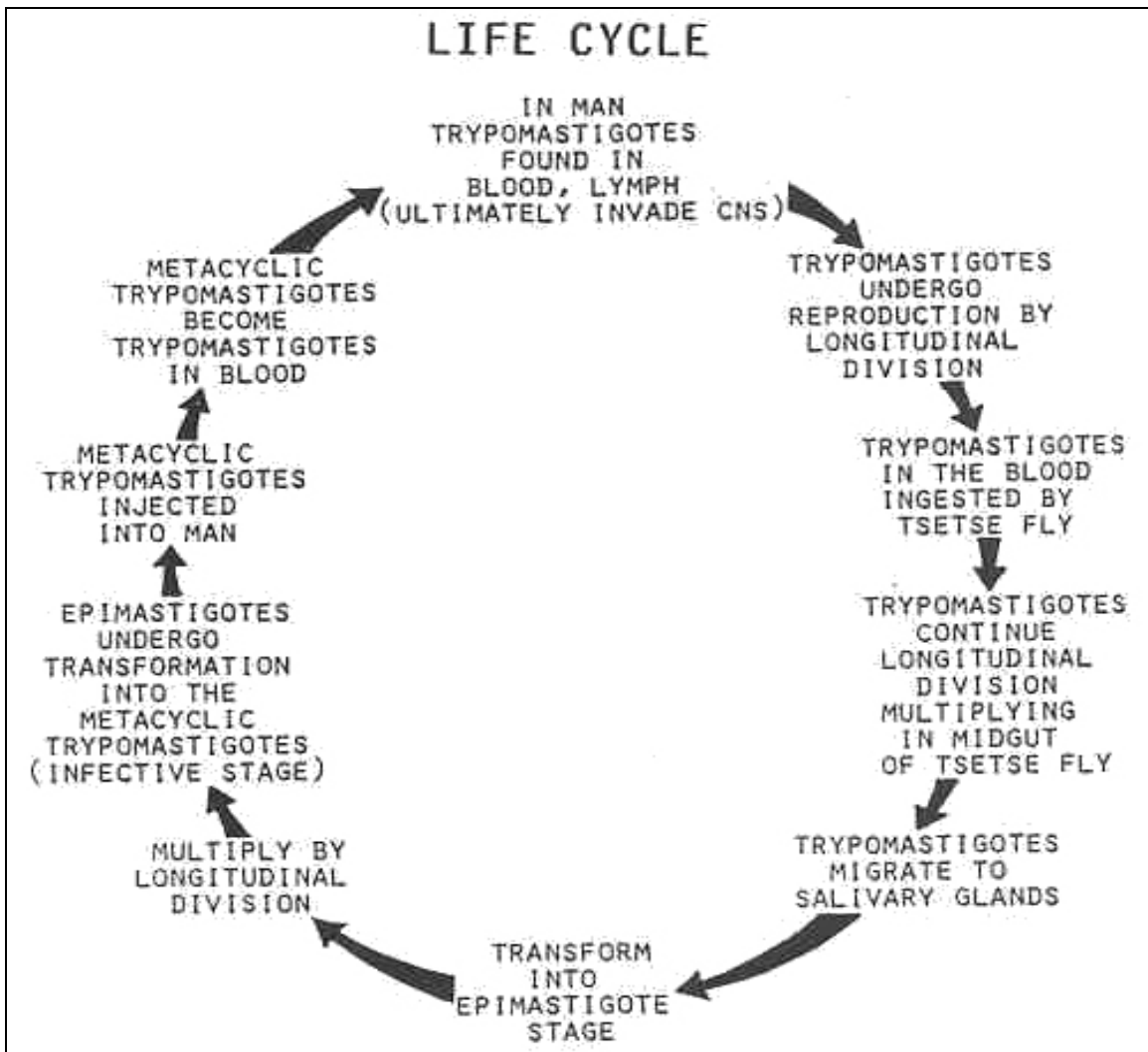


Figure 1-50. Life cycle of Trypanosoma brucei.

Trypanosoma brucei

TRYPOMASTIGOTE

SHAPE: "S" form.

KINETOPLAST: Small.

VOLUTIN GRANULES: Present.

DIVIDING FORMS: Prevalent.

LABORATORY IDENTIFICATION:

SPECIMEN SOURCE: Blood, lymph, spinal fluid.

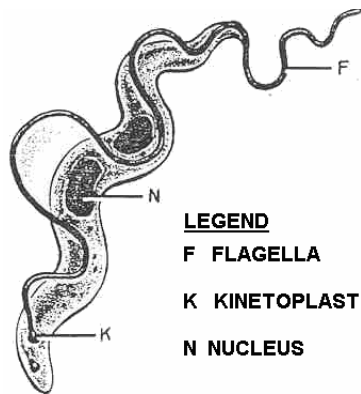


Figure 1-51. Trypomastigote stage of Trypanosoma brucei.

ORGANISM 3 -- Trypanosoma cruzi

GENERAL CHARACTERISTICS

COMMON NAME: Chaga's disease or American Trypanosomiasis.

GEOGRAPHICAL DISTRIBUTION: Western hemisphere (Central and South America).

PATHOGENESIS: Frequently fatal; localized, severe inflammation (chagoma; "Romana's sign"); cardiomyopathy; mega-disease.

XENODIAGOSIS: Infective forms in reduviid bugs; check weekly for one month.

HABITAT: Circulatory, central nervous, and reticuloendothelial systems; heart muscle; bone marrow.

INTERMEDIATE HOST: Reduviid bug; Triatoma and Panstrongylus species.

RESERVOIR HOST: Various mammals.

INFECTED FORM: Metacyclic trypomastigote.

MODE OF INFECTION: Fecal contamination of the bite.

LABORATORY IDENTIFICATION:

SPECIMEN SOURCE: Blood

Figure 1-52. Information on Trypanosoma cruzi.

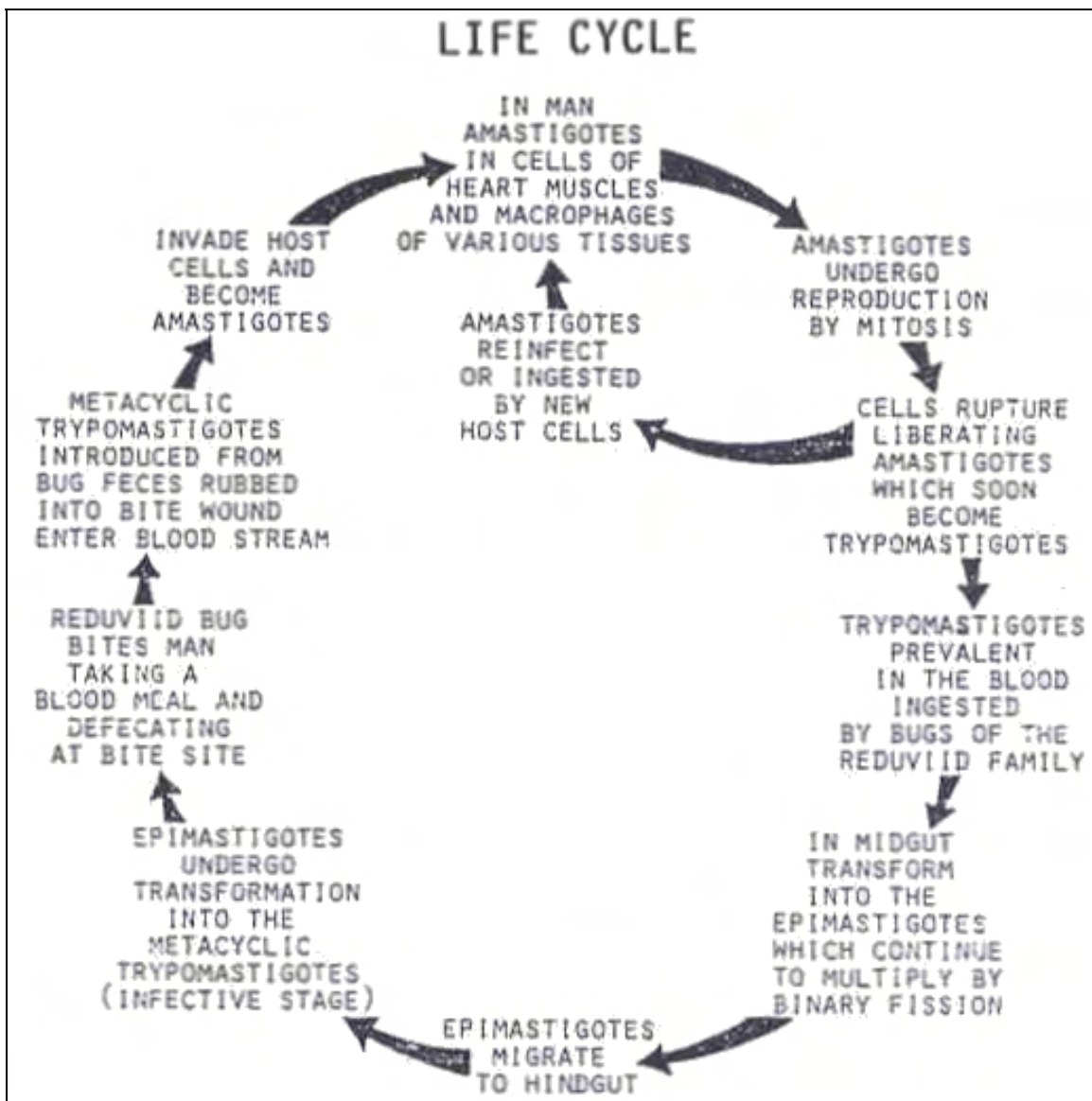


Figure 1-53. Life cycle of Trypanosoma cruzi.

Trypanosoma cruzi

TRYPOMASTIGOTE

SHAPE: "C" and "U" form.

KINETOPLAST: Large.

VOLUTIN GRANULES: Absent (usually)..

DIVIDING FORMS: Rare.

LABORATORY IDENTIFICATION:

SPECIMEN SOURCE: Blood

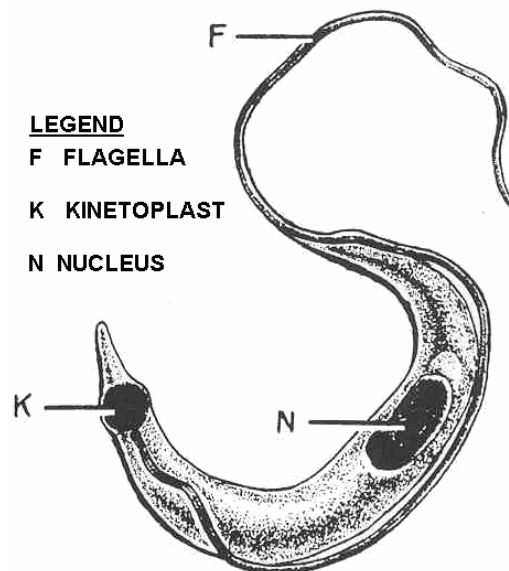


Figure 1-54. Trypomastigote stage of Trypanosoma cruzi.

Continue with Exercises

EXERCISES, LESSON 1

INSTRUCTIONS: Answer the following exercises by marking the lettered response that best answers the exercise, by completing the incomplete statement, or by writing the answer in the space provided at the end of the exercise.

After you have completed all the exercises, turn to "Solutions to Exercises" at the end of the lesson and check your answers. For each exercise answered incorrectly, reread the material referenced with the solution.

1. Can all of the structural stages seen in the genera Leishmania and Trypanosoma be found in a human host?
 - a. Yes.
 - b. No.

2. Chaga's disease is transmitted by:
 - a. The bite of a Tse-Tse fly.
 - b. The bite of a reduviid bug.
 - c. The feces of a reduviid bug.
 - d. Ingestion of infected game animals.

3. Which of the following statements best describes a phase in the life cycle of Leishmania species?
 - a. The infective form is injected by the bite of a sandfly.
 - b. Phagocytic RE cells ingest the infective form.
 - c. The promastigote stage occurs in the gut of the intermediate host.
 - d. All of the above.

4. The most easily recognized structure in a protozoan cell is:
 - a. Cytoplasmic reticulum.
 - b. Ectoplasm.
 - c. Nucleus.
 - d. Golgi complex.

5. Montezuma's revenge is caused by:
 - a. Entamoeba coli.
 - b. Entamoeba histolytica.
 - c. Endolimax nana.
 - d. Entamoeba polecki.

6. The infective form of Naegleria fowleri is:
 - a. The ciliated trophozoite.
 - b. The quadri-nucleated cyst.
 - c. The promastigote.
 - d. The biflagellated trophozoite.

7. Members of the class Zoomastigophora move by means of:
 - a. Flagella.
 - b. Pseudopodia.
 - c. Gliding.
 - d. Cilia.

8. If a trophozoite with 8 flagella is recovered from a fecal specimen, it is likely to be:
- Chilomastic mesnili.
 - Trichomonas hominis.
 - Giardia lamblia.
 - Enteromonas hominis.
9. The infective form of Trichomonas vaginalis is the:
- Mature cyst.
 - Trophozoite.
 - Quadri-nucleated cyst.
 - Uninucleate cyst.
10. The organism which can only be differentiated from Entamoeba histolytica in the cystic stage by its size is:
- Entamoeba hartmanii.
 - Entamoeba coli.
 - Entamoeba Dolecki.
 - Endolimax nana.
11. Locomotion among members of the class Rhizopoda is accomplished by organelles called:
- Flagella.
 - Cilia.
 - Pseudopodia.
 - None of the above.

12. Cytoplasm in the trophozoite stage of Entamoeba coli is often described as:
- Finely granular with no inclusions.
 - "Dirty" and vacuolated with yeast, bacteria and molds.
 - Coarsely granular with RBC inclusions.
 - "Clean" with yeast, bacteria, and molds.
13. A large, well defined glycogen vacuole is characteristic of which of the following organisms?
- Entamoeba histolytica.
 - Endolimax nana.
 - Entamoeba coli.
 - Iodamoeba butschlii.
14. The term lemon-shape best describes the cysts of:
- Chilomastix mesnili.
 - Dientamoeba fragilis.
 - Giardia lamblia.
 - Enteromonas hominis.
15. A possible mode of infection for Dientamoeba fragilis would be:
- Injection by an arthropod vector.
 - Ingestion with the ova of pinworm.
 - Through nasal passages while diving into water.
 - Through sexual intercourse.

16. The appearance of two fibrils joined in the shape of a "bird's beak" is characteristic of the cysts of which organism?
- Enteromonas hominis.
 - Endolimax nana.
 - Retortamonas intestinalis.
 - Leishmania species.
17. A diagnostic method used to recover the infective forms of Trypanosoma cruzi is:
- Fecal concentration.
 - Collection of urethral or vaginal discharge.
 - Xenodiagnosis.
 - Collection of duodenal aspirates.
18. Which of the following sites serves as a habitat for stages of the African Trypanosomes?
- Lymph nodes.
 - Spleen and other internal organisms.
 - Central nervous system.
 - All of the above.

Check Your Answers on Next Page

SOLUTIONS TO EXERCISES, LESSON 1

1. a (para 1-11)
2. c (para 1-11, org 3)
3. d (para 1-11, org 1)
4. c (para 1-3)
5. b (para 1-8, org 1)
6. d (para 1-8, org 5)
7. a. (para 1-9)
8. c (para 1-10; org 1)
9. b (para 1-10, org 3)
10. a (para 1-8, org 2)
11. c (para 1-6)
12. b (para 1-8, org 3)
13. d (para 1-8, org 7)
14. a (para 1-10, org 2)
15. b (para 1-10, org 4)
16. c (para 1-10, org 5)
17. c (para 1-11, org 3)
18. d (para 1-11, org 2)

End of Lesson 1

LESSON ASSIGNMENT

LESSON 2

Phylum Protozoo: Ciliata, Piroplasmaida, and Sporozoa.

LESSON ASSIGNMENT

Paragraphs 2-1 through 2-12.

LESSON OBJECTIVES

After completing this lesson, you should be able to:

- 2-1. Identify the organism characteristics of parasitic members of Class Ciliata.
- 2-2. Select a statement that best describes the life cycle of a member of Class Ciliata.
- 2-3. Identify the organism characteristics of parasitic members of Class Piroplasmaida.
- 2-4. Select a statement that best describes the life cycle of a member of Class Piroplasmaida.
- 2-5. Identify the organism characteristics of members of Class Sporozoa.
- 2-6. Select a statement that best describes the life cycle of a member of Class Sporozoa.
- 2-7. Identify the specimen of choice for recovery of specific protozoan organisms.
- 2-8. Identify the special techniques required for recovery of specific protozoan organisms.

SUGGESTION

After completing the assignment, complete the exercises of this lesson. These exercises will help you to achieve the lesson objectives.

LESSON 2

PHYLUM PROTOZOO: CILIATA, PIROPLASMASIOA AND SPOROZOA

Section I. CLASS CILIATA

2-1. GENERAL DESCRIPTION

These organisms use small, hair-like structures called cilia (singular: cilium) for locomotion. The outer envelope of the organism is a tough but flexible area called the pellicle. Food absorption is carried out by gathering food particles with the cilia and forcing them down the gullet (cytostome), where a vacuole is produced which surrounds the food. Digestion is accomplished by internal enzymes. Excretion of the unused food is accomplished by expulsion through the anal pore (cytopyge). See figure 2-1.

2-2. RESPIRATION AND REPRODUCTION

Hydrostasis with the environment is controlled by a pair of contractile vacuoles. Respiration is performed by diffusion through the cell membrane. Reproduction may be attained by simple cell division or by a complex exchange of genetic material between two individuals. There is only one member of this class which is pathogenic to man: Balantidium coli.

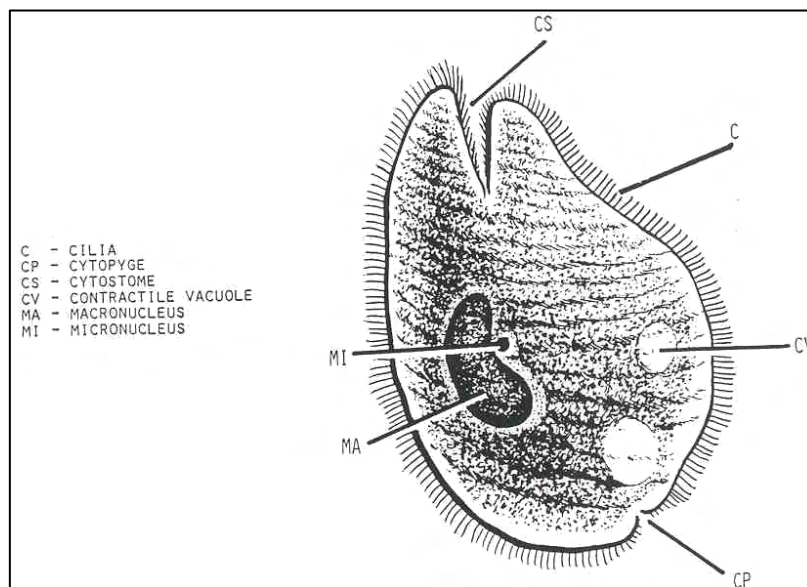


Figure 2-1. Typical ciliate.

2-3. PARASITIC MEMBER OF CLASS CILIATA

See figures 2-2 through 2-4 for an example.

ORGANISM 1--Balantidium coli
GENERAL CHARACTERISTICS

Only ciliate parasitic to man.

COMMON NAME: Balantidiasis, balantidial dysentery.

PATHOGENESIS: Invasion of intestinal mucosa and submucosa.

GEOGRAPHICAL DISTRIBUTION: Cosmopolitan.

HABITAT: Cecum.

INTERMEDIATE HOST: None.

RESERVOIR HOST: Hogs.

INFECTIVE FORM: Mature cyst.

MODE OF INFECTION: Ingestion.

LABORATORY IDENTIFICATION:

SPECIMEN OF CHOICE: Feces.

Figure 2-2. Information on Balantidium coli.

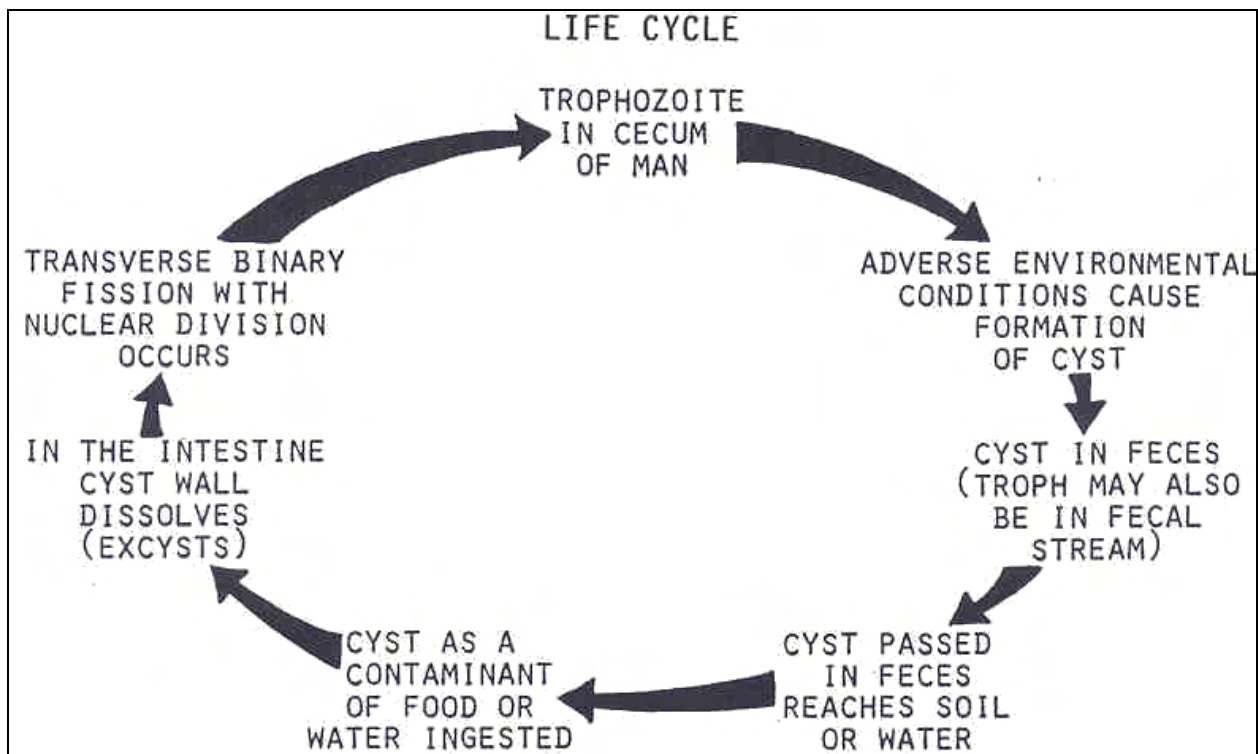


Figure 2-3. Life cycle of Balantidium coli.

Balantidium coli

TROPHOZOITE

SIZE: 40 to 50 by 50 to 70 μ .

SHAPE: Sac-like.

NUCLEUS: Macronucleus: large, enlongate, kidney-shape (mitotic division);
micronucleus: small, spherical (amitotic).

CYTOPLASM: Cell membrane covered with a delicate pellicle.

CILIA: Locomotion and food procurement; fine hair-like projections.

GULLET: Cytostome; anterior end: funnel shape peristome; posterior end:
rounded, peristome.

CYTOPYGE: Excretory pore, posterior.

PULSATING VACUOLES: One or two.



CYST

SIZE: 30 by 55 μ .

SHAPE: Oval to round.

NUCLEUS: Only the macronucleus is seen.

CYTOPLASM: Double cyst wall; remnants of cilia and gullet.

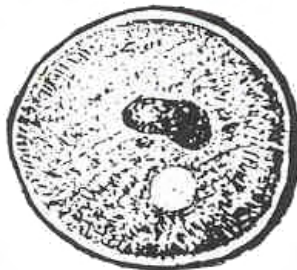


Figure 2-4. Stages of B. coli.

Section II. CLASS PIROPLASMASIDA

2-4. CLASS

Members of Class Piroplasmida, genus Babesia are characterized by bodies which are small, pyriform to ameboid. They possess no spores, flagella, or cilia.

2-5. FUNCTION

The reproduction is asexual by cell division or schizogony. In the life cycle, ticks are used as vectors. In some publications, these organisms are placed in the Class Sporozoa.

2-6. PARASITIC MEMBER OF CLASS PIROPLASMASIDA

See figure 2-5 through 2-7 for an example.

ORGANISM 1--CLASS Piroplasmida--Genus Babesia

GENERAL CHARACTERISTICS

COMMON NAME: Redwater fever; piroplasmosis; babesiosis.

PATHOGENESIS: Many species are pathogenic to vertebrates; over one hundred cases in humans (splenectomized persons are most susceptible); could be fatal.

GEOGRAPHICAL DISTRIBUTION: Most cases from Nantucket Island, Massachusetts.

HABITAT: Intracellular in RBCs.

INTERMEDIATE HOST: vertebrates; man.

RESERVOIR HOST:

TICKS: Definitive host, vector.

VERTEBRATES: Intermediate host.

INFECTIVE FORM TO MAN: Vermicle.

MODE OF INFECTION: Injection.

LABORATORY IDENTIFICATION:

SPECIMEN OF CHOICE: Blood.

Figure 2-5. Information on Babesia.

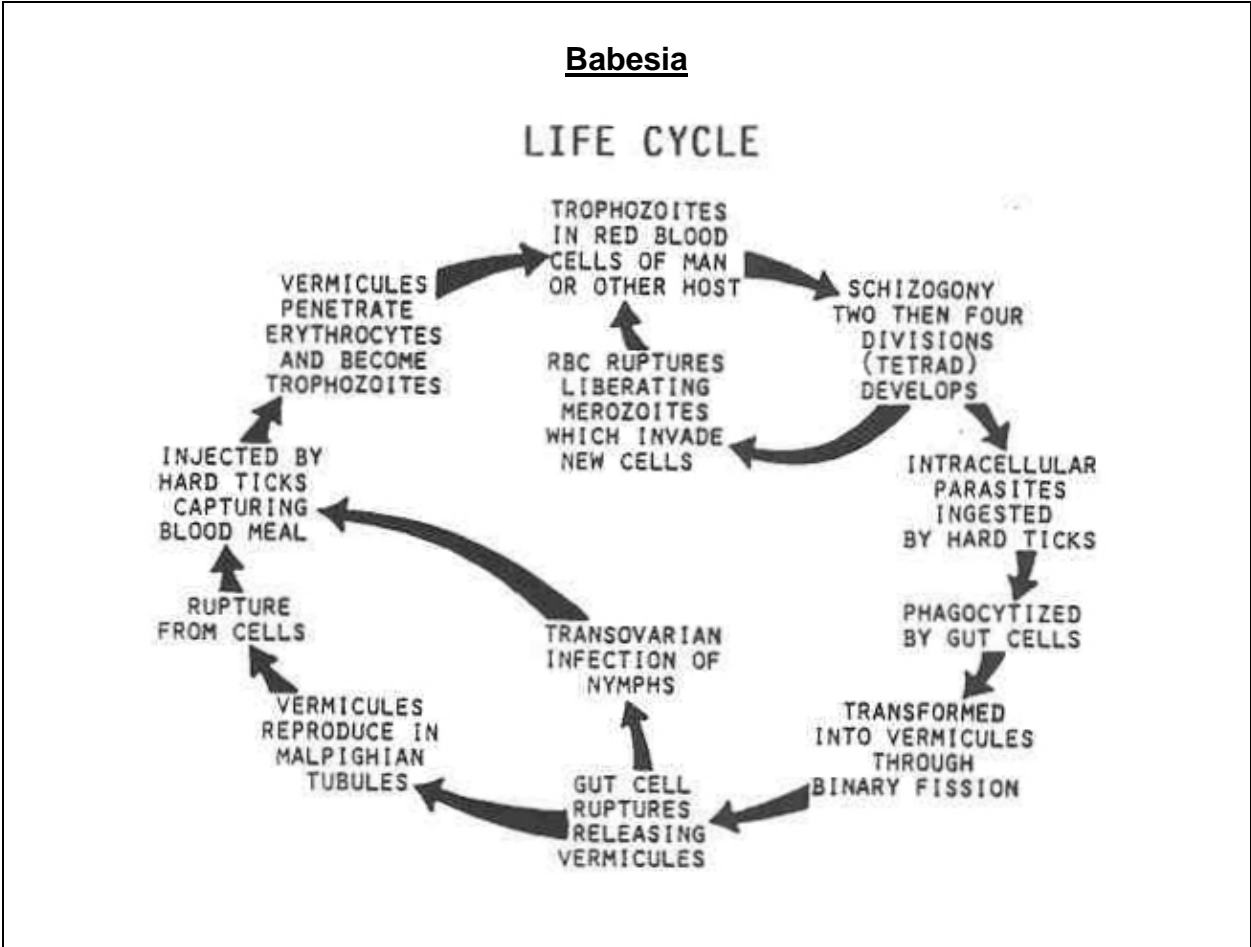


Figure 2-6. Life cycle of Babesia.

Babesia

TROPHOZOITE

SIZE: 4 by 1.5 μ .

SHAPE: Tear-drop; ameboid; ovoid; spherical.

Present within a vacuole in the RBC.

May be confused with P. falciparum.

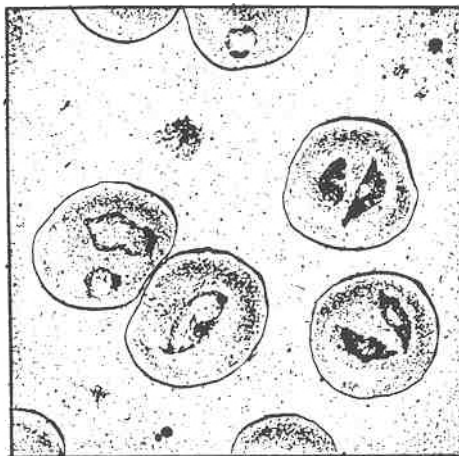


Figure 2-7. Trophozoite stage of Babesia.

Section III. CLASS SPOROZOA

2-7. GENERAL COMMENTS

Reproduction in this class is accomplished through both sexual and asexual cycles. All members are parasitic and usually require two hosts to complete the cycle. Sporozoans use body flexion, gliding, or undulation of longitudinal ridges as means of motility. Small pseudopods are used for feeding. There are three families in the class: family Eimeriidae, family Endodyococcidoridae, and family Plasmodiidae.

2-8. FAMILY EIMERIIDAE

The life cycle of the family Eimeriidae can be completed in one host, but two hosts may be used. The macrogametocytes and the microgametocytes are developed independently. The zygote is non-motile and sporozoites are formed inside a sporocyst. The members of this family parasitic to man are: Isospora belli, Eimeria species, and Cryptosporidium species.

2-9. FAMILY ENDODYCOCCIDORIDAE

All members are intracellular parasites of vertebrates. Three species are pathogenic to humans: Toxoplasma gondii, Sarcocystis hominis, and Pneumocystis carinii.

2-10. FAMILY PLASMODIIDAE

Plasmodium is the representative genus of this class. These organisms live as intracellular parasites in the red blood cells of the intermediate host (man) and multiply asexually through a process known as schizogony. In the definitive host, there is sexual reproduction which takes place in the gut, hemolymph, and salivary glands of the mosquito. The gametes are developed independently and the zygote (ookinete) is motile.

2-11. ORGANISMS OF CLASS SPOROZOA

See figures 2-8 through 2-31 for information on examples of organisms of Class Sporozoa.

ORGANISM 1--Isospora belli

GENERAL CHARACTERISTICS

COMMON NAME: Coccidiosis.

GEOGRAPHICAL DISTRIBUTION: Worldwide.

PATHOGENESIS: Few reported cases, rare local epidemics.

HABITAT: Ileocecal and jejunal region of intestines.

INTERMEDIATE HOST: None.

RESERVOIR HOST: None known.

INFECTIVE FORM: Oocyst.

MODE OF INFECTION: Ingestion.

LABORATORY IDENTIFICATION:

SPECIMEN OF CHOICE: Feces.

Figure 2-8. Information on Isospora belli.

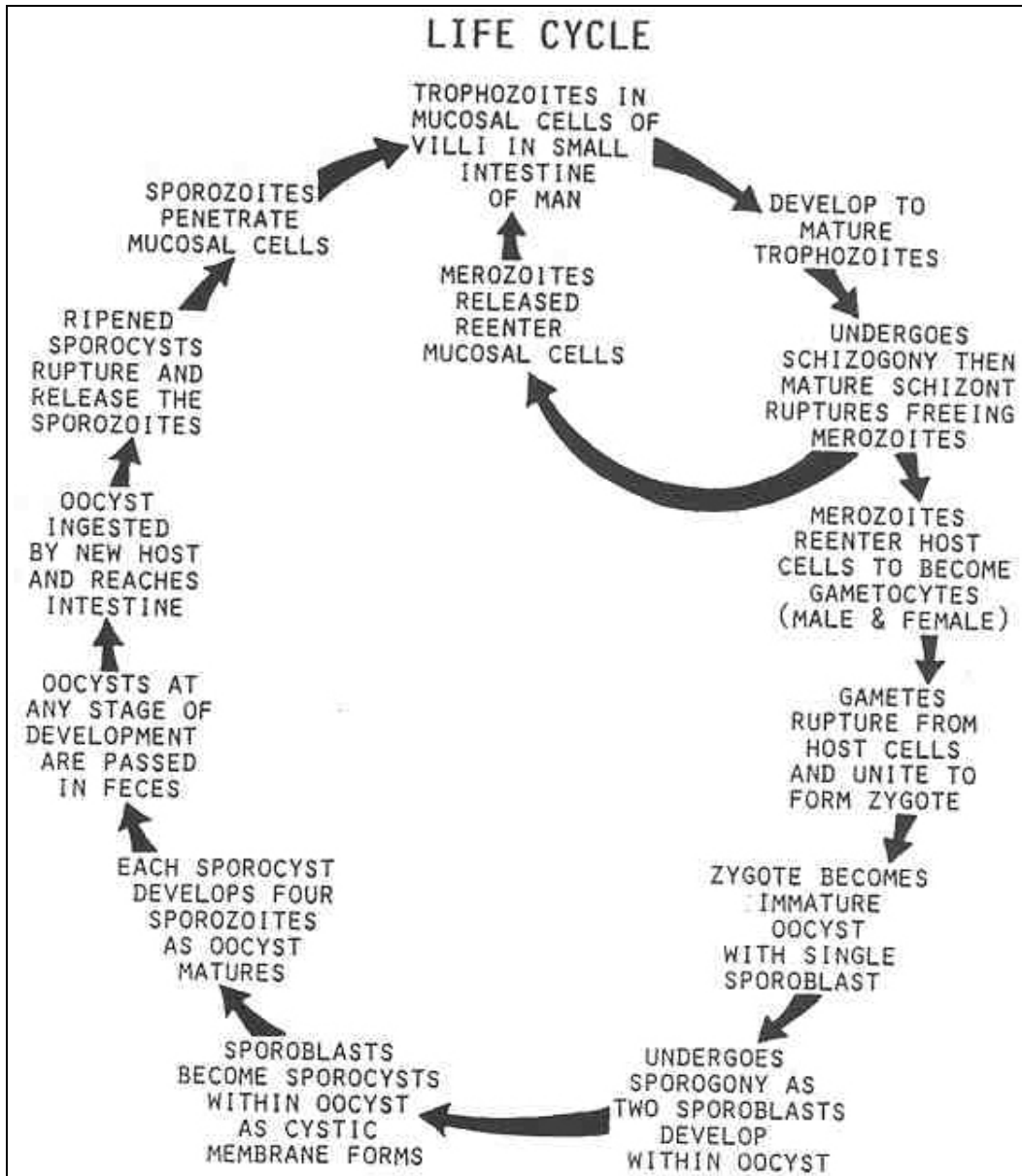


Figure 2-9. Life cycle of Isospora belli.

Isospora belli

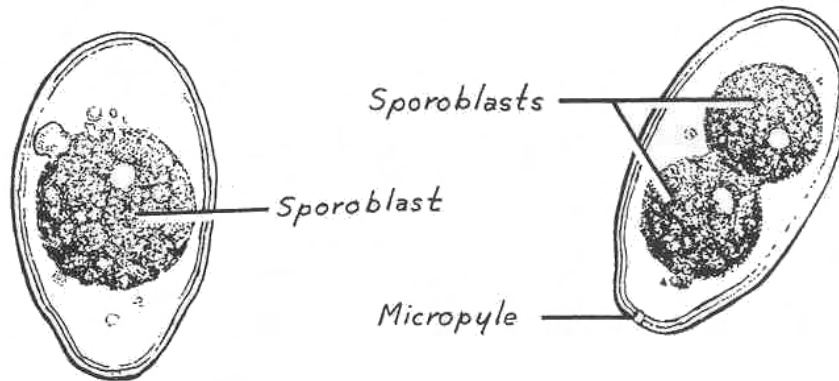
IMMATURE OOCYST

THIN CYST WALL

OVOID

12 x 30 μ

ONE OR TWO SPOROBLASTS



MATURE OOCYST

TWO SPOROCASTS: 8 x 12 μ

EACH SPOROCAST CONTAINS FOUR SPOROZOITES

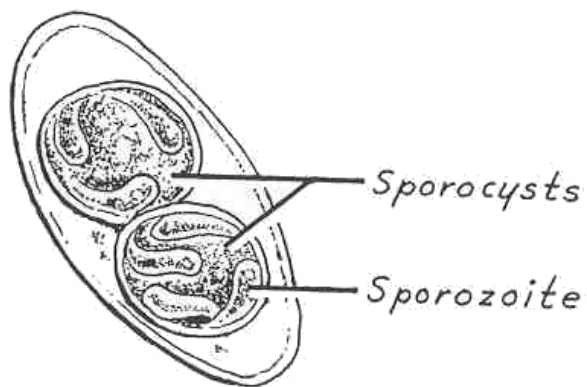


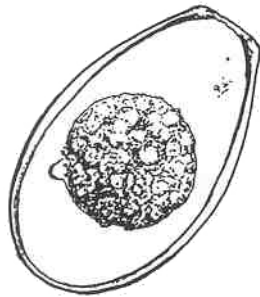
Figure 2-10. Stages of Isospora belli.

ORGANISM 2--Eimeria species

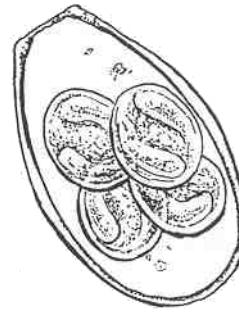
PARASITES OF BIRDS, REPTILES, AND MAMMALS OTHER THAN MAN

OOCYST

Similar to Isospora belli except for four sporocysts with two sporozoites in each.
SPECIMEN OF CHOICE: Fecal specimen, looking for oocyst.



IMMATURE OOCYST



MATURE OOCYST

Figure 2-11. Information on Eimeria.

ORGANISM 3--Cryptosporidium species

GENERAL CHARACTERISTICS

COMMON NAME: None.

GEOGRAPHICAL DISTRIBUTION: Cosmopolitan.

PATHOGENESIS: Normally a parasite in the intestines of reptiles, birds, and mammals other than man; increasing number of human cases, causing severe diarrhea mostly in immunosuppressed persons.

HABITAT: Intestines.

INTERMEDIATE HOST: None.

RESERVOIR HOST: Mammals.

INFECTIVE FORM: Mature oocyst.

MODE OF INFECTION: Ingestion.

LABORATORY IDENTIFICATION:

SPECIMEN OF CHOICE: Feces.

Figure 2-12. Information on Cryptosporidium.

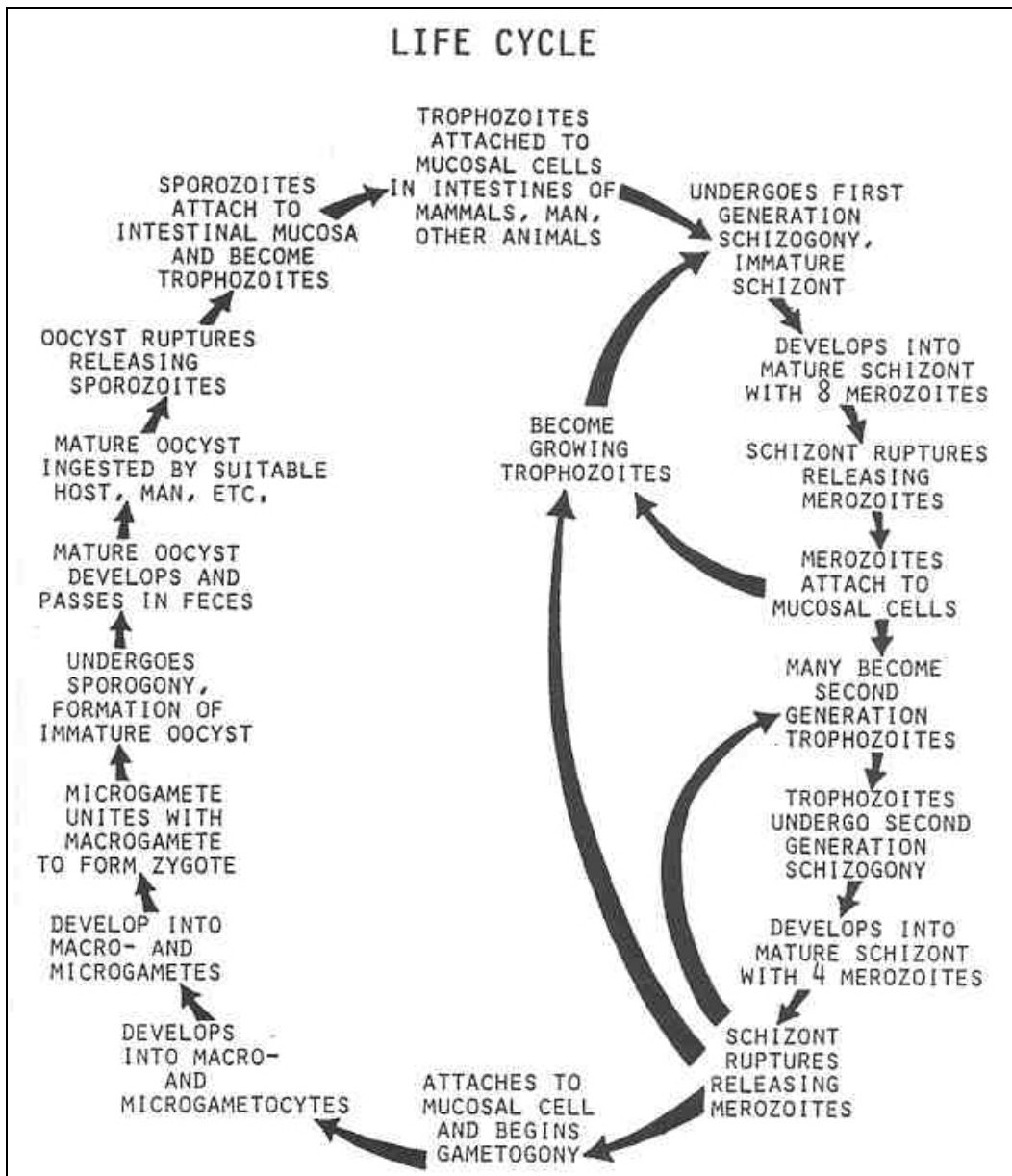


Figure 2-13. Life cycle of Cryptosporidium species.

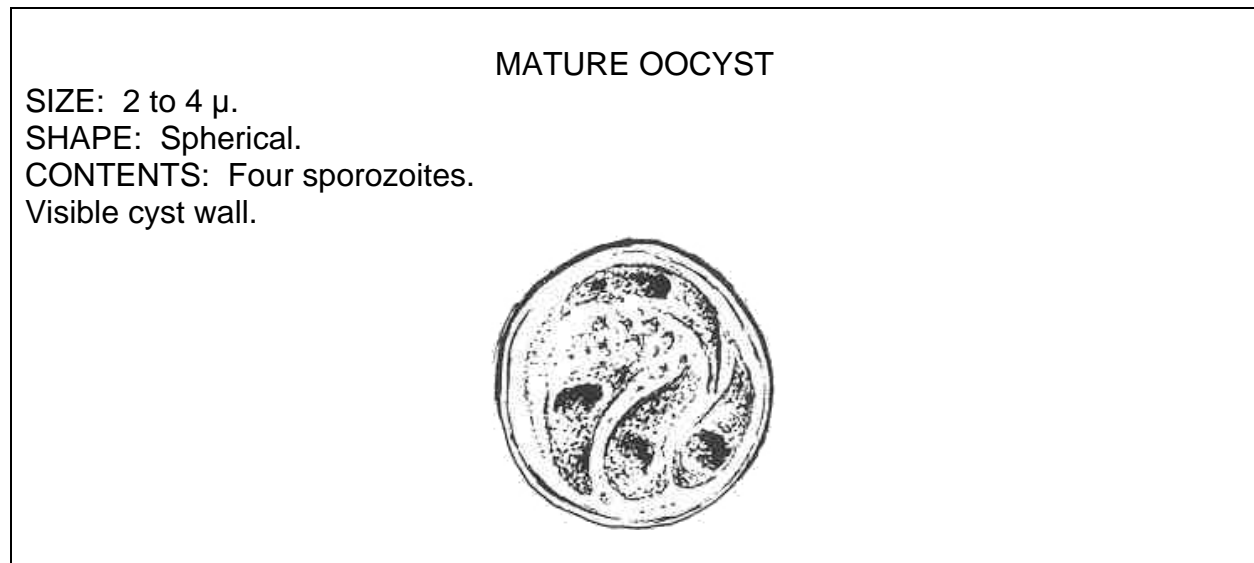


Figure 2-14. Oocyst of Cryptosporidium.

ORGANISM 4--Toxoplasma gondii

GENERAL CHARACTERISTICS

COMMON NAME: None.

GEOGRAPHICAL DISTRIBUTION: Worldwide.

PATHOGENESIS: 30 to 90 percent human infection; acquired: asymptomatic, rarely a severe systemic disease; congenital: acute or chronic; implicated as one of the leading causes of birth defects; primarily diagnosed serologically.

HABITAT: Intracellular parasite; infects any nucleated cell of the body; intestinal epithelium (initially) in felines only: predominance in brain and retina.

INTERMEDIATE HOST: Humans and many other mammals; cats and other felines are definitive hosts.

RESERVOIR HOST: Cats and other domestic animals (reservoirs for human infection).

INFECTIVE FORM: Infective oocysts from cat feces; or tissue trophozoites or cysts.

MODE OF INFECTION: Ingestion of oocysts; spread by the blood; placental penetration; ingestion of raw or poorly cooked meat.

LABORATORY IDENTIFICATION:

SPECIMEN OF CHOICE: Blood, tissue biopsy.

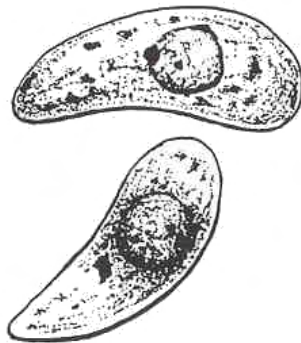
Figure 2-15. Information on Toxoplasma gondii.

Toxoplasma gondii

TACHYZOITES

ACUTE STAGES (GROUPS): Contains 8-16 tachyzoites (Giemsa stain) per infected cell.

SIZE: 3 x 6 μ ; crescent-shaped.
RED, Central nucleus.



GROSS MORPHOLOGY
(crescentic shape)

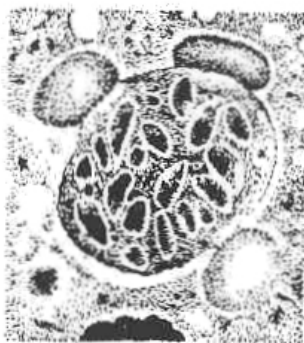

FREE ORGANISMS
(as seen in stained body fluids)

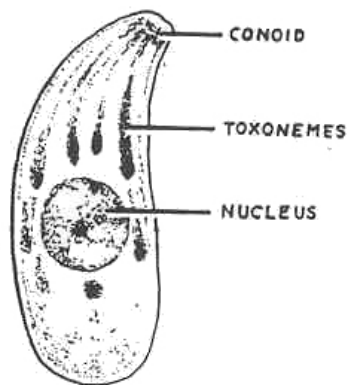
CYST

SIZE: 200 to 1000 μ .

BRADYZOITES: thousands per cyst; size--6 μ .



CYST FORMATION
(in tissue)



INTERNAL STRUCTURE

Figure 2-17. Stages of Toxoplasma gondii.

ORGANISM 5--Sarcocystis hominis (lindermanii)

GENERAL CHARACTERISTICS

(Proposed from comparable species in laboratory animals)

COMMON NAME: None.

GEOGRAPHICAL DISTRIBUTION: Cosmopolitan.

PATHOGENESIS: Usually a mild disease.

HABITAT: Muscle; intestinal tract.

INTERMEDIATE HOST: Usually herbivores.

RESERVOIR HOST: Carnivores.

INFECTIVE FORM: Cystozoites or sporozoites.

MODE OF INFECTION: Ingestion.

LABORATION IDENTIFICATION:

SPECIMEN OF CHOICE: Tissue biopsies.

Figure 2-18. Information on Sarcocystis hominis.

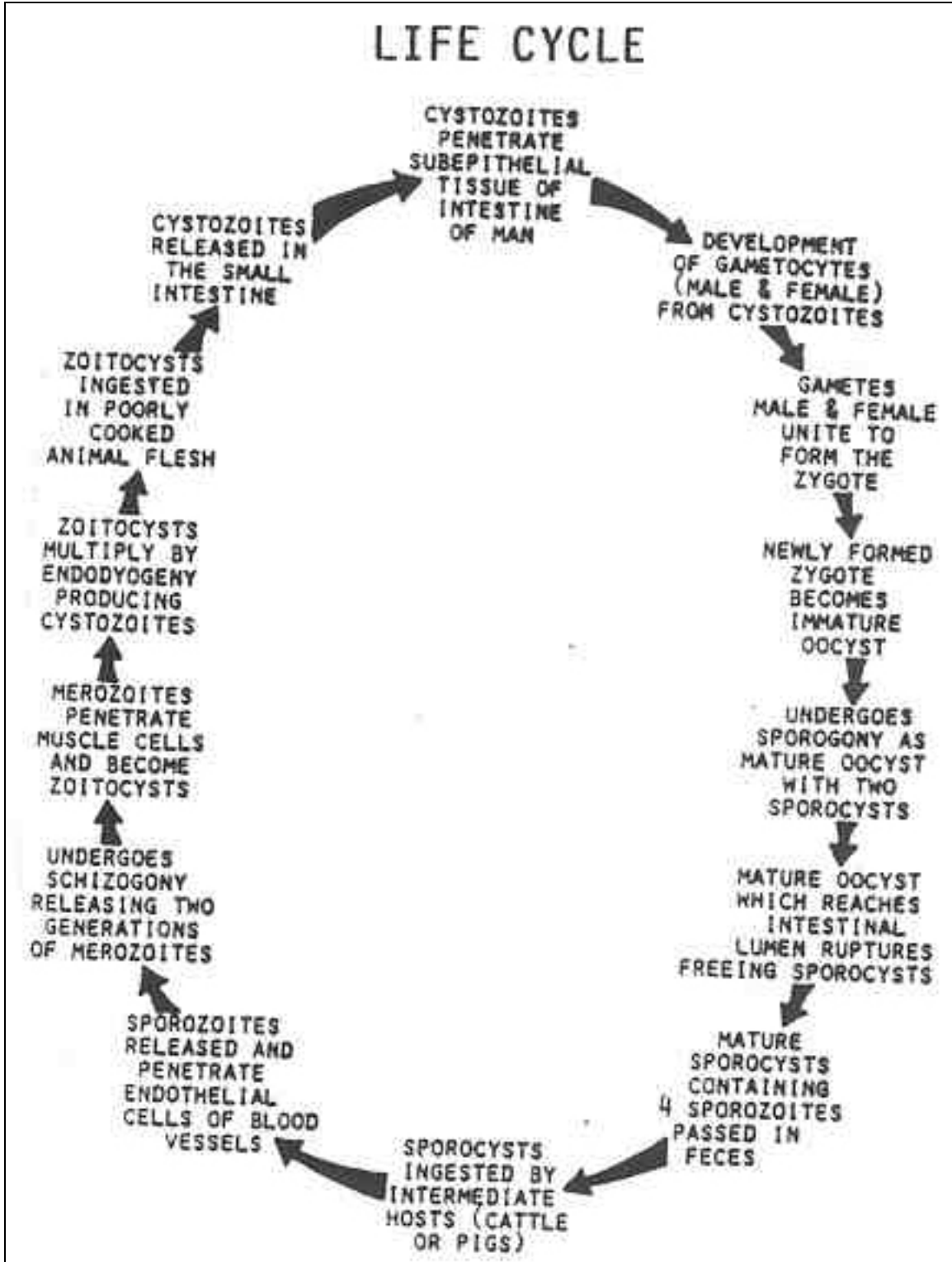


Figure 2-19. Life cycle of Sarcocystis hominis.

Sarcocystis hominis (lindermanii)

ZOITOCYST (SARCOCYST)

SIZE: Usually 1 to 2 mm; may be as big as 1 cm.

SHAPE: Elongate; cylindrical; spindle-shape.

CONTENTS: Internal septae and compartments full or cystozoites.

LIMITING MEMBRANE: With radial striations.

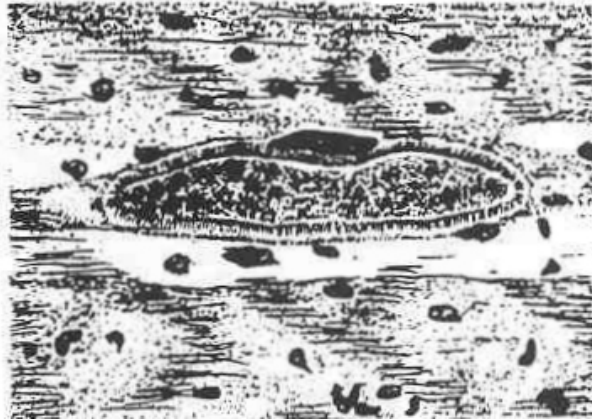

Figure 2-20. Zoitocyst S. hominis.

ORGANISM 6--Pneumocystis carinii

GENERAL CHARACTERISTICS

COMMON NAME: None.

GEOGRAPHICAL DISTRIBUTION: Cosmopolitan.

PATHOGENESIS: Causes interstitial plasma cell pneumonia usually in infants and immunocompromised persons.

HABITAT: Lungs.

INTERMEDIATE HOST: None.

RESERVOIR HOSTS: Rodents, a variety of animals.

INFECTIVE FORM: Mature cyst.

MODE OF INFECTION: Air-borne sputum particles inhaled, transplacental.

LABORATORY IDENTIFICATION:

SPECIMEN SOURCE: Pulmonary material; bronchial washings; biopsies.

SPECIAL TECHNIQUES: Giemsa's stain; methenamine silver nitrate, Gram-Weigert.

Figure 2-21. Information on Pneumocystis carinii.

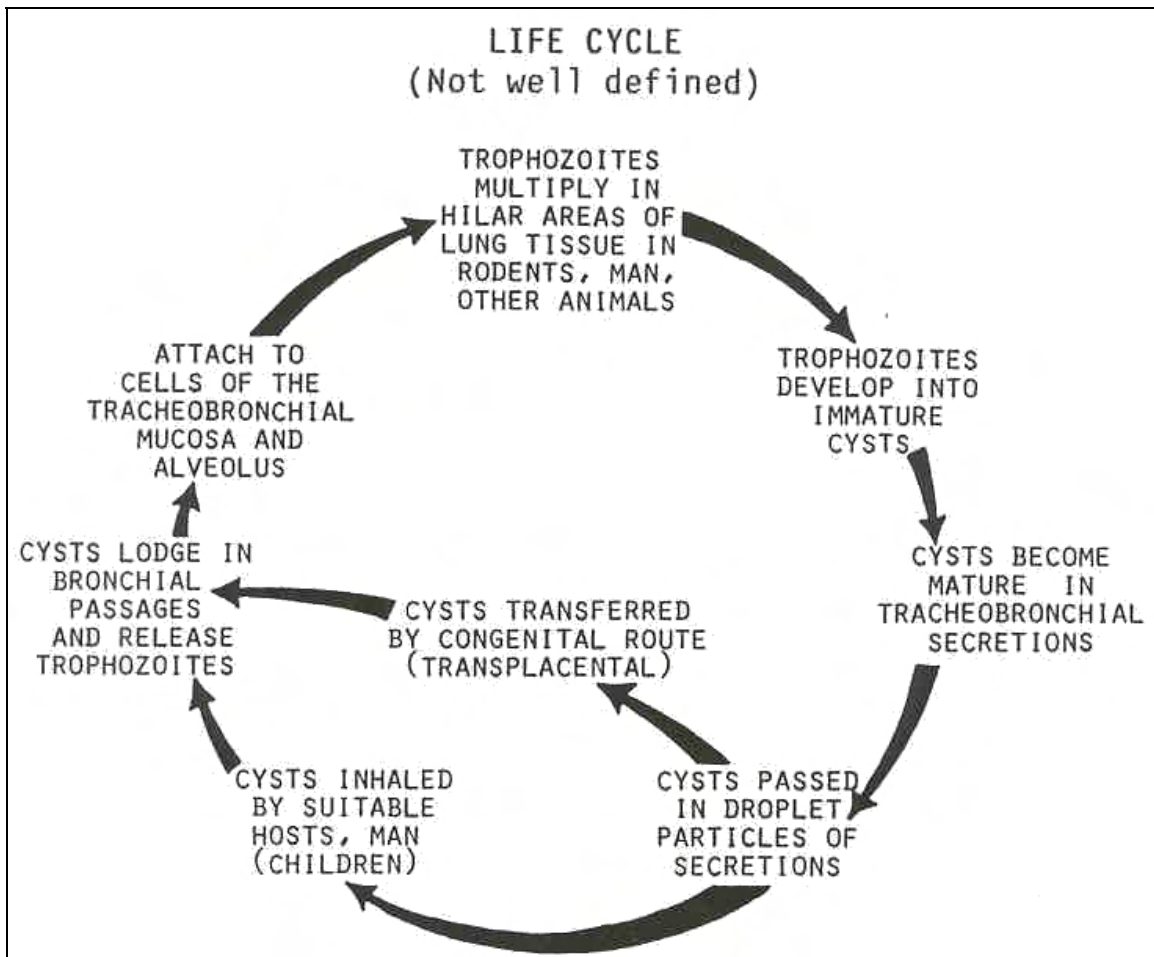


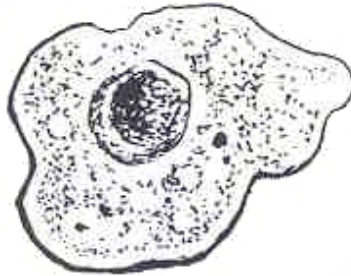
Figure 2-22. Life cycle of Pneumocystis carinii.

TROPHOZOITE

SIZE: 2 to 4 μ .

SHAPE: Irregular.

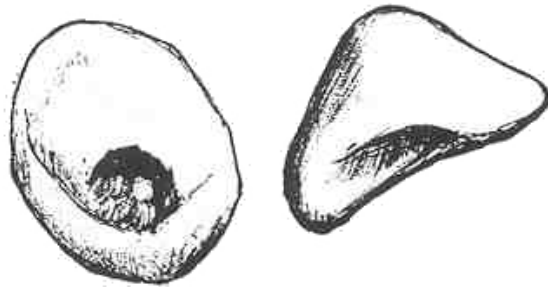
CONTENTS: Central nucleus.



IMMATURE CYST

SIZE: 5 to 12 μ .

SHAPE: Spherical, often collapsed.



MATURE CYST

SIZE: 5 to 12 μ .

SHAPE: Spherical.

CONTENTS: 8 nuclei, often in "rosette" arrangement.

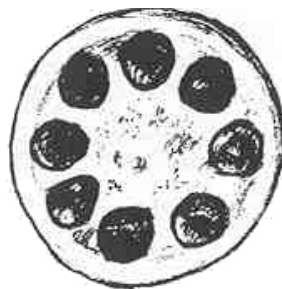


Figure 2-23. Stages of P. carinii.

ORGANISM 7--Plasmodium species

GENERAL CHARACTERISTICS

HISTORY: Symptoms described by 1550 BC (Ebers papyrus); recovery of Countess d'El Chinchon 1623 to 1632); associated with "bad (mal) swamp air" (aria); Laveran described the parasite in 1880 AD.

COMMON NAME

Plasmodium vivax--Benign tertian malaria.

Plasmodium ovale--Ovale tertian malaria.

Plasmodium malariae--Quartan malaria.

Plasmodium falciparum--Malignant tertian malaria.

PATHOGENESIS: Cyclic fever and chills; aches and general malaise.

Plasmodium vivax: Usually mild; parasitemia up to five percent; 47 percent of reported cases; relapses due to recurring liver phases (secondary exoerythrocytic); fever cycle (chills) are every 45 hours (average).

Plasmodium ovale: Usually mild; parasitemia less than one percent; less than one percent of reported cases; questionable relapses; fever cycle is 49 hours (average).

Plasmodium malariae: Usually mild (severe kidney involvement in children, may be fatal); parasitemia up to one percent; less than three percent of reported cases; longest incidence of recrudescence (up to 30 years); fever cycle is 72 hours.

Plasmodium falciparum: Usually severe (blocking of capillaries, involvement of major organs, algid malaria, black water fever, drug resistant strains have been recognized); parasitemia up to 40 percent; 49 percent of total reported cases; short recrudescence relapse with no secondary exoerythrocytic phases; fever cycle is 36 to 48 hours, often asynchronous.

Figure 2-24. Information on Plasmodium (continued).

Plasmodium

GEOGRAPHICAL DISTRIBUTION

P. vivax--Temperate and tropic zones.

P. ovale--Mainly Africa and western Pacific islands.

P. malariae and P. falciparum--Tropics and subtropics.

TREATMENT

MALARIOUS ATTACK: Chloroquine and Amodiaquine are very effective drugs for rapid relief (no effect against the exoerythrocytic phase); Pyrimethamine and Chlorquanide are slow but can eradicate tissue stages of P. falciparum.

SUPPRESSION (PREVENTION OR POSTPONEMENT OF ATTACKS): Chloroquine, Amodiaquine, Pyrimethamine, and Chlorquanide destroy the erythrocytic parasite; Primaquine is effective against gametocytes and exoerythrocytic parasites.

PROPHYLAXIS: P. falciparum--pyrimethamine and primaquine: Black water fever; corticosteroids: Resistant strains of P. falciparum; quinine, Fansidar and Mefloquine.

CONTROL: Eradication of the vector (female Anopheles mosquito); elimination of source (reservoir host and asymptomatic carriers).

PROPHYLAXIS: Prevent mosquito bites and drug prophylaxis.

DIRECT TRANSMISSION: Screen blood donor and pregnant female.

HABITAT IN MAN: Liver and blood.

INTERMEDIATE HOST: Man is the intermediate host; the mosquito is the definitive host.

RESERVOIR HOST: Primate.

INFECTIVE FORM: To man is the sporozoite; to mosquitoes are both macrogametocytes and microgametocytes.

MODE OF INFECTION: Injection.

Figure 2-24. Information on Plasmodium (concluded).

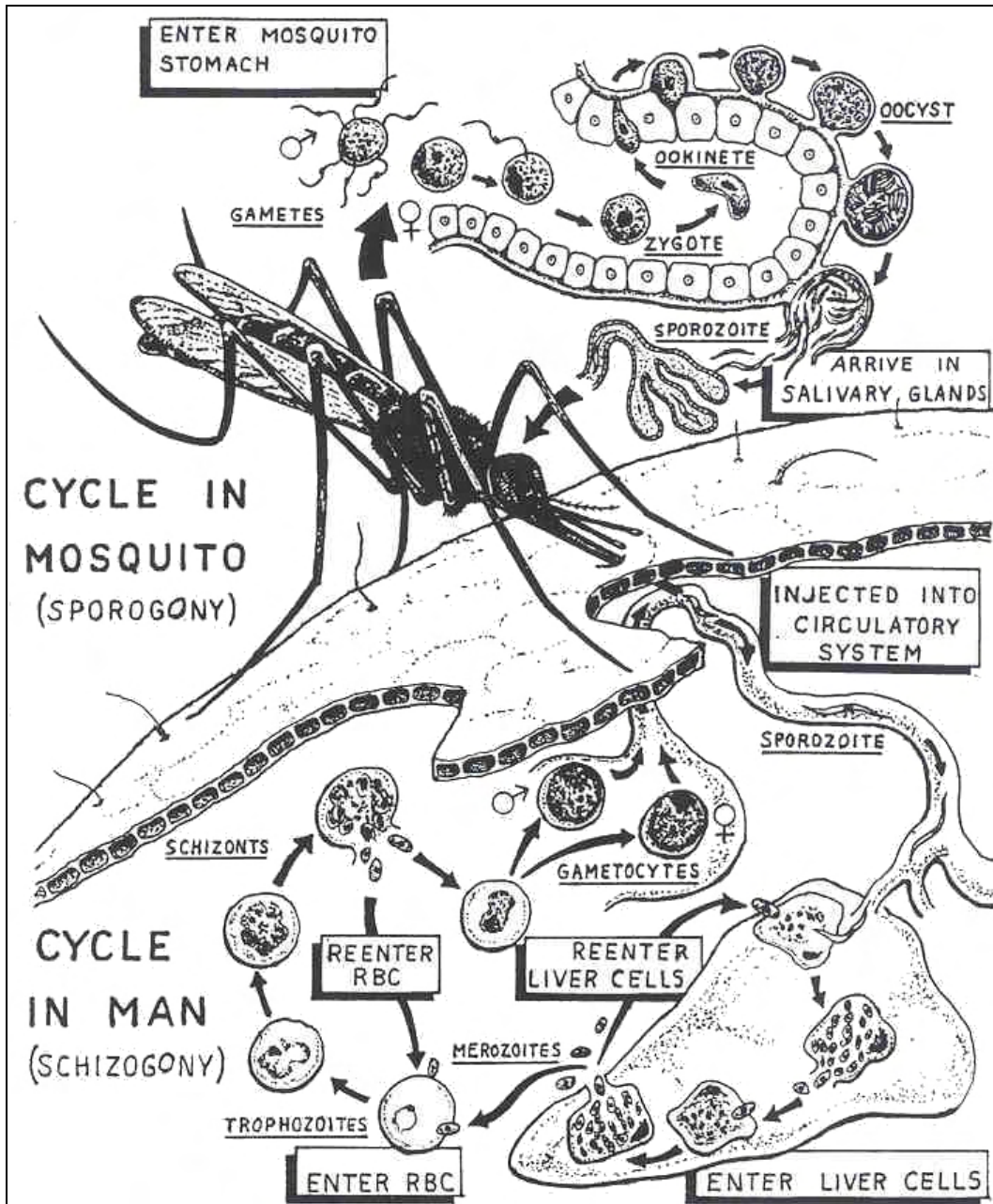


Figure 2-25. Life cycle of *Plasmodium* species.

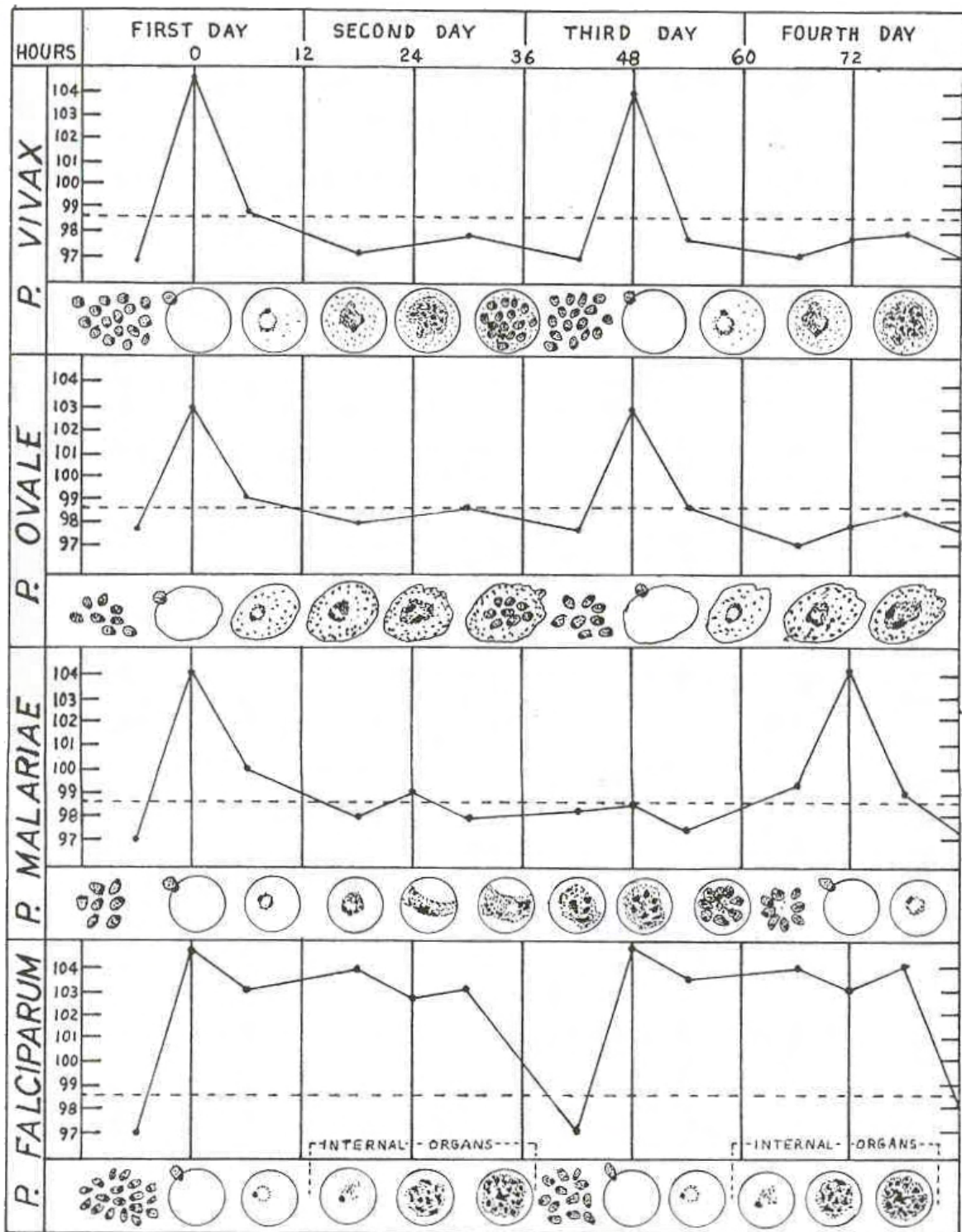


Figure 2-26. Correlation of the fever-chill cycles and erythrocytic cycles of the human Plasmodi.

Plasmodium species

YOUNG TROPHOZOITES--RING FORMS

SPECIMEN OF CHOICE: Capillary blood.

TIME OF COLLECTION: About 8 to 12 hours after the fever peak and about 8 to 12 hours intervals thereafter (midway between the fever peaks results in clearly defined morphology).

REPORT AS PLASMODIUM SPECIES: Unless 5 or more young rings per oil immersion field without Schuffner's granules are present: this case represents P. falciparum (thin smear only).

CHROMATIN DOT: Small; magenta-red.

CYTOPLASM: Light blue; 1 to 3 μ in size.

HEMOZOIN PIGMENT: Usually absent.

INFECTED ERYTHROCYTE: May be macrocytic and pale with Schuffner's granules in cases of P. vivax and P. ovale.

NOTE: See figures 1-1, 2-1, and 4-1 in Appendix C for additional illustrations.

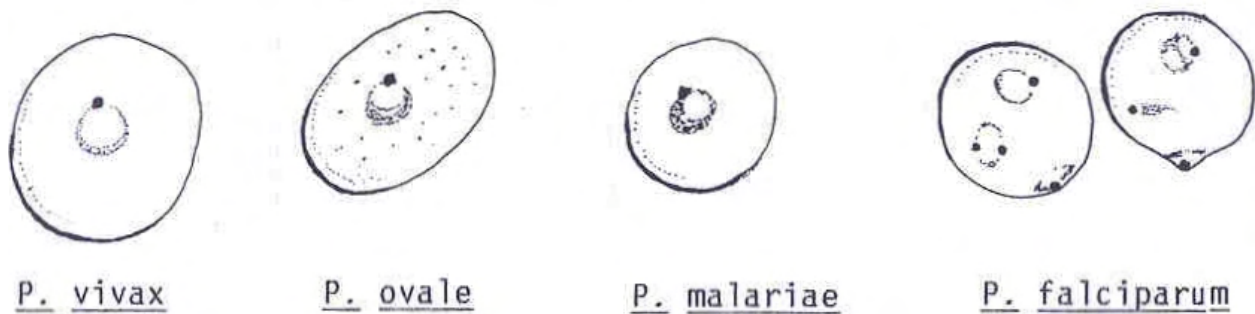


Figure 2-27. Stages of Plasmodia--young trophozoites--ring forms.

Plasmodium species

GROWING TROPHOZOITES

P. vivax

CHROMATIN MASS: Small to medium; light magenta.

CYTOPLASM

COLOR: Light blue.

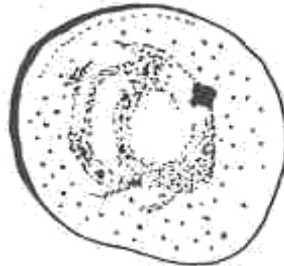
DENSITY: Flimsy; amoeboid shape.

SIZE--8 to 10 μ ; spreads out through the erythrocyte.

VACUOLES: Multiple.

HEMOZOIN PIGMENT: Diffused; light gold rods.

INFECTED ERYTHROCYTE: Enlarged; pale; fine Schuffner's granules.



P. ovale

CHROMATIN MASS--Medium to large; dark magenta.

CYTOPLASM

COLOR--Darker blue than P. vivax.

Density--Slight amoeboid activity.

SIZE--4 to 7 μ ; less than half of erythrocyte filled.

VACUOLES--May have one to two.

HEMOZOIN PIGMENT--Golden brown; often diffused.

INFECTED ERYTHROCYTE--Slightly enlarged; pale Schuffners granules appear early; may be oval and/or fimbriated

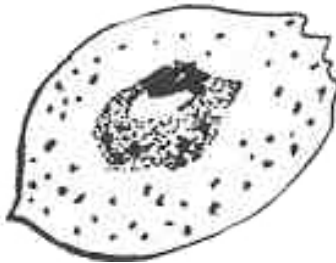


Figure 2-28. Stages of Plasmodia--growing trophozoite (continued).

P. malariae

CHROMATIN MASS: Medium to large; dark magenta.

CYTOPLASM

COLOR: Darker blue.

DENSITY: Band forms; basket forms.

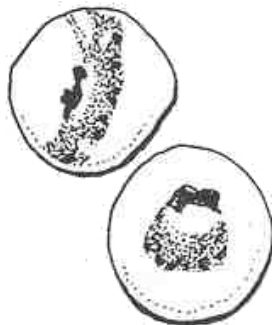
SIZE: 4 to 7 μ .

VACUOLES: May have multiple.

HEMOZOIN PIGMENT: Dark brown.

INFECTED ERYTHROCYTE: Normal appearance; may be slightly microcytic.

NOTE: See figures 1-3, 2-2, 2-3, 3-1 in Appendix C for additional illustrations.



P. falciparum

CHROMATIN MASS: Very small; some with double masses; applique forms common; magenta.

CYTOPLASM

COLOR: Blue.

DENSITY: Delicate; flame shapes common.

SIZE: 2 to 4 μ .

HEMOZOIN PIGMENT: Dark brown; usually not seen.

INFECTED ERYTHROCYTE: Normal appearance.

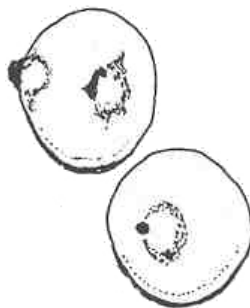


Figure 2-28. Stages of Plasmodia--growing trophozoite (concluded)

Plasmodium species

MATURE TROPHOZOITE

P. vivax

CHROMATIN MASS: Small to medium.

CYTOPLASM

COLOR: Light blue.

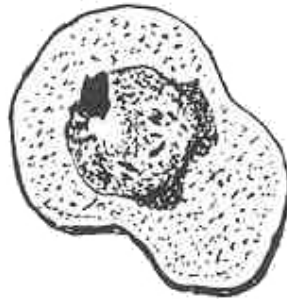
DENSITY: Somewhat amoeboid.

SIZE: 8 to 10 μ ; more condensed than growing trophozoite.

VACUOLES: Usually one.

HEMOZOIN PIGMENT: Diffused; light, golden brown rods.

INFECTED ERYTHROCYTE: Enlarged; pale; even-size Schuffner's granules numerous.



P. ovale

CHROMATIN MASS: Medium to large.

CYTOPLASM

COLOR: Darker blue.

DENSITY: Compact.

SIZE: 5 to 7 μ .

VACUOLE: Singular.

HEMOZOIN PIGMENT: Gold; somewhat diffused.

INFECTED ERYTHROCYTE: Slightly enlarged; pale; coarse and uneven Schuffner's granules; may be oval and/or fimbriate.

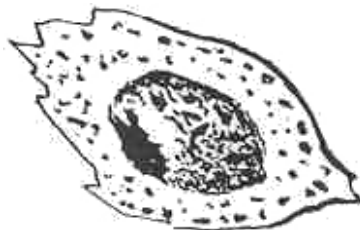


Figure 2-29. Stages of Plasmodia--mature trophozoite (continued).

P. malariae

CHROMATIN MASS--Medium to large.

CYTOPLASM

COLOR--Darker blue.


DENSITY--Compact.

SIZE: 4 to 7 μ .

VACUOLE: Singular; may have multiple.

HEMOZOIN PIGMENT--Dark green; coarse; usually on the edge of the parasite; abundant.

INFECTED ERYTHROCYTE: Normal appearance (often slightly microcytic).



P. falciparum

Normally not found in the peripheral circulatory system except in high parasitemia.

CHROMATIN MASS: Small.

CYTOPLASM:

COLOR: Blue.

DENSITY: Slightly compact.

SIZE: 2 to 4 μ .

VACUOLE: Singular.

HEMOZOIN PIGMENT: Black; one or two clumps.

INFECTED ERYTHROCYTE: Normal appearance.




Figure 2-29. Stages of Plasmodia--mature trophozoite (concluded).

NOTE: See figures 1-4, 2-4, 3-4 and 4-4 in Appendix C for additional illustrations.

Plasmodium species

MATURE SCHIZONT

P. vivax


SIZE OF MEROZOITES: Medium.

NUMBER OF MEROZOITES: 12 to 24 μ in random order.

SHAPE: Attempts to fill the RBC.

HEMOZOIN PIGMENT: Gold; central cluster of rods.

INFECTED ERYTHROCYTE: Enlarged; pale; Schuffner's granules.



P. ovale

SIZE OF MEROZOITES: Medium-large.

NUMBER OF MEROZOITES: 4 to 16 μ in random order.

SHAPE: Fills one-half of the RBC.

HEMOZOIN PIGMENT: Gold; central cluster.

INFECTED ERYTHROCYTE: Enlarged; pale; Schuffner's granules.

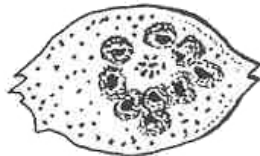


Figure 2-30. Stages of Plasmodia--mature schizon (continued).

P. malariae

SIZE OF MEROZOITES: Medium-large.

NUMBER OF MEROZOITES: 6 to 12 μ , usually in rosette arrangement.

SHAPE: Fills the RBC.

HEMOZOIN PIGMENT: Dark green; central cluster of granules.

INFECTED ERYTHROCYTE: Normal.



P. falciparum

Rarely seen, poor prognosis.

SIZE OF MEROZOITES: Very small.

NUMBER OF MEROZOITES: 8 to 32 μ in random order.

SHAPE: Fills about 1/2 of the RBC.

HEMOZOIN PIGMENT: Black; peripheral clump.

INFECTED ERYTHROCYTE: Normal.

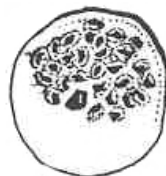

Figure 2-30. Stages of Plasmodia--mature schizon (concluded).

NOTE: See figures 1-6, 2-6, 3-6 in Appendix C for additional illustrations.

Plasmodium species

GAMETOCYTES

DIFFERENTIATION: No vacuoles present.

MACROGAMETOCYTE: Dark blue and compact cytoplasm; peripheral and compact chromatin.

MICROGAMETOCYTE: Light blue and diffused cytoplasm; thready chromatin.

P. vivax

SHAPE: Oval.

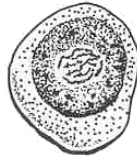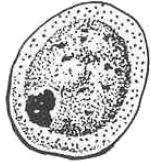CYTOPLASM: Pale blue.

CHROMATIN MASS: Medium to large.

SIZE: Fills the entire RBC.

HEMOZOIN PIGMENT: Gold; abundant; scattered.

INFECTED ERYTHROCYTE: Enlarged; pale; Schuffner's granules.



P. ovale

SHAPE: Oval.

CYTOPLASM: Dark blue.

CHROMATIN MASS: Medium-large.

SIZE: Almost fills the RBC.

HEMOZOIN PIGMENT: Gold-brown; abundant; scattered.

INFECTED ERYTHROCYTE: Enlarged; pale; Schuffner's granules.

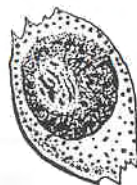
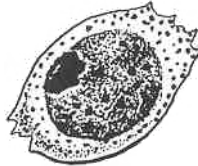


Figure 2-31. Stages of Plasmodia--gametocytes (continued).

P. malarie

SHAPE: Oval.

CYTOPLASM: Dark blue.

CHROMATIN MASS: Medium-large.

SIZE: Fills three-fourths of the RBC.

HEMOZOIN PIGMENT: Dark green; abundant; scattered.

INFECTED ERYTHROCYTE: Normal appearance.



P. falciparum

SHAPE: Crescent; banana.

CYTOPLASM: Light blue.

CHROMATIN MASS: Central; fragmented.

SIZE: Longer than the RBC's diameter.

HEMOZOIN PIGMENT: Red-black; clustered about the chromatin.

INFECTED ERYTHROCYTE: Stretched; ghost cell.

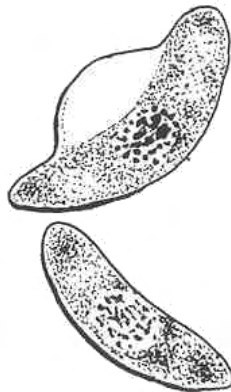


Figure 2-31. Stages of Plasmodia--gametocytes (concluded).

NOTE: See figures 1-7, 1-8, 2-7, 2-8, 3-7, 4-6 and 4-7 in Appendix C for additional illustrations.

2-12. THICK DROP PREPARATION

See figure 2-32 for information on thick drop preparation. See figure 2-33 for an example of parasite morphology on thick smear.

THICK DROP PREPARATION
SPECIATION: Most difficult to accomplish except with the gametocyte of <u>P. falciparum</u> ,
CYTOPLASM: Scattered or fractured; blue.
CHROMATIN MASS: Red to deep magenta.
HEMOZOIN PIGMENT: Clumped.
ERYTHROCYTES: Lysed; may be seen outlined by the granules.
PROPER DENSITY OF SMEAR: 10 to 30 WBC's per oil immersion field.
FIBRIN: Only a few bluish strands are acceptable.
PROBLEMS: Confusion with other structures such as: platelets, WBCs, bacteria, cellular debris, stain crystals, and other artifacts.
PRECIPITATE: Proper rinsing and procedure should eliminate background elements.

Figure 2-32. Thick drop preparation.

Plasmodium species

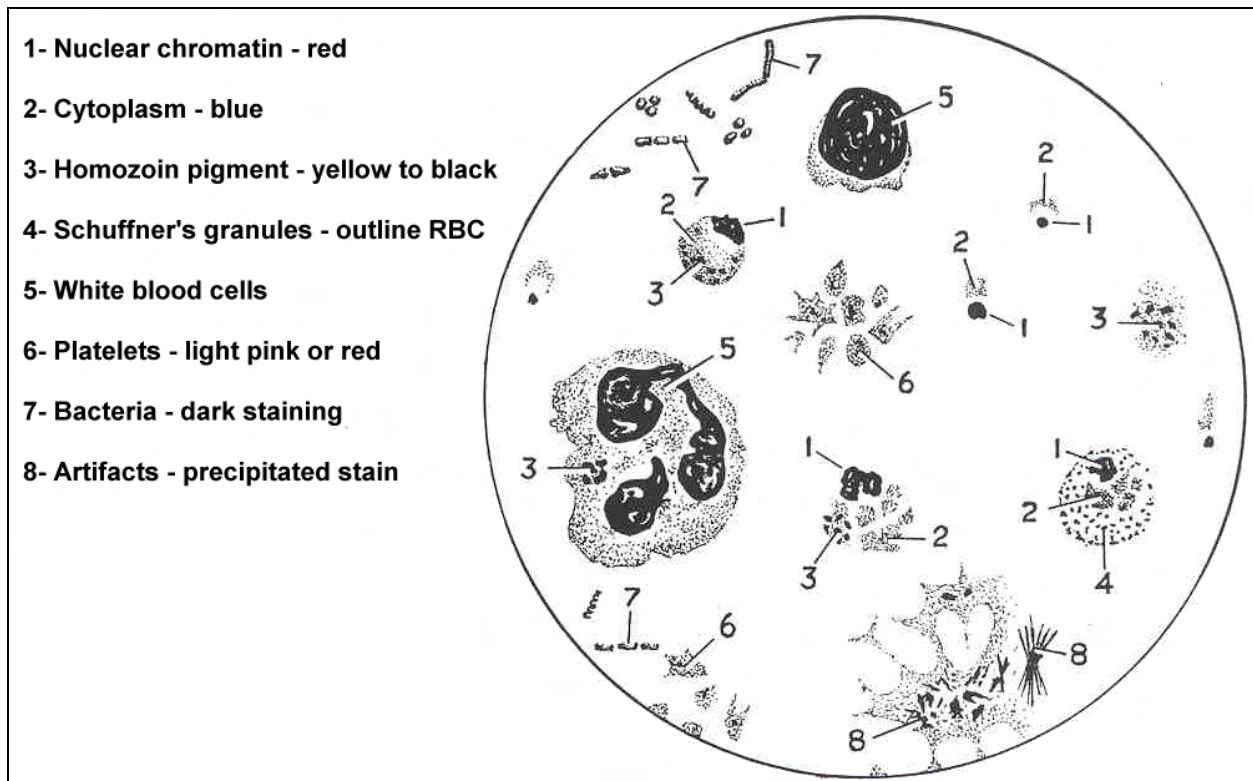


Figure 2-33. Parasite morphology on thick smear.

[Continue with Exercises](#)

EXERCISES, LESSON 2

INSTRUCTIONS: Answer the following exercises by marking the lettered response that best answers the exercise, by completing the incomplete statement, or by writing the answer in the space provided at the end of the exercise.

After you have completed all the exercises, turn to "Solutions to Exercises" at the end of the lesson and check your answers. For each exercise answered incorrectly, reread the material referenced with the solution.

1. Motility of Sporozoans is accomplished by:
 - a. Gliding.
 - b. Undulation of longitudinal ridges.
 - c. Body flexion.
 - d. All of the above.

2. The size of mature oocysts of Cryptosporidium is:
 - a. 2 to 4 μ .
 - b. 6 to 10 μ .
 - c. 12 to 15 μ .
 - d. 12 to 30 μ .

3. A Sporozoan organism that frequently causes birth defects in humans is:
 - a. Sarcocystis hominis.
 - b. Cryptosporidium.
 - c. Toxoplasma gondii.
 - d. Pneumocystis carinii.

4. The human infective form of all Plasmodium species is the:
 - a. Macrogametocyte.
 - b. Microgametocyte.
 - c. Sporozoite.
 - d. Trophozoite.

5. The two Plasmodium species which account for most (96%) infections are:
 - a. Plasmodium vivax and Plasmodium malariae.
 - b. Plasmodium falciparum and Plasmodium vivax.
 - c. Plasmodium malariae and Plasmodium ovale.
 - d. Plasmodium falciparum and Plasmodium malariae.

6. Members of the Class Ciliata use small hair-like structures for movement and for:
 - a. Controlling hydrostasis.
 - b. Food procurement.
 - c. Protection.
 - d. Diffusion.

7. If a Plasmodium trophozoite occupies most of an enlarged infected erythrocyte it is:
 - a. Plasmodium vivax.
 - b. Plasmodium malariae.
 - c. Plasmodium ovale.
 - d. Plasmodium falciparum.

8. Hemozoin pigment in the schizont form of Plasmodium malariae is:
- Gold.
 - Black.
 - Green.
 - Brown.
9. The reservoir host of Balantidium coli is the:
- Rabbit.
 - Hog.
 - Sheep.
 - Monkey.
10. Crescent shape gametocytes are typical of:
- Plasmodium vivax.
 - Plasmodium malariae.
 - Plasmodium falciparum.
 - Plasmodium ovale.
11. A well prepared thick drop smear for Plasmodium will have _____ WBC's per oil immersion field.
- 5-10.
 - 10-30.
 - 30-40.
 - 20-50.

12. Organisms belonging to the Genus Babesia can best be described as small, multiciliate, and ameboid in shape.
- True.
 - False.
13. Redwater fever is transmitted to man by:
- Ingestion of contaminated water.
 - Transfusion of infected blood.
 - Injection by hard ticks.
 - Injection by Anopheles mosquitoes.
14. The organisms of Eimeria species, if present in the host, are recovered from which of the following sources?
- Pleural effusions.
 - Fecal specimens.
 - Sputum.
 - Cerebral spinal fluid.
15. The specimen of choice for the recovery of malarial parasites is:
- Tissue impression smears.
 - Venous blood.
 - Oxalated blood.
 - Capillary blood.

16. In the life cycle of malarial parasites, the definitive host is:
- Primates.
 - Female Anopheles mosquitoes.
 - Human beings.
 - Domestic animals.
17. Respiration among the ciliates is accomplished by diffusion through the cell membrane
- True.
 - False.
18. Infections of Isospora belli are initiated:
- Following the bite of the tick vector.
 - When the oocyst is ingested by the host.
 - Following the ingestion of mature cysts.
 - When hosts are bitten by infected sand flies.
19. Which of the following characteristics help to identify the trophozoite of Sarcocystis hominis?
- A limiting membrane with radial striations.
 - Elongated and cylindrical shape.
 - Internal septae and compartments.
 - All of the above.

20. A spherical mature cyst with 8 nuclei arranged in a "rosette" pattern relates to which of the following organisms?
- a. Pneumocystis carinii.
 - b. Toxoplasma gondii.
 - c. Cryptosporidium species.
 - d. Sarcocystic hominis.
21. Both asexual and sexual reproductive cycles are known to occur among members of the class Sporozo.
- a. True.
 - b. False.
22. The term used to describe the asexual cycle of members of the family Plasmodiidae is:
- a. Gametogony.
 - b. Sporogony.
 - c. Schizogony.
 - d. None of the above.

Check Your Answers on Next Page

SOLUTIONS TO EXERCISES, LESSON 2

1. d (para 2-7)
2. a (para 2-11, org 3)
3. c (para 2-11, org 4)
4. c (para 2-11, org 7)
5. b (para 2-11, org 7)
6. b (para 2-1)
7. a (para 2-11, figure 2-20)
8. c (para 2-11, figure 2-22)
9. b (para 2-3), org 1)
10. c (para 2-11, figure 2-23)
11. b (figure 2-24
12. b (para 2-4)
13. c (para 2-6), org 1)
14. a (para 2-11, org 2)
15. d (para 2-11, org 7)
16. b (para 2-11, org 7)
17. a (para 2-2)
18. b (para 2-11, org 1)
19. d (para 2-11, org 5)
20. a (para 2-11, org 6)
21. a (para 2-7)
22. c (para 2-10)

End of Lesson 2

LESSON ASSIGNMENT

LESSON 3

Phylum Platyhelminths.

LESSON ASSIGNMENT

Paragraphs 3-1 through 3-10.

LESSON OBJECTIVES

After completing this lesson, you should be able to:

- 3-1. Identify the general characteristics of members of Phylum Platyhelminthes.
- 3-2. Identify the organism characteristics of parasitic members of Class Trematoda.
- 3-3. Select a statement that best describes the life cycle of a member of Class Trematoda.
- 3-4. Identify the organism characteristics of parasitic members of Class Cestoda.
- 3-5. Select a statement that best describes the life cycle of a member of Class Cestoda.
- 3-6. Identify the specimen of choice for recovery of specific Platyhelminthes.
- 3-7. Identify the special technique required for recovery of specific Platyhelminthes.

SUGGESTION

After completing the assignment, complete the exercises of this lesson. These exercises will help you to achieve the lesson objectives.

LESSON 3

PHYLUM PLATYHELMINTHS

Section I. OVERVIEW OF PLATYHELMINTHES

3-1. GENERAL COMMENTS

The organisms that belong to this phylum show a dorsoventral flattening that gives them the common name of flat worms. The internal structures are organized in a bilateral symmetry. The body may consist of only one part (monozoic) or of two or more parts (polyzoic). Because flat worms are adapted to parasitism, the necessity for certain functions is no longer needed. Therefore, the organs involved in those functions were eliminated. On the other hand, with the new demands of parasitism, some of the organs have adapted to enhance their capabilities.

3-2. STRUCTURE

Skeletal, circulatory, and respiratory structures are lacking within these organisms. They have no body cavity (acoelomates) and the internal organs are embedded in a cellular matrix called the parenchyma. The digestive tract may be either incomplete or totally absent. The nervous system varies from a very primitive network found in the free living forms to a well developed arrangement present in the parasitic forms composed of a pair of anterior ganglia each having a longitudinal nerve cord. The excretory system varies with each species. There may be flame cells, long ducts with exterior exit, or bladders with excretory pores.

3-3. REPRODUCTION

With a few exceptions (e.g. schistosomes), the phylum is characterized by a monoecious arrangement of the reproductive systems, in which both male and female reproductive organs are present within a single individual worm. Fertilization is internal and the exchange of spermatozoa between individuals or between two segments is the preferred method of fertilization.

3-4. CLASSES

There are three classes in the phylum. The class Turbellaria consists of free living organisms (e.g., genus Planaria), while the classes Trematoda and Cestoda contain all parasitic species.

Section II. CLASS TREMATODA

3-5. GENERAL COMMENTS

Flukes which parasitize humans have been found in most of the systems and organs of the body. Flukes use more than one host, alternating asexual generations in one or more hosts (intermediate hosts) with the sexual generation in another host (definitive host). The flukes are monozoic (one body part), leaf-shaped organisms that have two heavily muscled suckers. The oral sucker is used as a mouth while the ventral sucker, acetabulum, is used as an organ of attachment to the host. The digestive system is incomplete with internal and external digestion. The nervous system is well developed. Some anatomical structures (e.g., the shape and length of the intestinal ceca, the size and location of the acetabulum, hooklets around the oral sucker, and the location, the shape, and number of testes) are used for taxonomical differentiation.

NOTE: See figures 3-1 through 3-9 and table 3-1 for additional information.

3-6. SUBCLASSES

The members of the class Trematoda are commonly known as flukes. The class is divided into three subclasses: Monogenea, Aspidobothria, and Digenea. The subclass Monogenea is characterized by having only one host, and its members are ectoparasites of poikilothermic vertebrates (such as fish, amphibians, and reptiles). Members of the subclass Aspidobothria are characterized by a relatively simple life cycle without asexual generations, and are ectoparasites of fish, turtles, and mollusks. The third subclass, Digenea, is the largest of the three, and encompasses all trematodes which are parasitic to man. Some members of this subclass are parasites of many other animals. The subclass Digenea is further subdivided into two orders: Strigeatoidea which contains the schistosomes, and Prosostomatea which contains the other parasitic flukes.

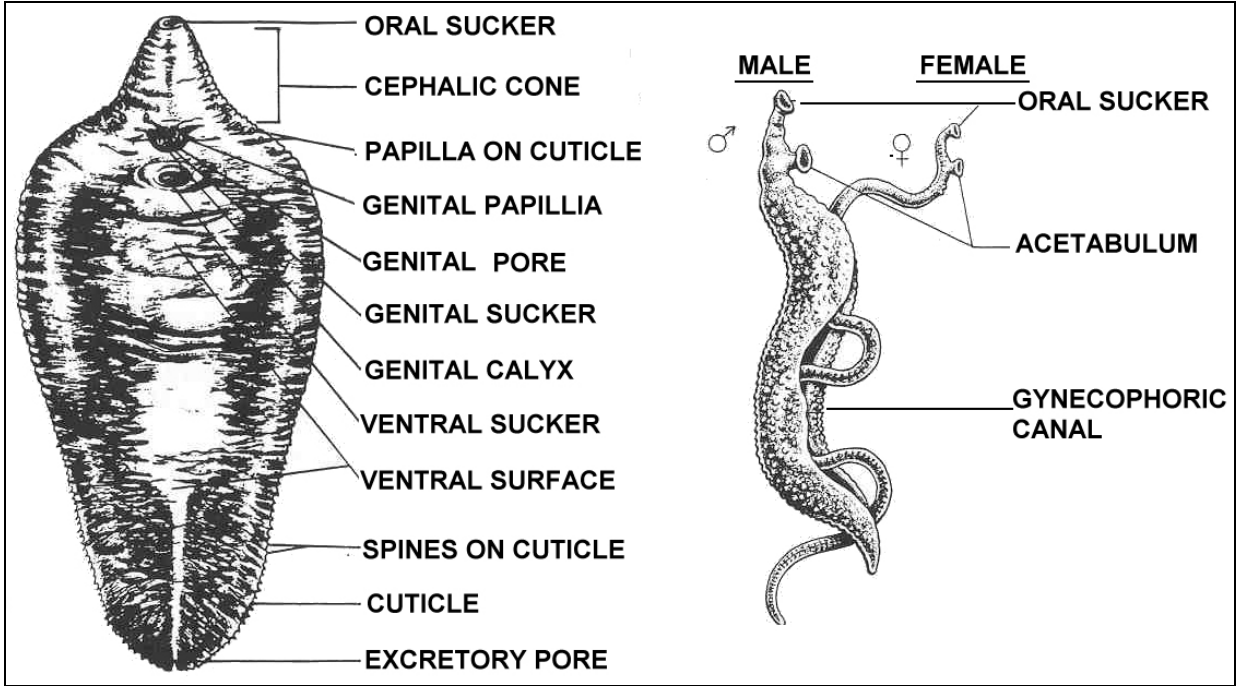


Figure 3-1. External fluke structure.

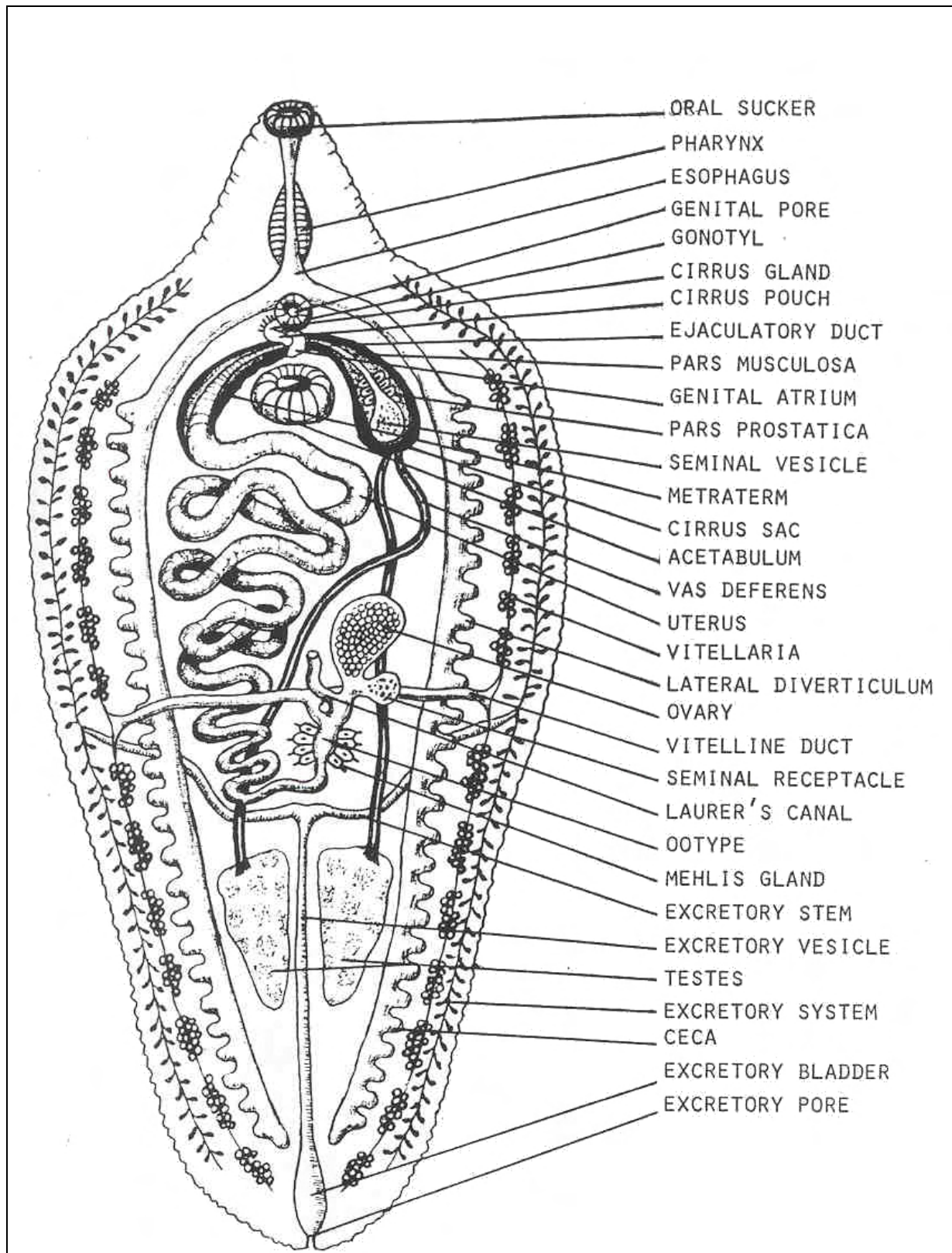


Figure 3-2. Internal fluke structure.

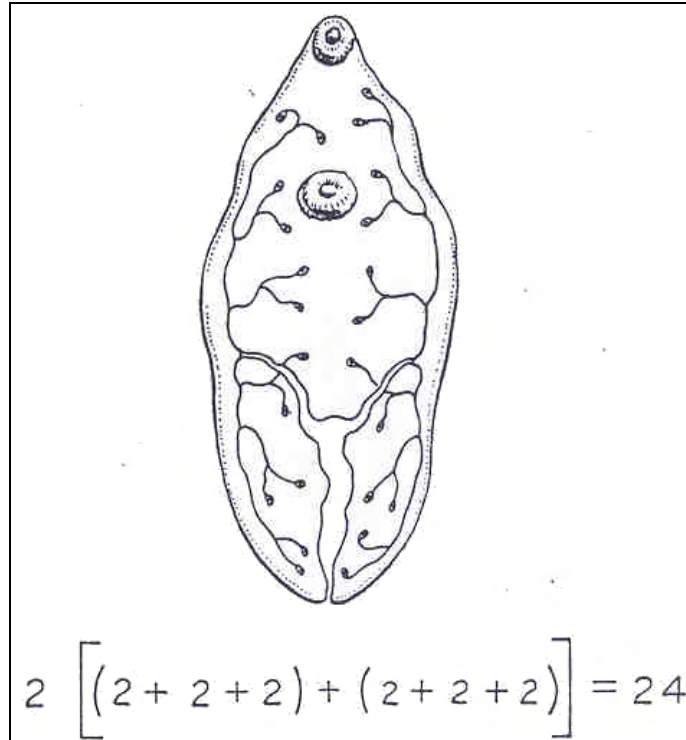


Figure 3-3. Osmoregulatory system of a fluke.

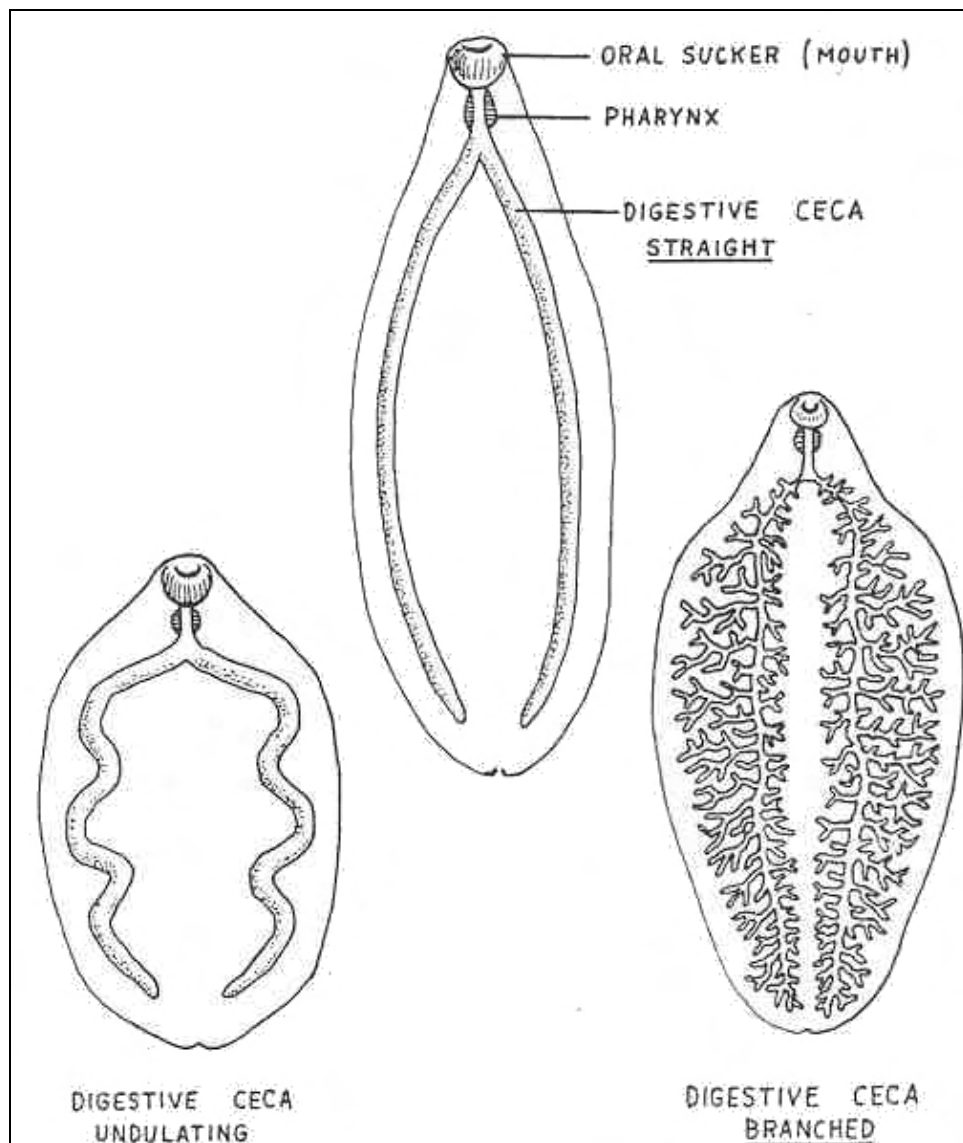


Figure 3-4. Digestive system of a fluke.

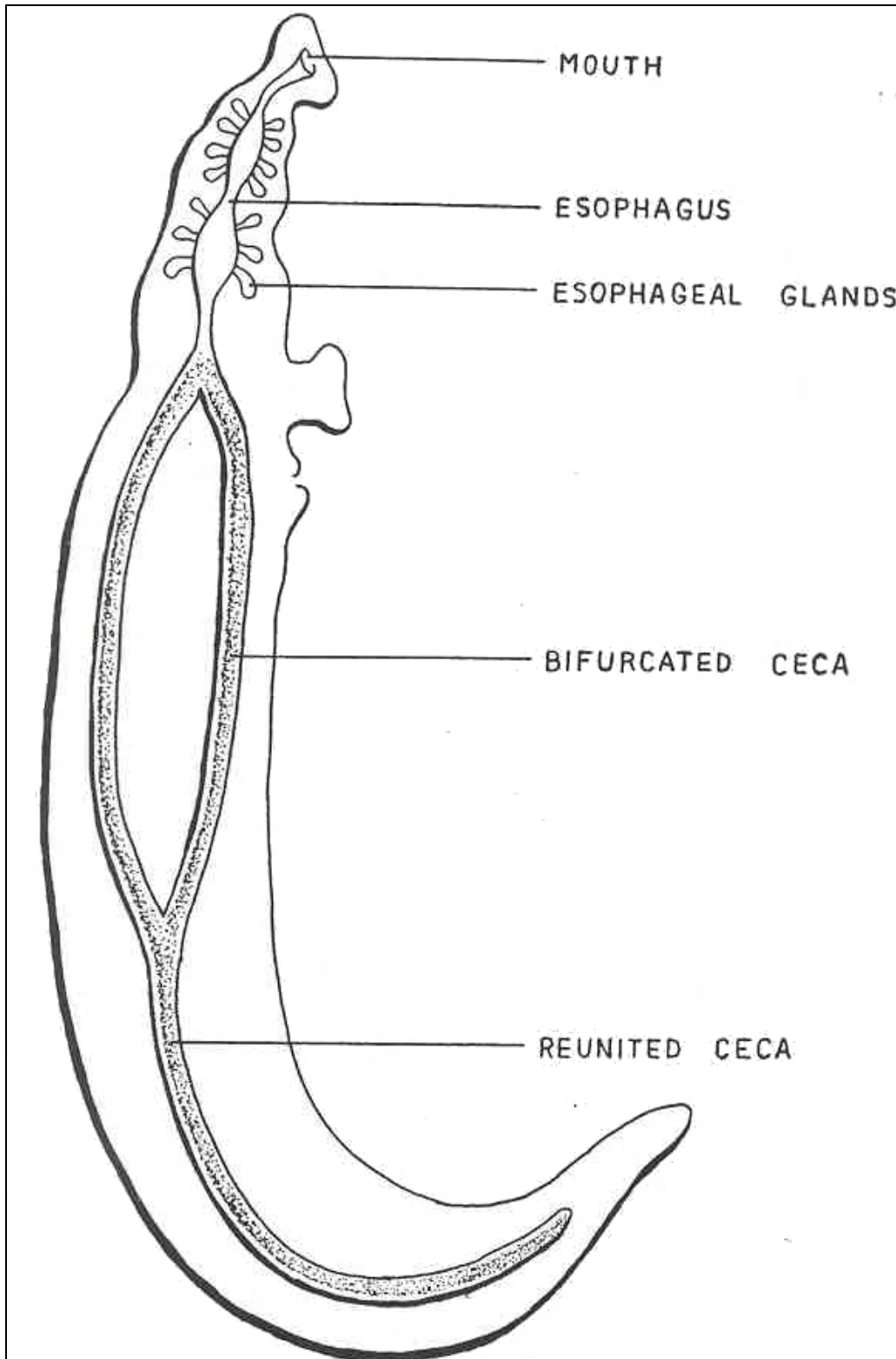


Figure 3-5. Digestive system of a fluke.

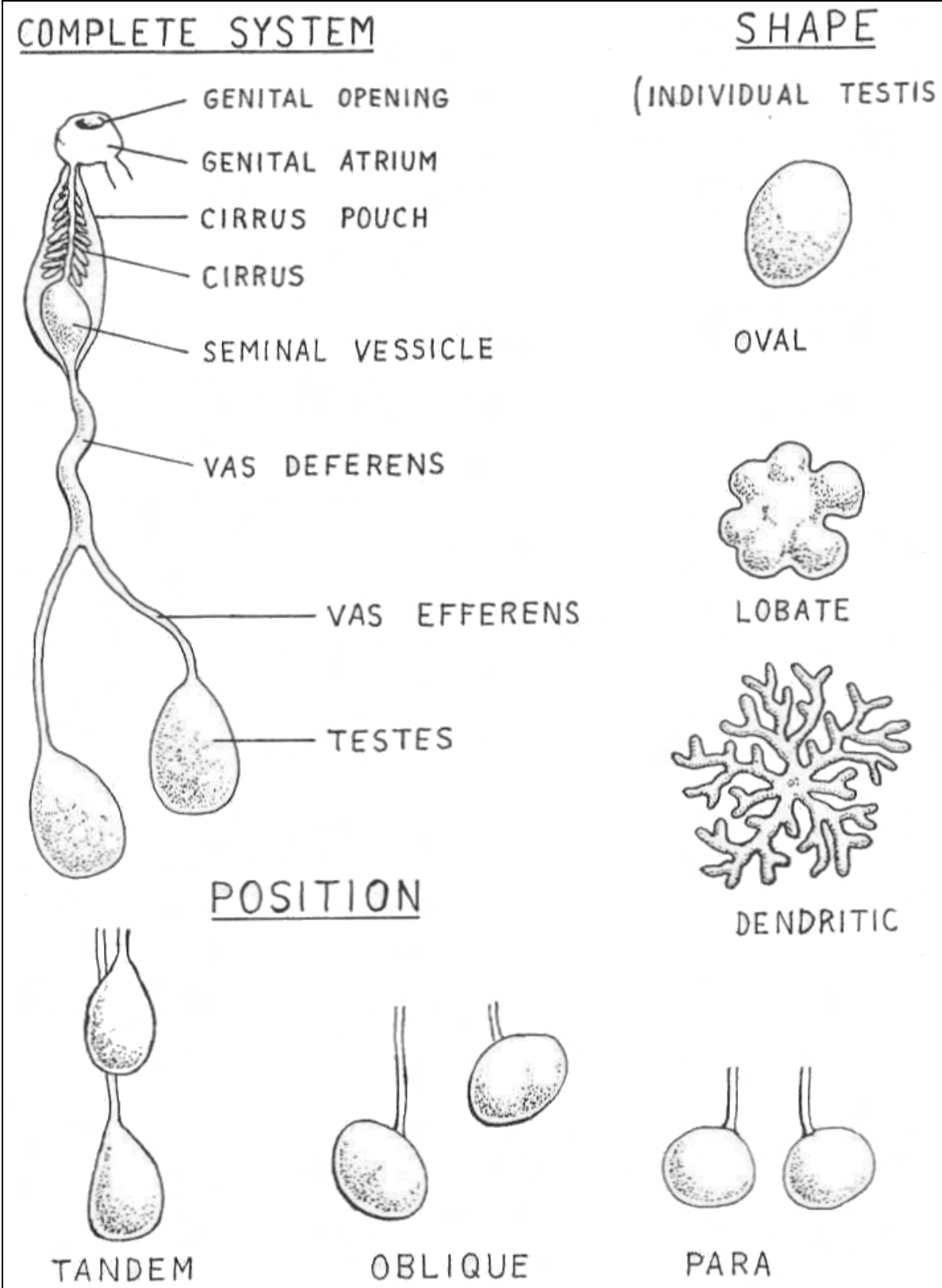


Figure 3-6. Reproductive system of a fluke--male.

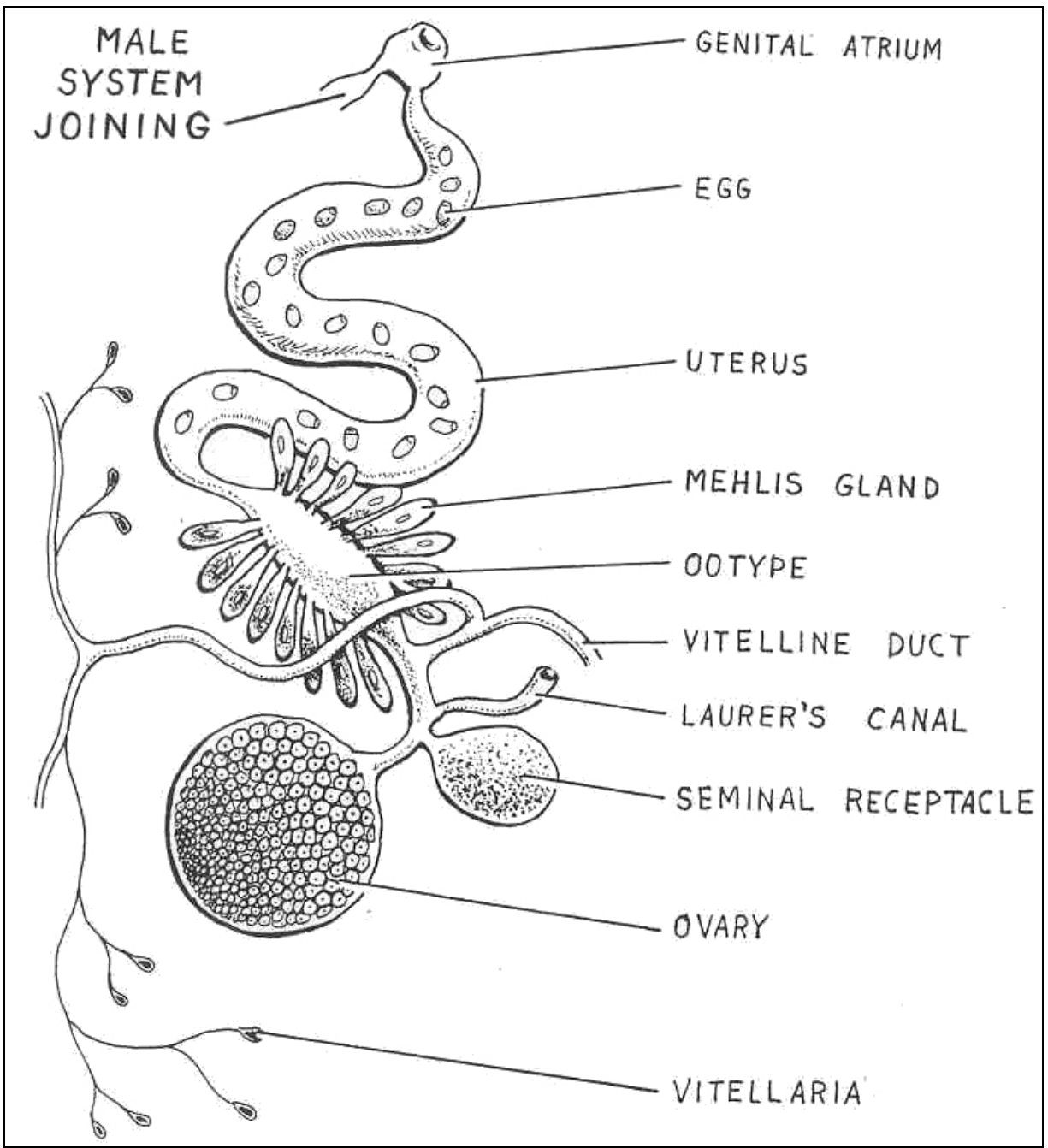


Figure 3-7. Reproductive system of a fluke--female.

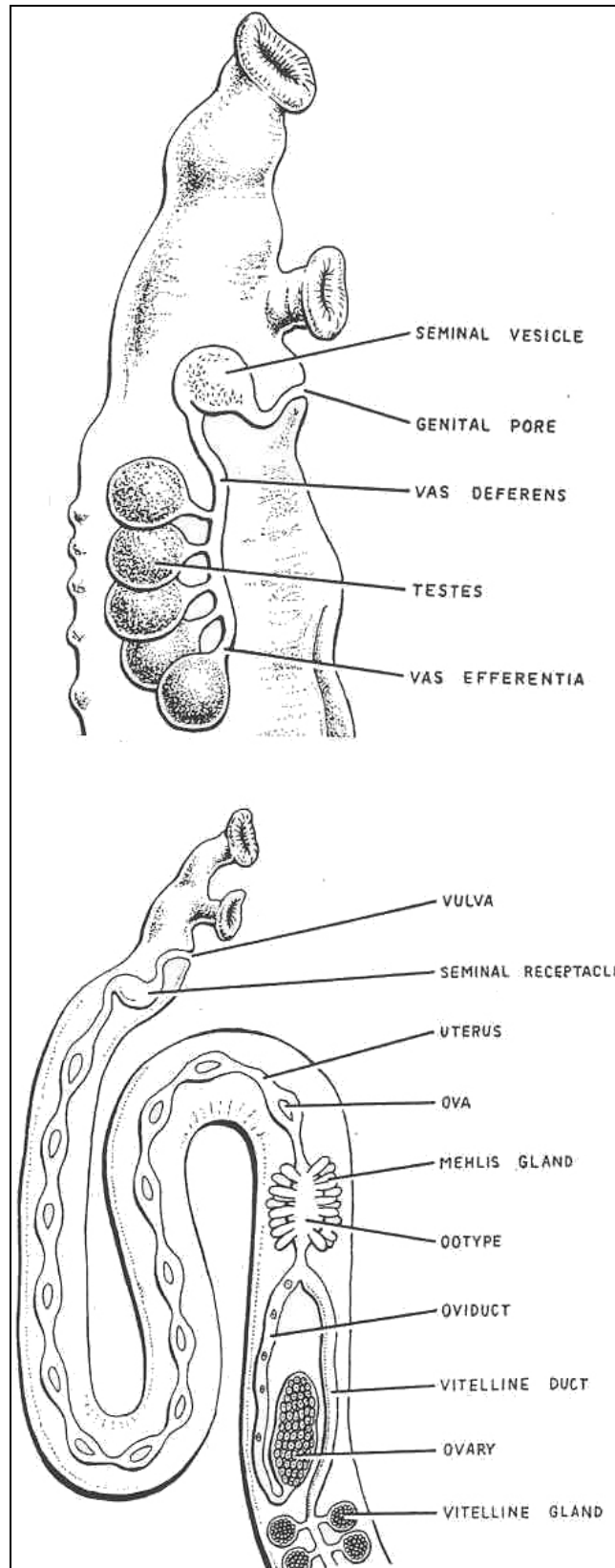


Figure 3-8. Reproductive system of schistosome.

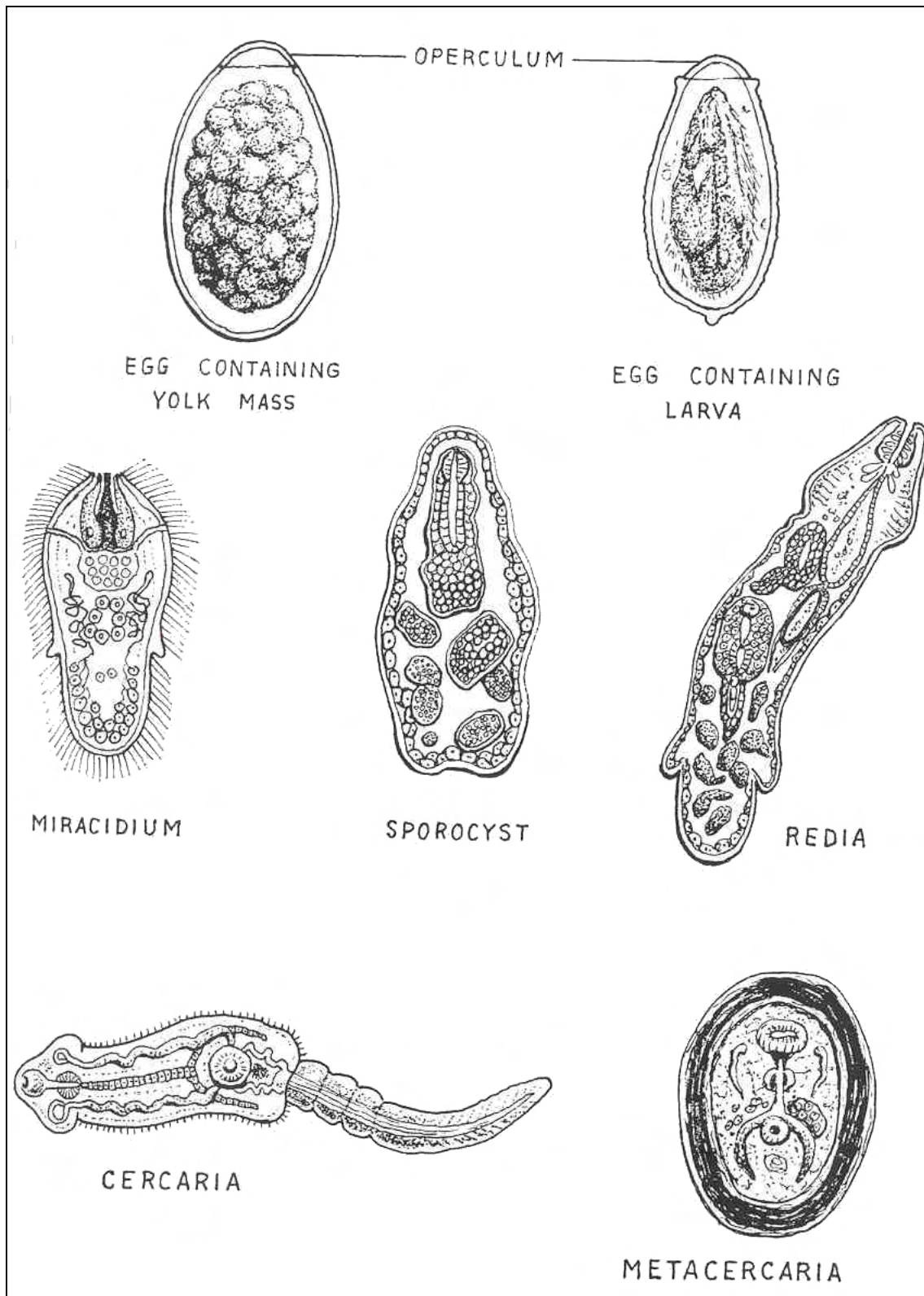


Figure 3-9. Larval stages of flukes.

KEY TO IMPORTANT ADULT HUMAN TREMATODES

1.	Dioecious trematodes (one sex per worm).....	<u>Schistosoma</u> species.	
	Monoecious trematodes (both sexes per worm).....		2
2.	Small flukes: size under 5 mm.....		3
	Large flukes: size range 20 to 45 mm.....		4
	Medium flukes: size range 5 to 20 mm.....		5
3.	Gonotyl absent; ventral sucker offset to one side; intestinal ceca straight; testes oval and oblique.....	<u>Metagonimus yokogawai</u>	
	Gonotyl present; ventral sucker central; intestinal ceca straight; testes oval and para.....	<u>Heterophyes heterophyes</u>	
4.	Cephalic cone present; intestinal ceca branched; testes tandem and dendritic.....	<u>Faciolopsis hepatica</u>	
	Cephalic cone absent; intestinal ceca undulating; testes tandem and dendritic.....	<u>Faciolopsis buski</u>	
5.	Anterior testes.....		6
	Posterior testes.....		7
6.	Intestinal ceca straight; testes oblique and lobate; wide acetabulum at posterior end; gourd-shaped body.....	<u>Gastrodiscoides hominis</u>	
	Intestinal ceca straight; testes oblique and lobate; Elongated.....	<u>Dicrocoelium dendriticum</u>	
7.	Circlet of spines around oral sucker; intestinal ceca straight; testes tandem and lobate.....	<u>Echinostoma</u> species	
	Intestinal ceca straight; testes oblique and lobate.....	<u>Opisthorchis</u> species	
	Intestinal ceca straight; testes tandem and highly branched.....	<u>Opisthorchis sinensis</u>	
	Intestinal ceca undulating; testes para and lobate.....	<u>Paragonimus westermani</u>	

Table 3-1. Key to important adult human trematodes.

3-7. COMMON PARASITES OF CLASS TREMATODA

See figures 3-10 through 3-48. Note that snails are the first intermediate hosts of all trematodes.

ORGANISM 1--Schistosoma japonicum

GENERAL CHARACTERISTICS

COMMON NAME: Oriental blood fluke.

GEOGRAPHICAL DISTRIBUTION: Far East.

PATHOGENESIS: Embolic eggs cause more severe lesions than other schistosome species, infiltration of vital organs; liver fibrosis and cirrhosis, splenomegaly, cellular infiltration, ulceration.

HABITAT: Venules surrounding the small intestine.

INTERMEDIATE HOST

FIRST: Snail (Oncomelaria).

SECOND: None.

RESERVOIR HOST: Mammals.

INFECTIVE FORM: Cercaria.

MODE OF INFECTION: Active penetration.

SPECIMEN OF CHOICE: Feces.

Figure 3-10. Information on Schistosoma japonicum.

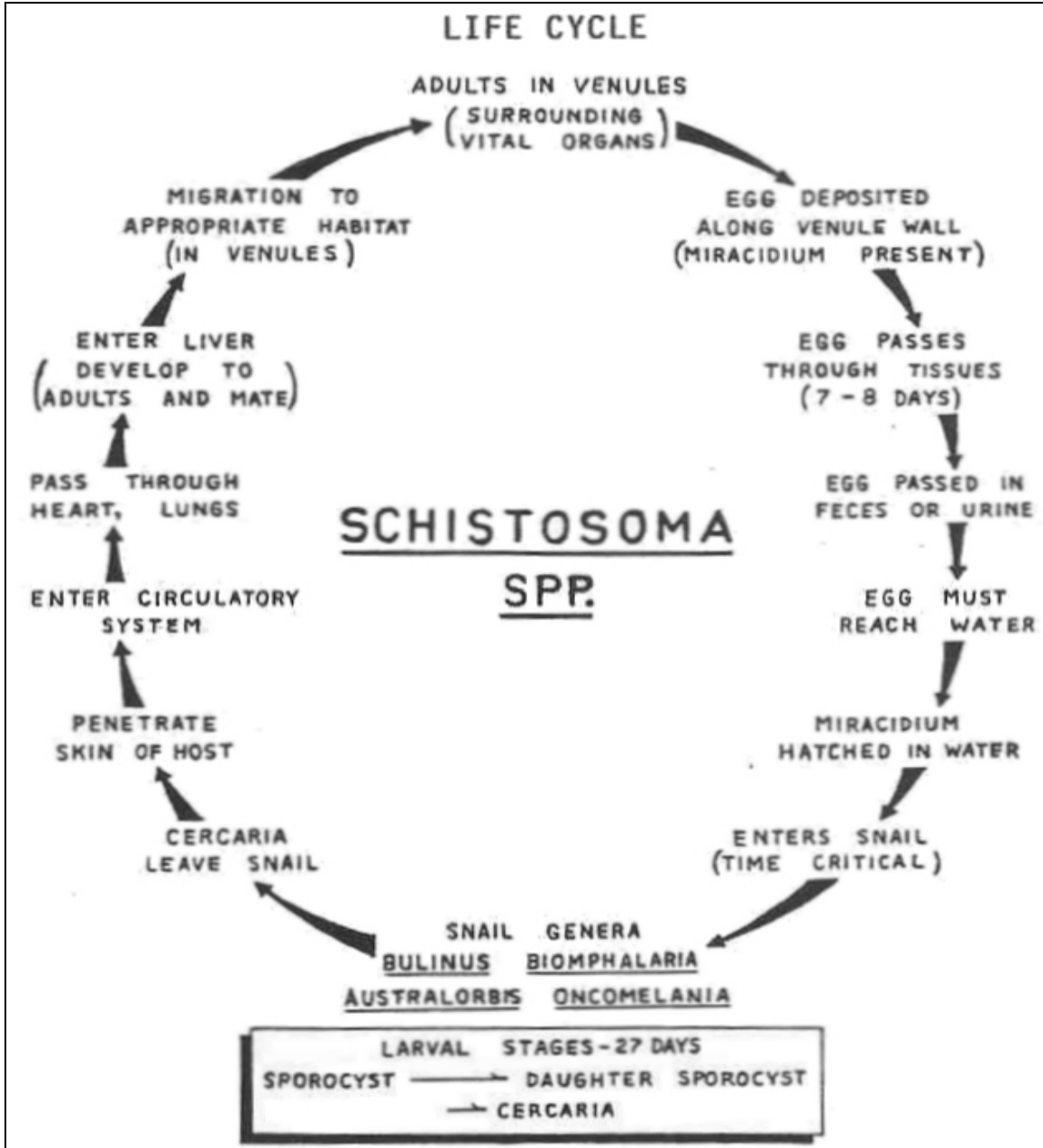


Figure 3-11. Life cycle of Schistosoma japonicum.

Schistosoma japonicum

OVA

SIZE: 90 x 70 μ (medium).

SHAPE: Oval to round.

COLOR: Yellow brown.

OPERCULUM: Absent.

CONTENT: Shouldered miracidium surrounded by vitelline membrane (double linear outline); short lateral spine sometimes curved (inconspicuous). Fecal debris adhering to shell.

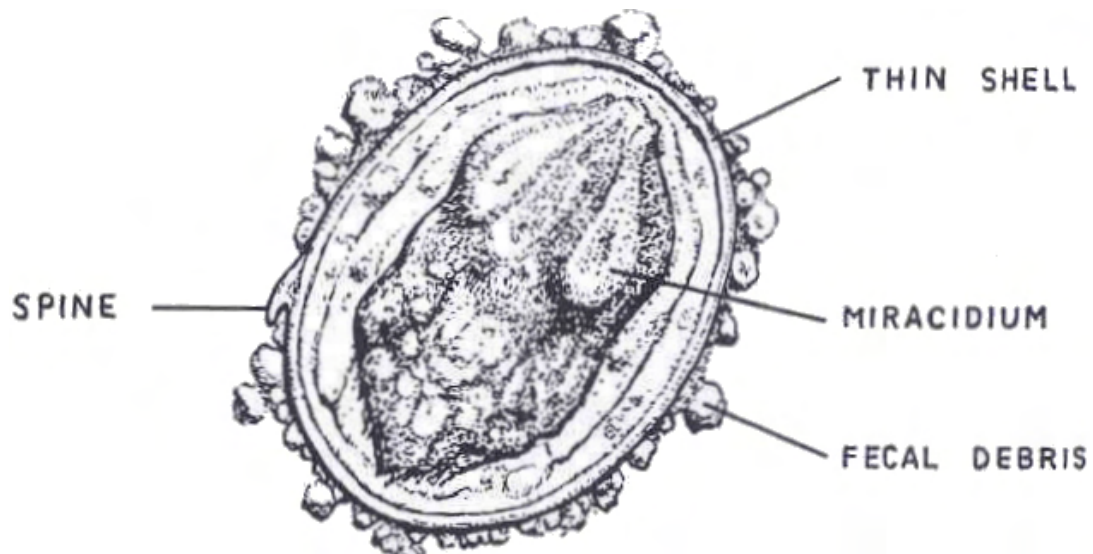


Figure 3-12. Stages of Schistosoma japonicum. (continued)

Schistosoma japonicum

ADULTS

SIZE:

MALE: 1.0 to 2.2 cm long by 0.5 mm wide.

FEMALE: 1.2 to 2.6 cm long by 0.3 mm wide.

SHAPE: Elongated with gynecophoral canal in males.

COLOR: Greyish white.

INTESTINAL CECA: Join very late (posterior third of body).

TESTES: Anterior (6 to 8)

OVARIES: Middle of body

UTERUS: Long with 50 to 100 ova.

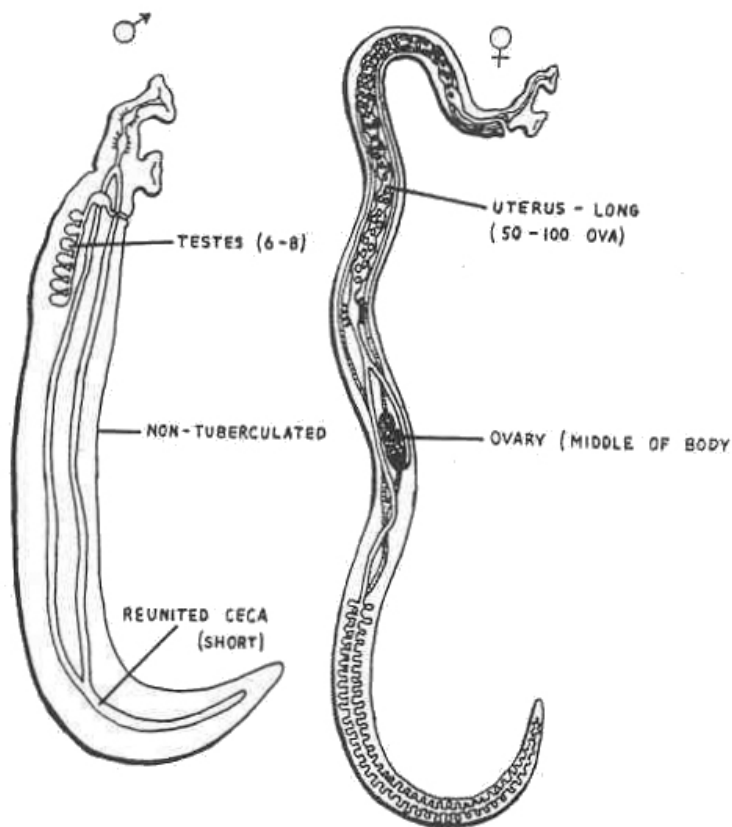


Figure 3-12. Stages of Schistosoma japonicum. (concluded)

ORGANISM 2--Schistosoma mansoni

GENERAL CHARACTERISTICS

COMMON NAME: Manson's blood fluke.

GEOGRAPHICAL DISTRIBUTION: Central and North Africa; Equatorial regions of South America; West Indies and Puerto Rico.

PATHOGENESIS: Infiltration of vital organs; hemorrhages, anemia, hepatosplenomegaly, liver cirrhosis, fibrous tissue proliferation, ulcerations.

HABITAT: Venules surrounding the large intestine.

INTERMEDIATE HOST

FIRST: Snail (*Biomphalaria*, *Australorbis*).

SECOND: None.

RESERVOIR HOST: Rarely monkeys.

INFECTIVE FORM: Cercaria.

MODE OF INFECTION: Active penetration.

SPECIMEN OF CHOICE: Feces.

Figure 3-13. Information on Schistosoma mansoni.

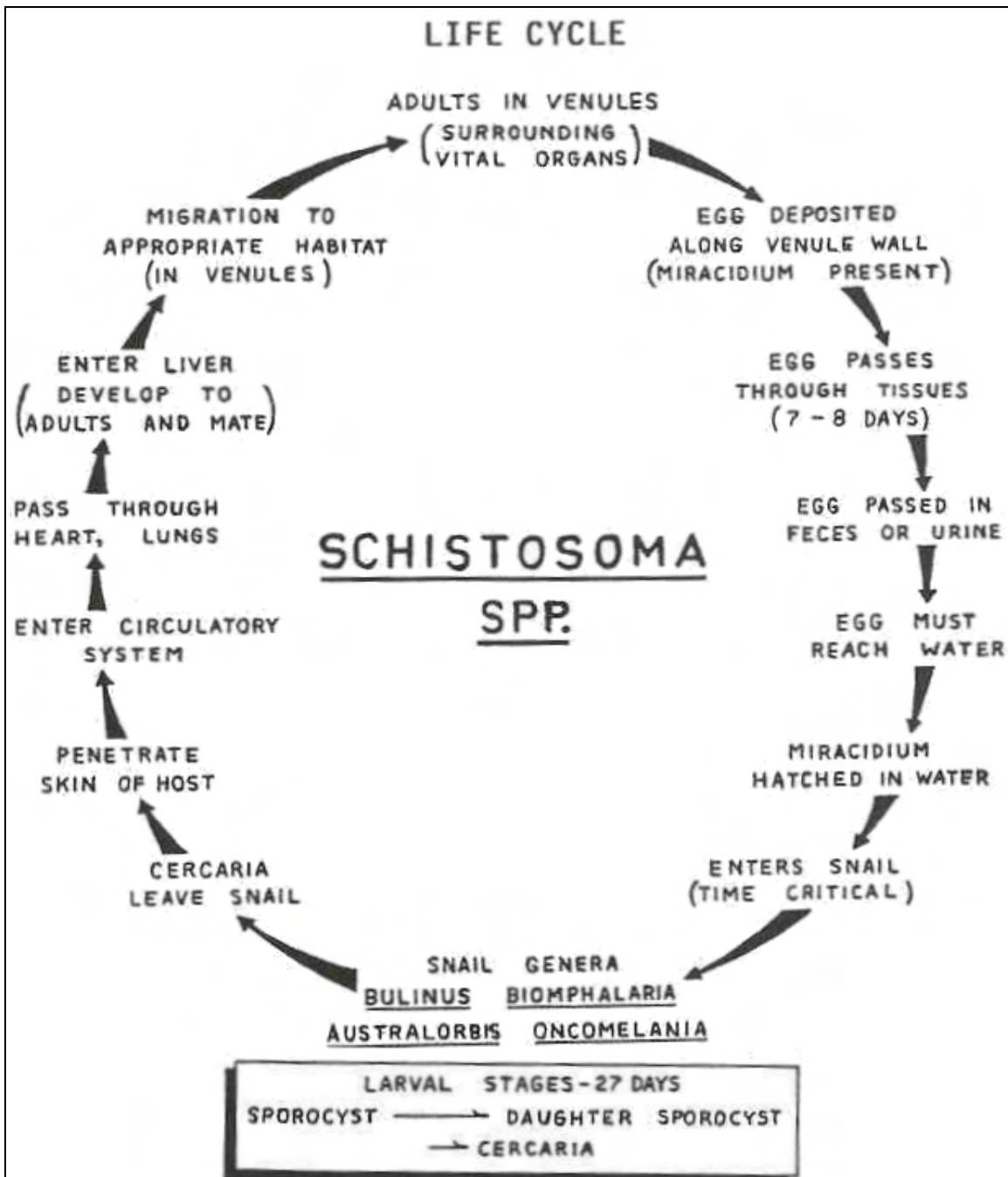


Figure 3-14. Life cycle of Schistosoma mansoni.

Schistosoma mansoni

OVA

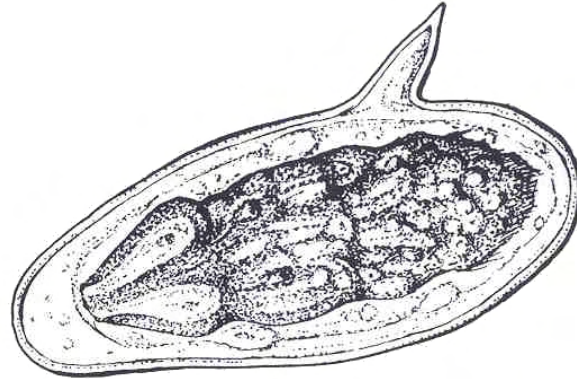
SIZE: 155 x 65 μ (large).

SHAPE: Elongated.

COLOR: Yellow brown.

OPERCULUM: Absent.

CONTENT: Shouldered miracidium surrounded by vitelline membrane (double linear outline). Large lateral spine.



ADULTS

SIZE

MALE: 0.6 to 1.4 cm long by 1.1 mm wide.

FEMALE: 1.2 to 1.6 cm long by 0.2 mm wide.

SHAPE: Elongated with gynecophoral canal in males.

COLOR: White to cream.

INTESTINAL CECA: Join early (in anterior portion of body).

TESTES: Anterior (3 to 13).

OVARY: In anterior half of body.

UTERUS: Short with 1 to 5 ova.

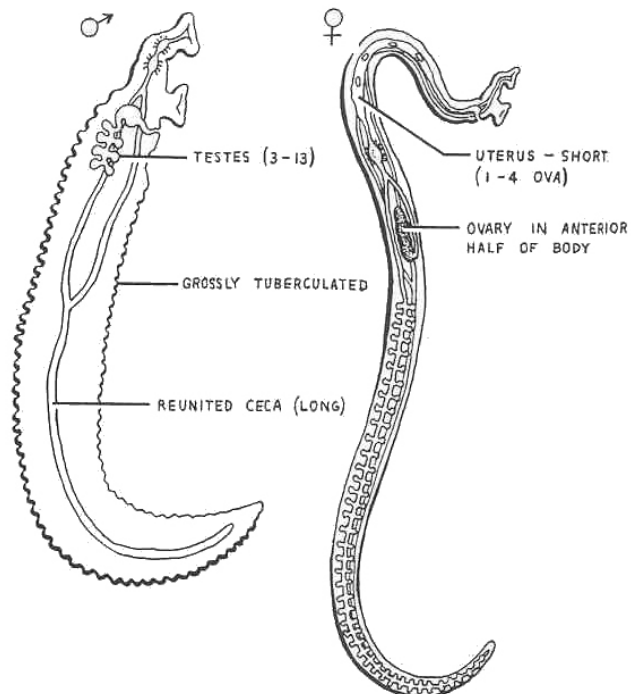


Figure 3-15. Stages of Schistosoma mansoni.

ORGANISM 3--Schistosoma haematobium

GENERAL CHARACTERISTICS

COMMON NAME: Vesical blood fluke.

GEOGRAPHICAL DISTRIBUTION: Africa; Asia Minor; Mediterranean regions.

PATHOGENESIS: Toxic irritations, lesions of urinary bladder and genitalia, cystitis, occlusions of ureters and urethra, hematuria, eosinophilia.

HABITAT: Venules surrounding the urinary bladder.

INTERMEDIATE HOST

FIRST: Snail (Bulinus, Biomphalaria).

SECOND: None.

RESERVOIR HOST: None.

INFECTIVE FORM: Cercaria.

MODE OF INFECTION: Active penetration.

SPECIMEN OF CHOICE: Urine (also feces).

Figure 3-16. Information on Schistosoma haematobium.

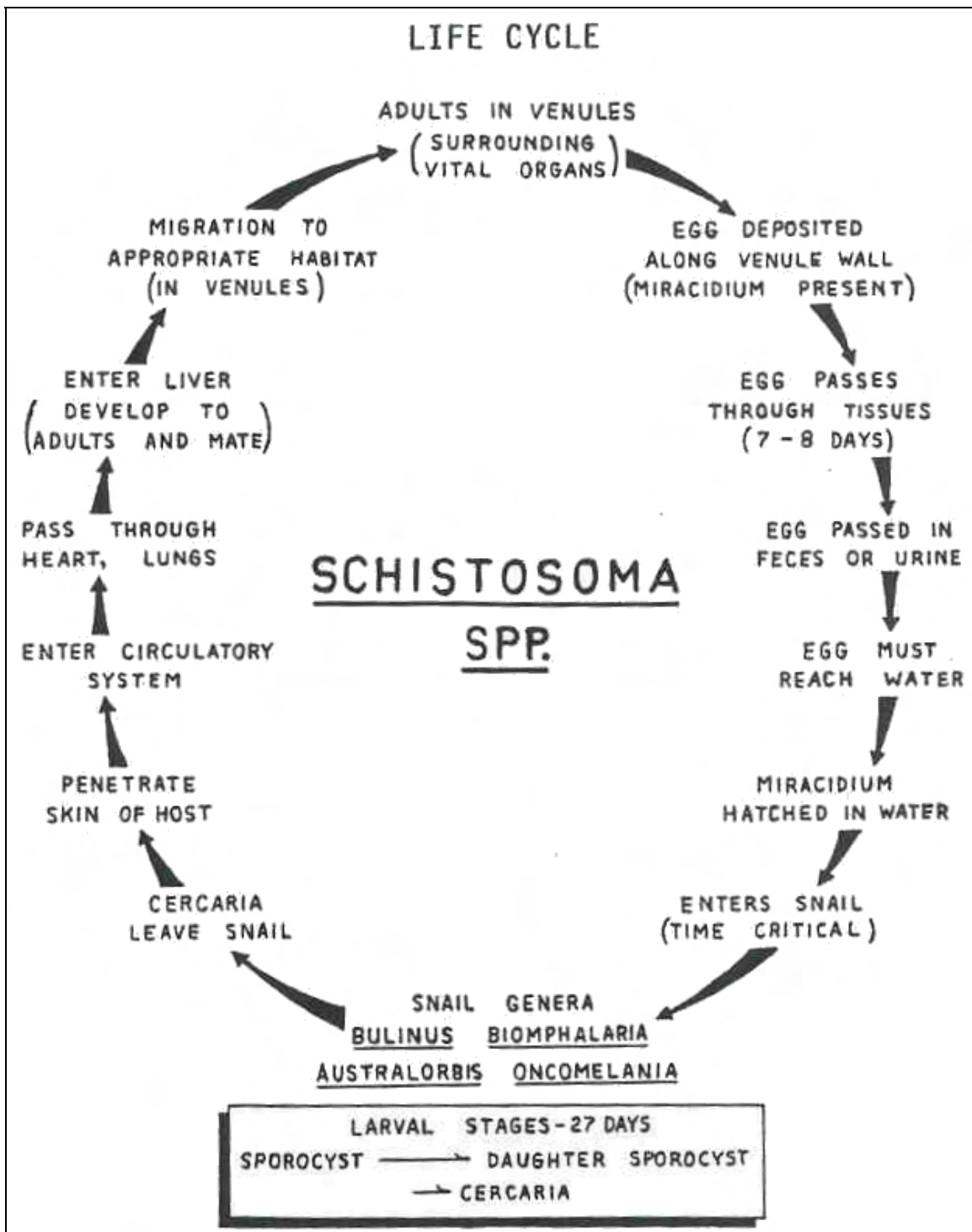


Figure 3-17. Life cycle of Schistosoma haematobium.

Schistosoma haematobium

OVA

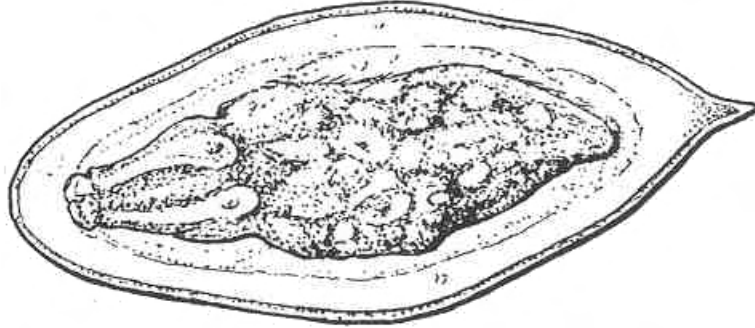
SIZE: 145 x 60 μ (large).

SHAPE: Elongated.

COLOR: Hyaline to light yellow.

OPERCULUM: Absent

CONTENT: Shouldered miracidium surrounded by vitelline membrane (double linear line). Terminal spine.



ADULTS

SIZE

MALE: 1.0 to 1.5 cm long x 0.9 mm wide.

FEMALE: 2.0 to 2.5 cm long by 0.25 mm wide.

SHAPE: Elongated with gynecophoral canal in males.

COLOR: Greyish white

INTESTINAL CECA: Join late (near middle of body).

TESTES: Anterior (4 to 5)

OVARIES: In posterior half of body.

UTERUS: Long with 20 to 30 ova.

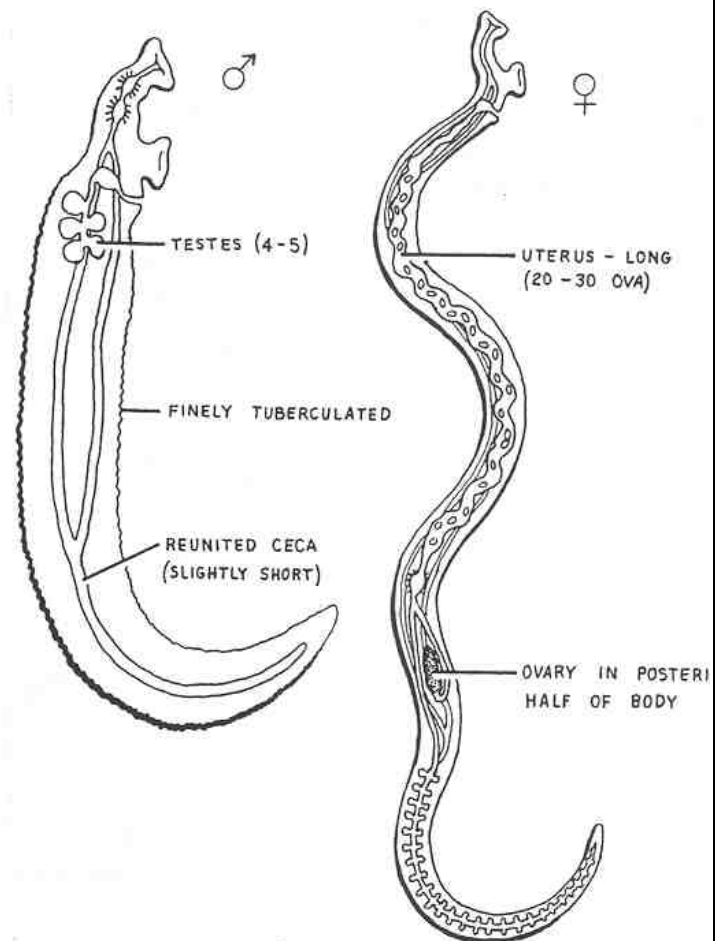


Figure 3-18. Stages of Schistosoma haematobium.

ORGANISM 4--Paragonimus westermani

GENERAL CHARACTERISTICS

COMMON NAME: Lung fluke.

GEOGRAPHICAL DISTRIBUTION: Asia and South America.

PATHOGENESIS: Pulmonary lesions, fibrous tissue capsules, pleurisy, pneumonitis.

HABITAT: Lung.

I

INTERMEDIATE HOST

FIRST: Snail.

SECOND: Crab or crayfish.

RESERVOIR HOST: Piscivores (fish-eating animals).

INFECTIVE FORM: Metacercaria.

MODE OF INFECTION: Ingestion.

SPECIMEN OF CHOICE: Sputum (also feces).

Figure 3-19. Information on Paragonimus westermani.

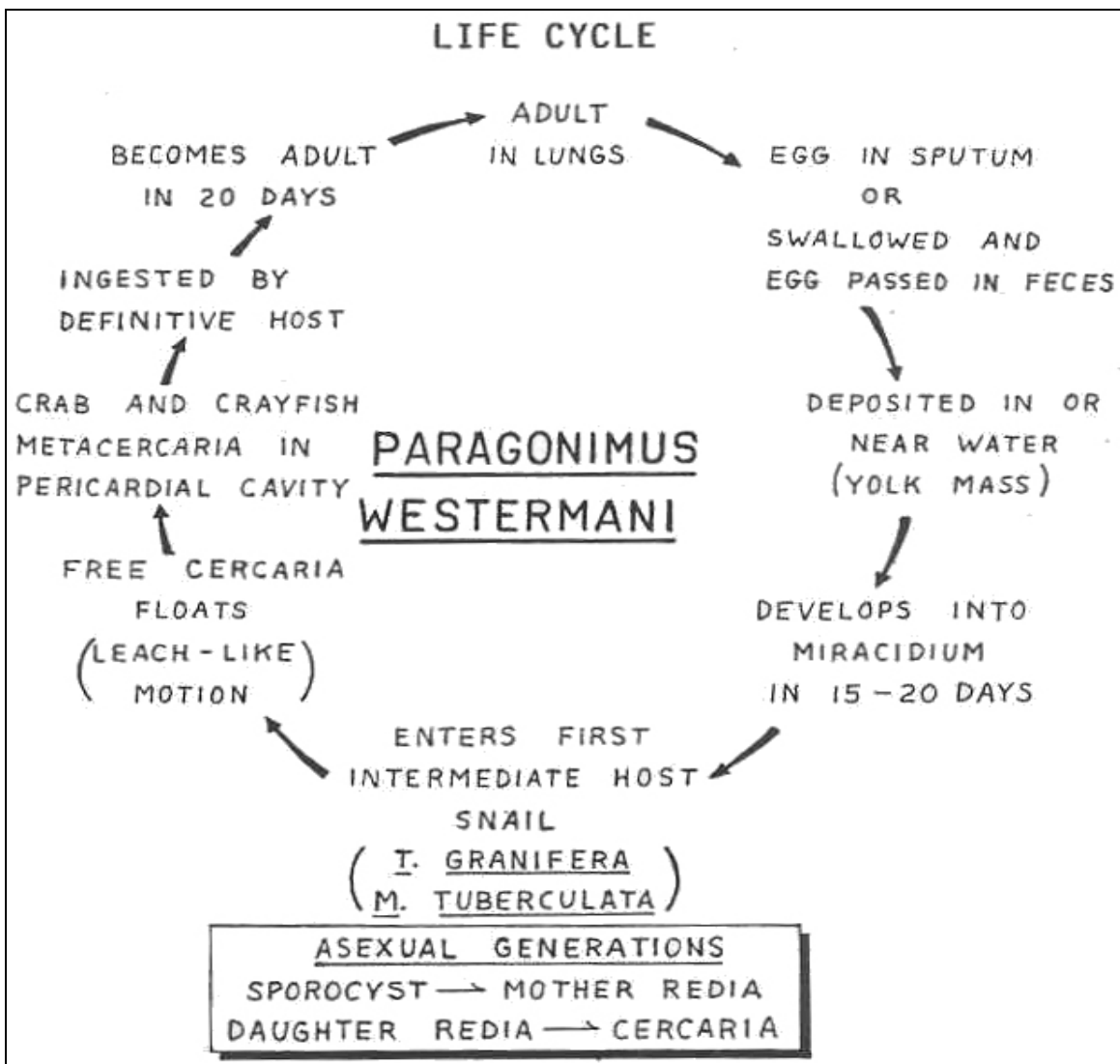


Figure 3-20. Life cycle of Paragonimus westermani.

Paragonimus westermani

OVA

SIZE: 95 x 55 μ (medium to large; four end-to-end span in HPF).

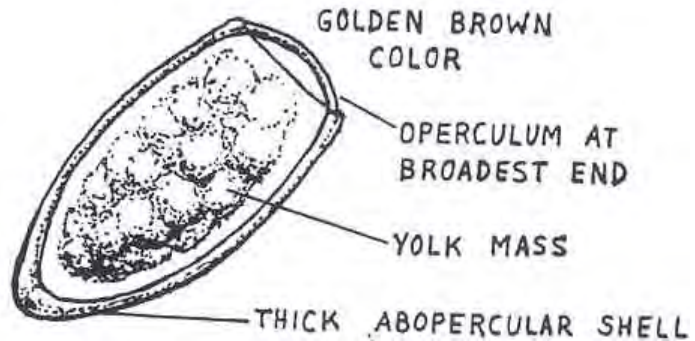
SHAPE: Oval

COLOR: Golden brown

OPERCULUM: Present at broad end.

CONTENT: Yolk mass
"differentiated," variable size of granules in the yolk.

ABOPERCULAR THICKENING



ADULT

SIZE: 10 to 14 mm long by 3 to 5 mm wide (large).

SHAPE: Oval body.

COLOR: Reddish brown.

INTESTINAL CECA: Undulating.

TESTES: Deeply lobate and para.

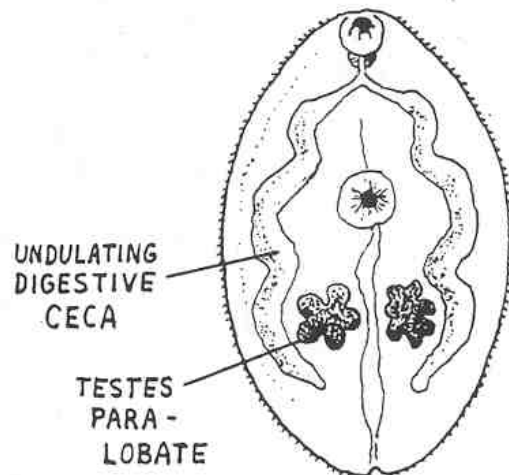


Figure 3-21. Stages of Paragonimus westermani. (concluded)

ORGANISM 5--Opisthorchis sinensis (Clonorchis sinensis)

GENERAL CHARACTERISTICS

COMMON NAME: Chinese liver fluke.

GEOGRAPHICAL DISTRIBUTION: Asia.

PATHOGENESIS: Mechanical and toxic irritations to liver, destruction of liver parenchyma, jaundice, adenomatous proliferation of tissue cells and liver cirrhosis.

HABITAT: Bile passages.

INTERMEDIATE HOST

FIRST: Snail.

SECOND: Fish.

RESERVOIR HOST: Piscivores.

INFECTIVE FORM: Metacercaria.

MODE OF INFECTION: Ingestion.

SPECIMEN OF CHOICE: Feces.

Figure 3-22. Information on Opisthorchis sinensis (Clonorchis sinensis).

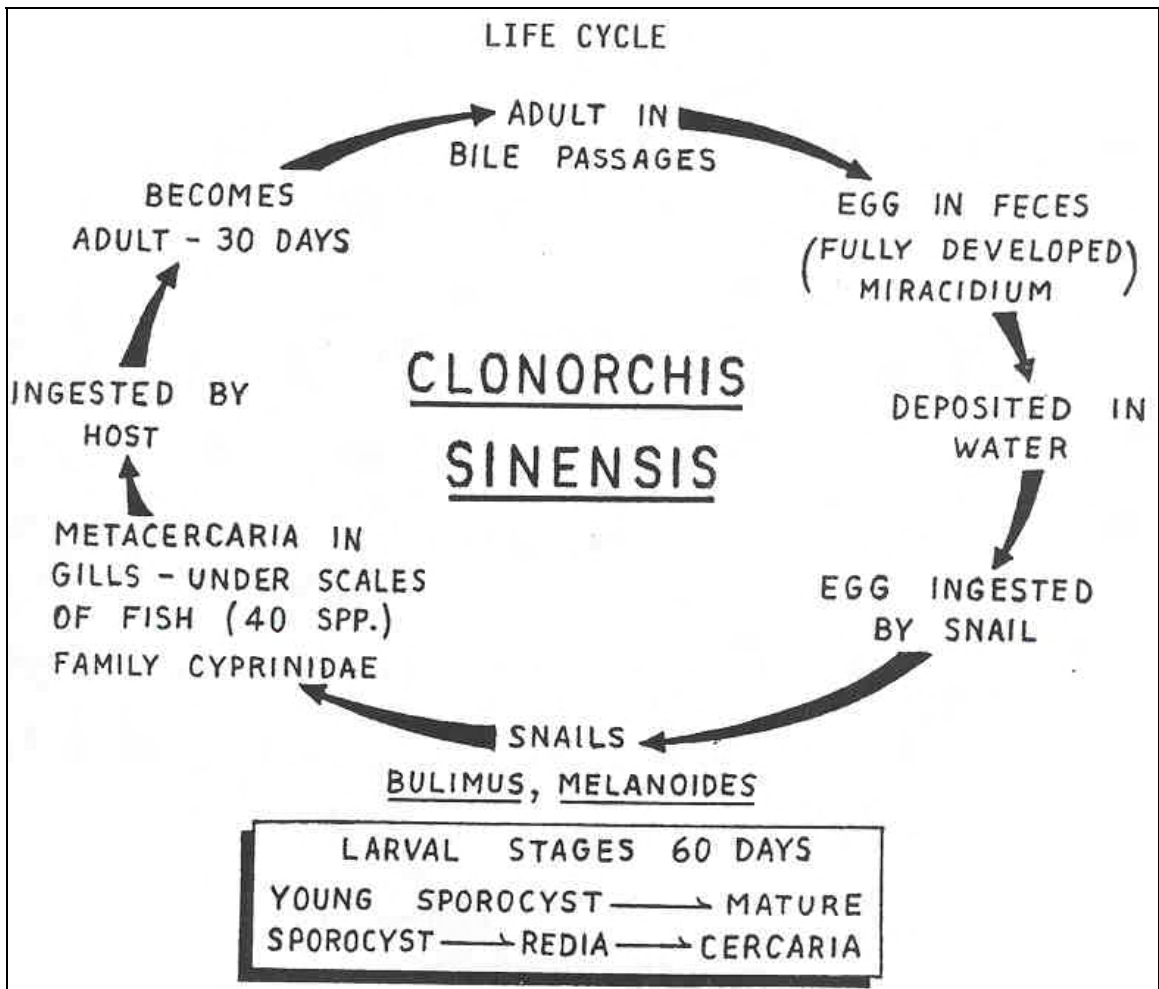


Figure 3-23. Life cycle of Opisthorchis sinensis.

Opisthorchis sinensis (Clonorchis sinensis)

OVA

SIZE: 30 x 15 μ (small, 12 end to end per HPF).

SHAPE: Vase-like.

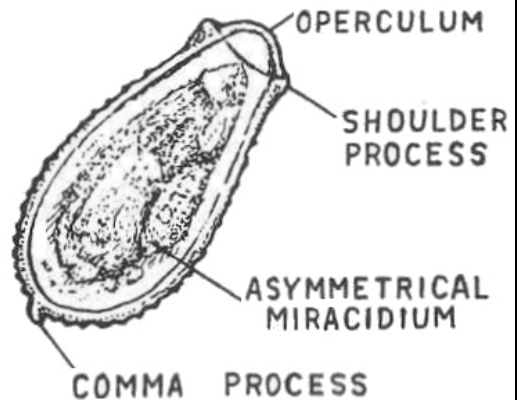
COLOR: Yellowish-brown.

OPERCULUM: Present, pronounced.

CONTENT: Asymmetrical miracidium, "boxer's glove" appearance.

ABOPERCULAR COMMA: May be seen.

BROAD OPERCULAR SHOULDERS



ADULT

SIZE: 10 to 20 mm long by 2 to 5 mm wide (medium).

SHAPE: Oval, elongated.

COLOR: Golden brown to pinkish.

INTESTINAL CECA: Straight.

TESTES: Dendritic and tandem.

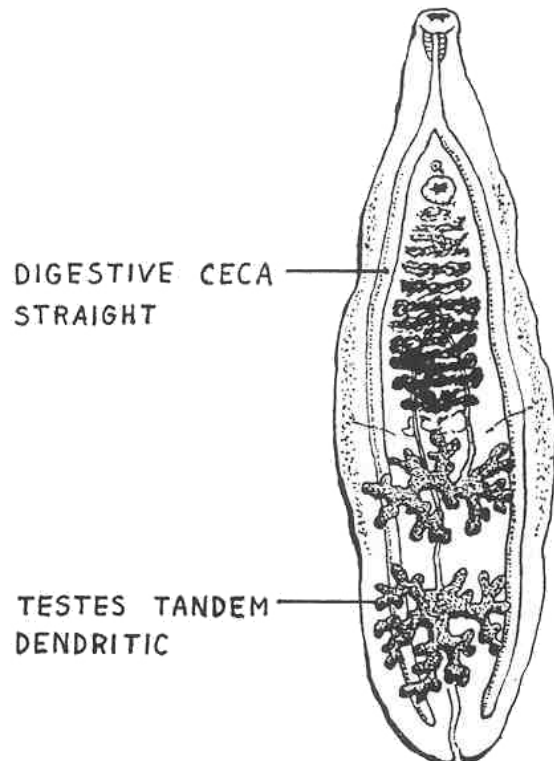


Figure 3-24. Stages of Opisthorchis sinensis.

ORGANISM 6--Opisthorchis species--O. viverrini and O. felineus

GENERAL CHARACTERISTICS

COMMON NAME: Cat liver fluke.

GEOGRAPHICAL DISTRIBUTION: O. viverrini, Thailand and Laos--O. felineus, Europe, Russia, and Vietnam.

PATHOGENESIS: Mechanical obstruction and toxic irritations in biliary passages, jaundice.

HABITAT: Bile passages.

INTERMEDIATE HOST

FIRST: Snail.

SECOND: Fish.

RESERVOIR HOST: Piscivores.

INFECTIVE FORM: Metacercaria.

MODE OF INFECTION: Ingestion.

SPECIMEN OF CHOICE: Feces.

Figure 3-25. Information on Opisthorchis viverrini and O. felineus.

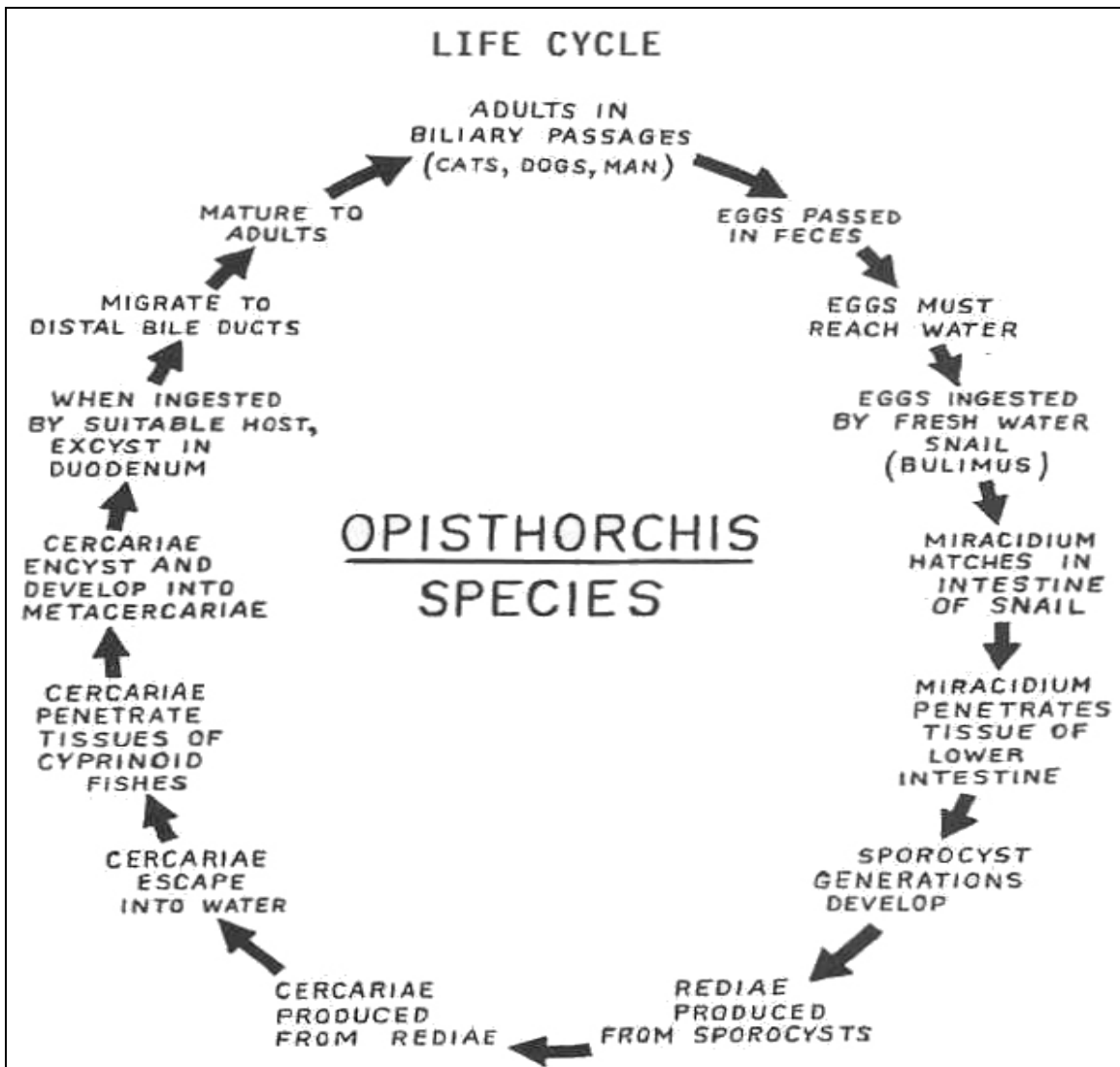


Figure 3-26. Life cycle of Opisthorchis species.

O. viverrini and O. felineus

OVA

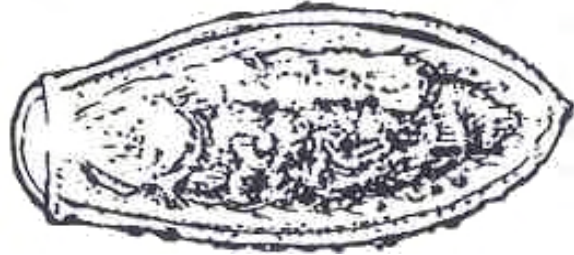SIZE: 30 x 15 μ (small) (12 end to end per HPF).

SHAPE: Vaselike.

COLOR: Yellowish-brown.

OPERCULUM: Present, pronounced.

CONTENT: Miracidium.



ADULT

SIZE: 7 to 11 mm long x 2 to 3 mm wide (medium).

SHAPE: Oval, elongated.

COLOR: Grey to brown.

INTESTINAL CECA: Straight.

TESTES: Lobed and oblique.

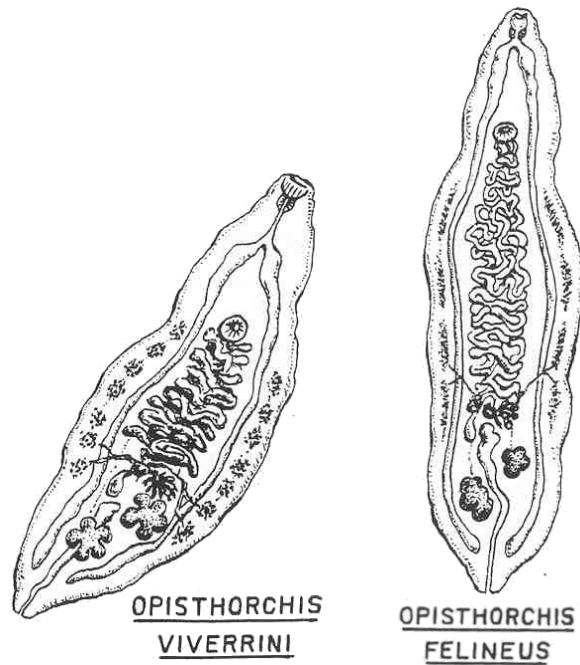


Figure 3-27. Stages of Opisthorchis species.

ORGANISM 7--Dicrocoelium dendriticum

GENERAL CHARACTERISTICS

COMMON NAME: Lancet fluke.

GEOGRAPHICAL DISTRIBUTION: Cosmopolitan.

PATHOGENESIS: Inflammation of biliary epithelium, biliary dysfunction, edema, toxemia.

HABITAT: Liver.

INTERMEDIATE HOST

FIRST: Land snail.

SECOND: Black ant (*Formica fusca*).

RESERVOIR HOST: Herbivores.

INFECTIVE FORM: Metacercaria.

MODE OF INFECTION: Ingestion.

SPECIMEN OF CHOICE: Feces.

Figure 3-28. Information on Dicrocoelium dendriticum.

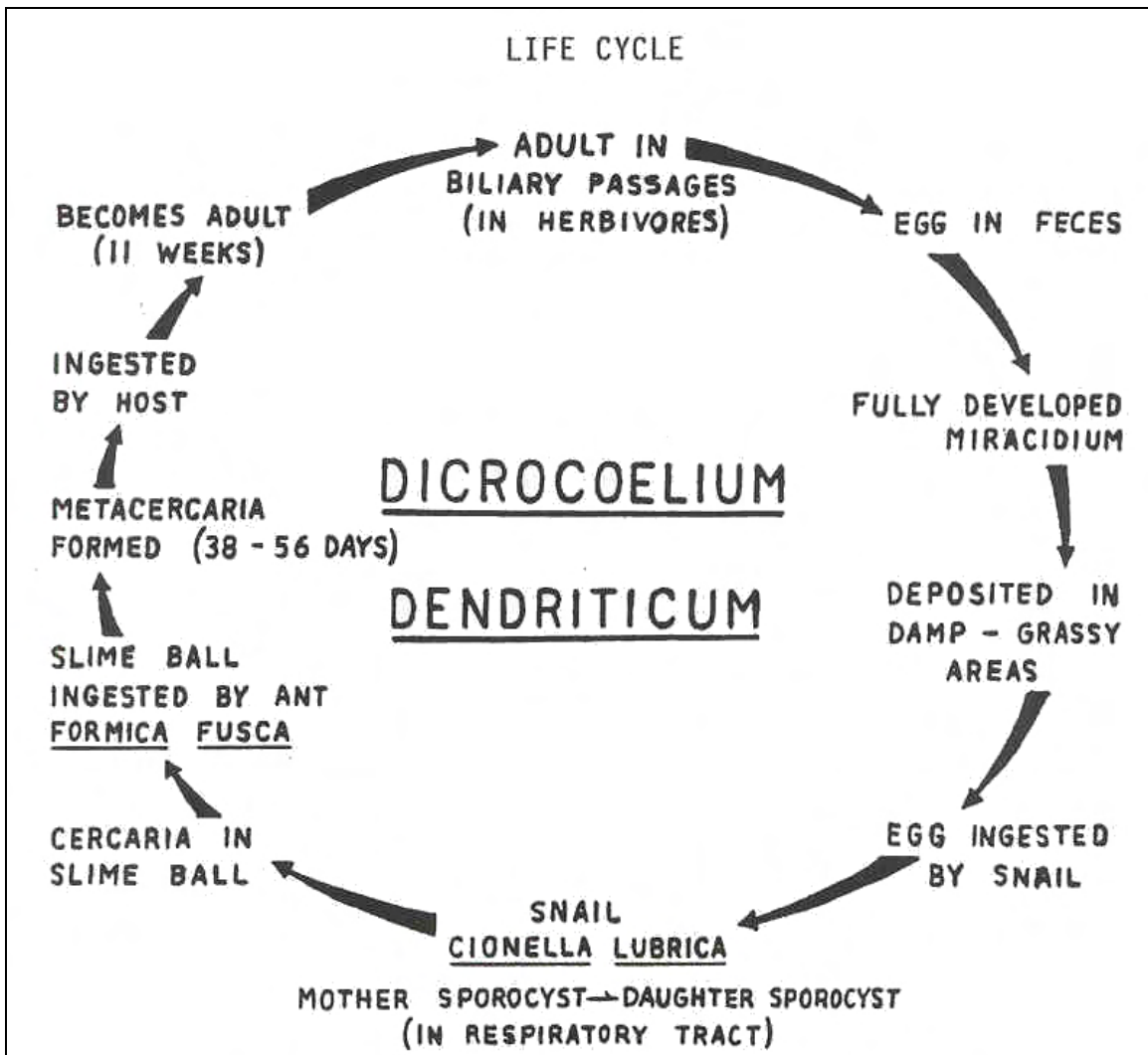


Figure 3-29. Life cycle of Dicrocoelium dendriticum.

Dicrocoelium dendriticum

OVA

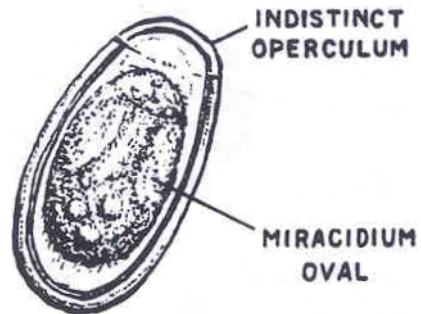
SIZE: 40 x 25 μ .

SHAPE: Oval (race track).

COLOR: Light brown.

OPERCULUM: Present, indistinct.

CONTENT: Miracidium.



ADULT

SIZE: 5 to 12 mm long by 1.5 to 2.5 mm wide (medium).

SHAPE: Elongated, lancet.

COLOR: Transparent.

INTESTINAL CECA: Straight.

TESTES: Shallow lobed and oblique; found in anterior half of the body.

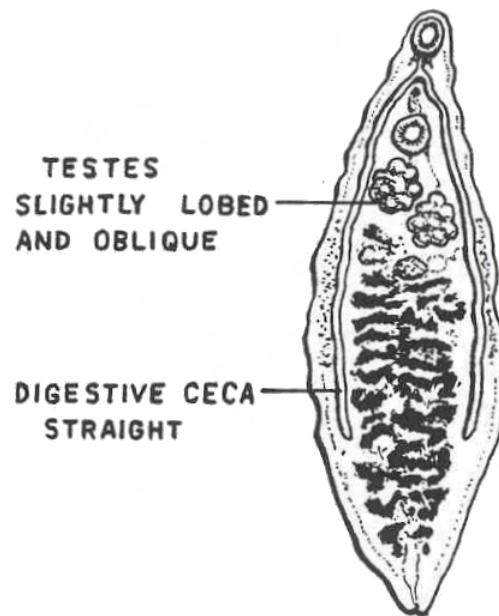


Figure 3-30. Stages of Dicrocoelium dendriticum.

ORGANISM 8--Fasciola hepatica

GENERAL CHARACTERISTICS

COMMON NAME: Sheep liver fluke.

GEOGRAPHICAL DISTRIBUTION: Worldwide; sheep-raising countries.

PATHOGENESIS: Mechanical and toxic irritation to liver, destruction of hepatic parenchyma, biliary obstruction, adenomatous and fibrotic changes, anemia (0.2 cc blood loss per worm per day), eosinophilia, cirrhosis (periportal).

HABITAT: Bile passages.

INTERMEDIATE HOST

FIRST: Snail.

SECOND: Fresh water vegetation (watercress).

RESERVOIR HOST: Herbivores and carnivores.

INFECTIVE FORM: Metacercaria.

MODE OF INFECTION: Ingestion.

SPECIMEN OF CHOICE: Feces.

Figure 3-31. Information on Fasciola hepatica.

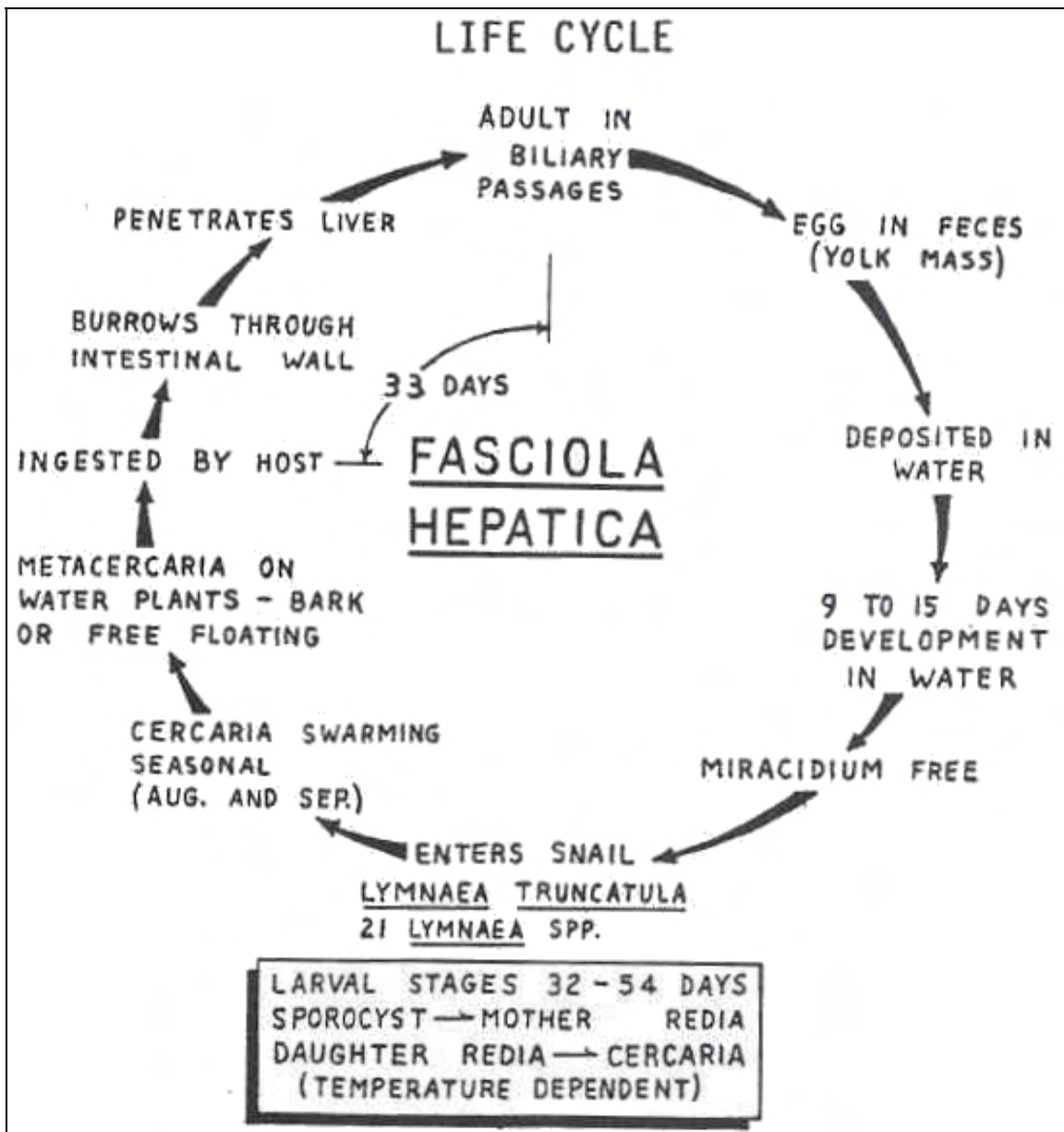


Figure 3-32. Life cycle of Fasciola hepatica.

Fasciola hepatica

OVA

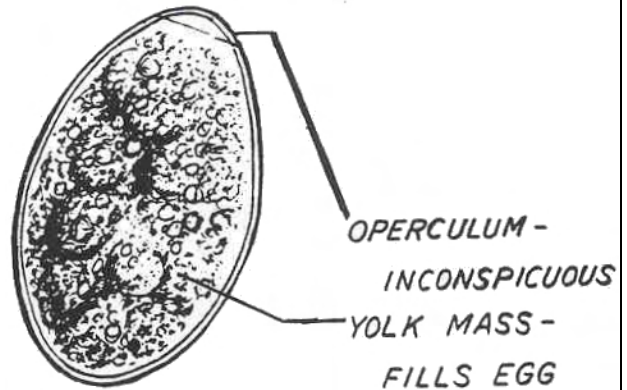
SIZE: 140 x 80 μ (large, 3 end to end will fill HPF).

SHAPE: "Hen's egg"; oval.

COLOR: Yellowish-brown

OPERCULUM: Present, indistinct.

CONTENT: Yolk mass; fills the egg.



ADULT

SIZE: 20 to 30 mm long by 8 to 13 mm wide (very large).

SHAPE: Leaf-like; prominent cephalic cone.

COLOR: Brownish.

INTESTINAL CECA: Branched.

TESTES: Dendritic and tandem.

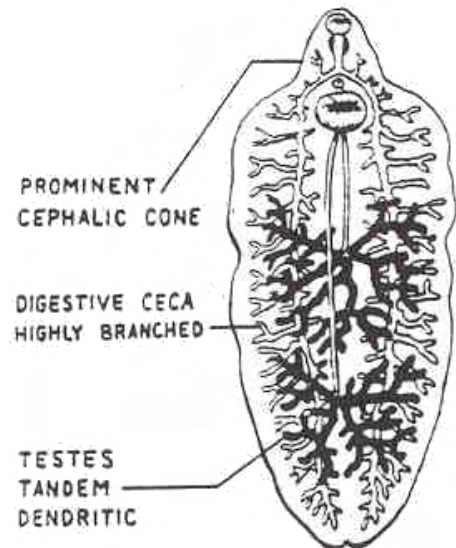


Figure 3-33. Stages of Fasciola hepatica.

ORGANISM 9--Fasciolopsis buski

GENERAL CHARACTERISTICS

COMMON NAME: Giant intestinal fluke.

GEOGRAPHICAL DISTRIBUTION: Asia.

PATHOGENESIS: Intestinal inflammation, ulceration and abscesses; generalized massive edema, obstruction, eosinophilia up to 35.

HABITAT: Small intestines.

INTERMEDIATE HOST

FIRST: Snail.

SECOND: Aquatic vegetation.

RESERVOIR HOST: Pigs, dogs, and rabbits.

INFECTIVE FORM: Metacercaria.

MODE OF INFECTION: Ingestion.

SPECIMEN OF CHOICE: Feces.

Figure 3-34. Information on Fasciolopsis buski.

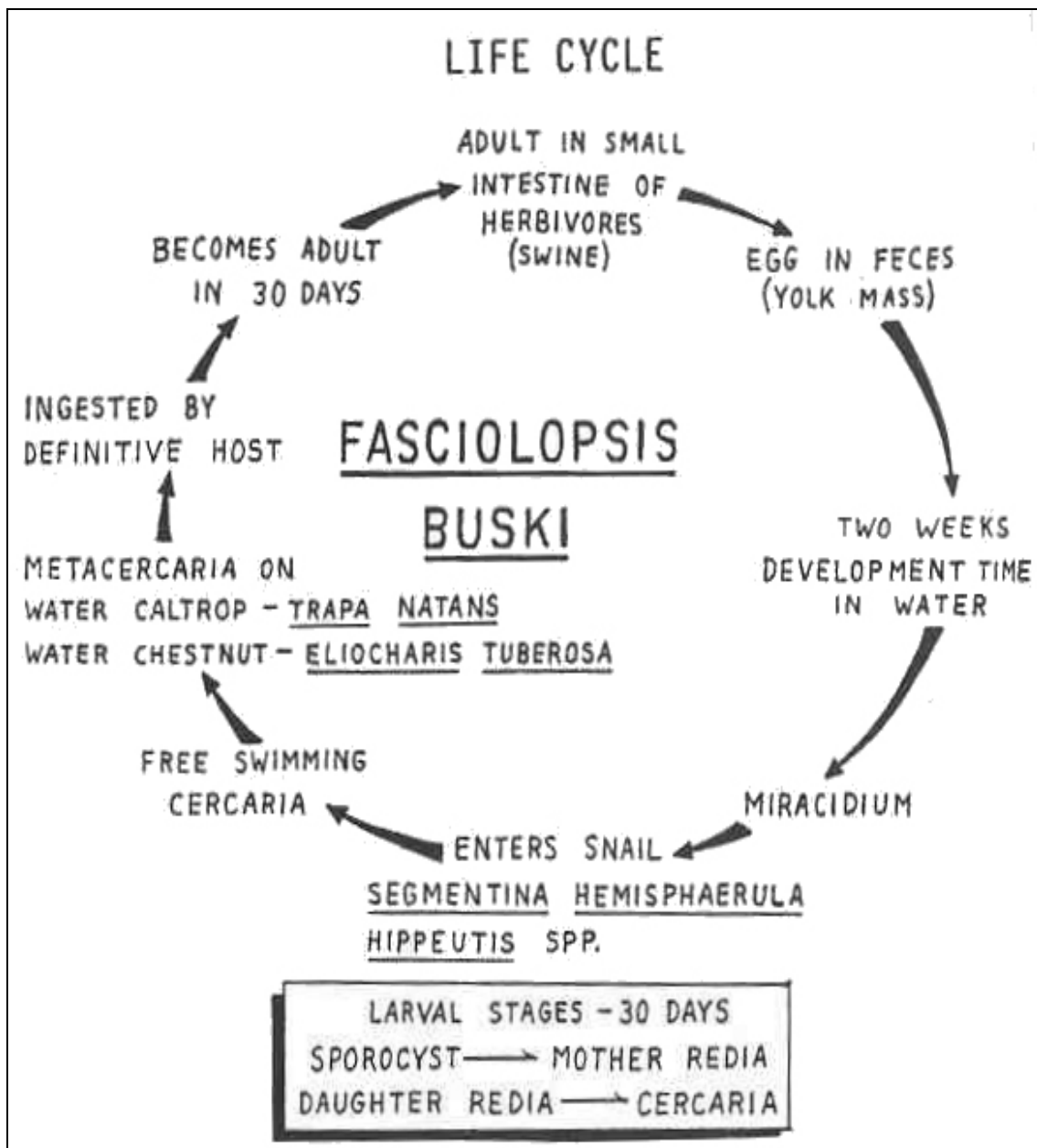


Figure 3-35. Life cycle of Fasciolopsis buski.

Fasciolopsis buski

OVA

Almost identical to F. hepatica except that the granules in the yolk mass are uniformly distributed.

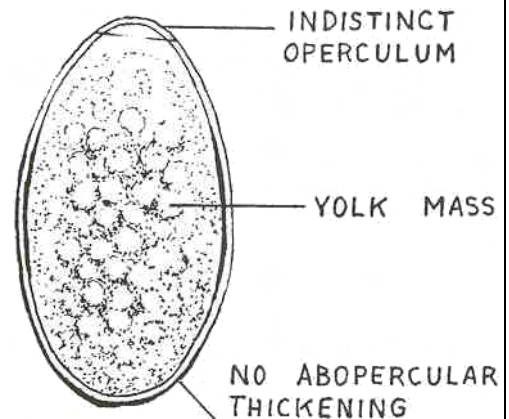
SIZE: 140 x 80 μ (large, 3 end to end will fill HPF).

SHAPE: "Hen's egg"; oval.

COLOR: Yellowish-brown.

OPERCULUM: Present, indistinct.

CONTENT: Yolk mass; fills the egg.



ADULT

SIZE: 25 to 45 mm long by 8 to 12 mm wide (very large).

SHAPE: Leaf-like, no cephalic cone.

COLOR: Flesh-colored.

INTESTINAL CECA: Undulating.

TESTES: Dendritic and tandem.

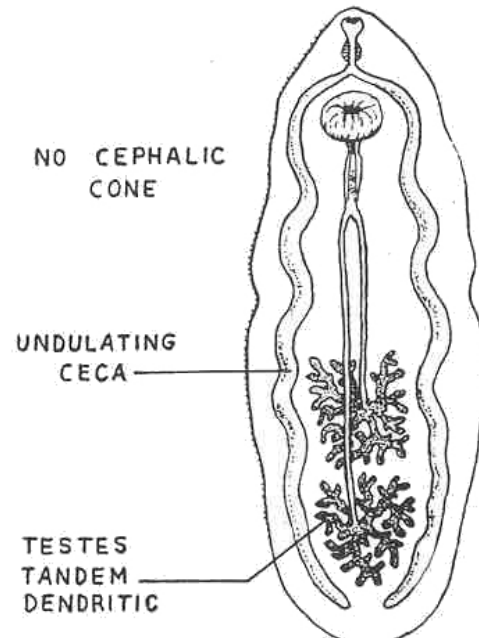


Figure 3-36. Stages of Fasciolopsis buski.

ORGANISM 10--Metagonimus yokogawai

GENERAL CHARACTERISTICS

COMMON NAME: Small intestinal fluke.

GEOGRAPHICAL DISTRIBUTION: Far East.

PATHOGENESIS: Occasionally eggs may enter lymphatics or mesenteric venules causing granulomatous lesions in heart and nervous system.

HABITAT: Small intestines.

INTERMEDIATE HOST

FIRST: Snail.

SECOND: Fish.

RESERVOIR HOST: Piscivores and birds.

INFECTIVE FORM: Metacercaria.

MODE OF INFECTION: Ingestion.

SPECIMEN OF CHOICE: Feces.

Figure 3-37. Information on Metagonimus yokogawai.

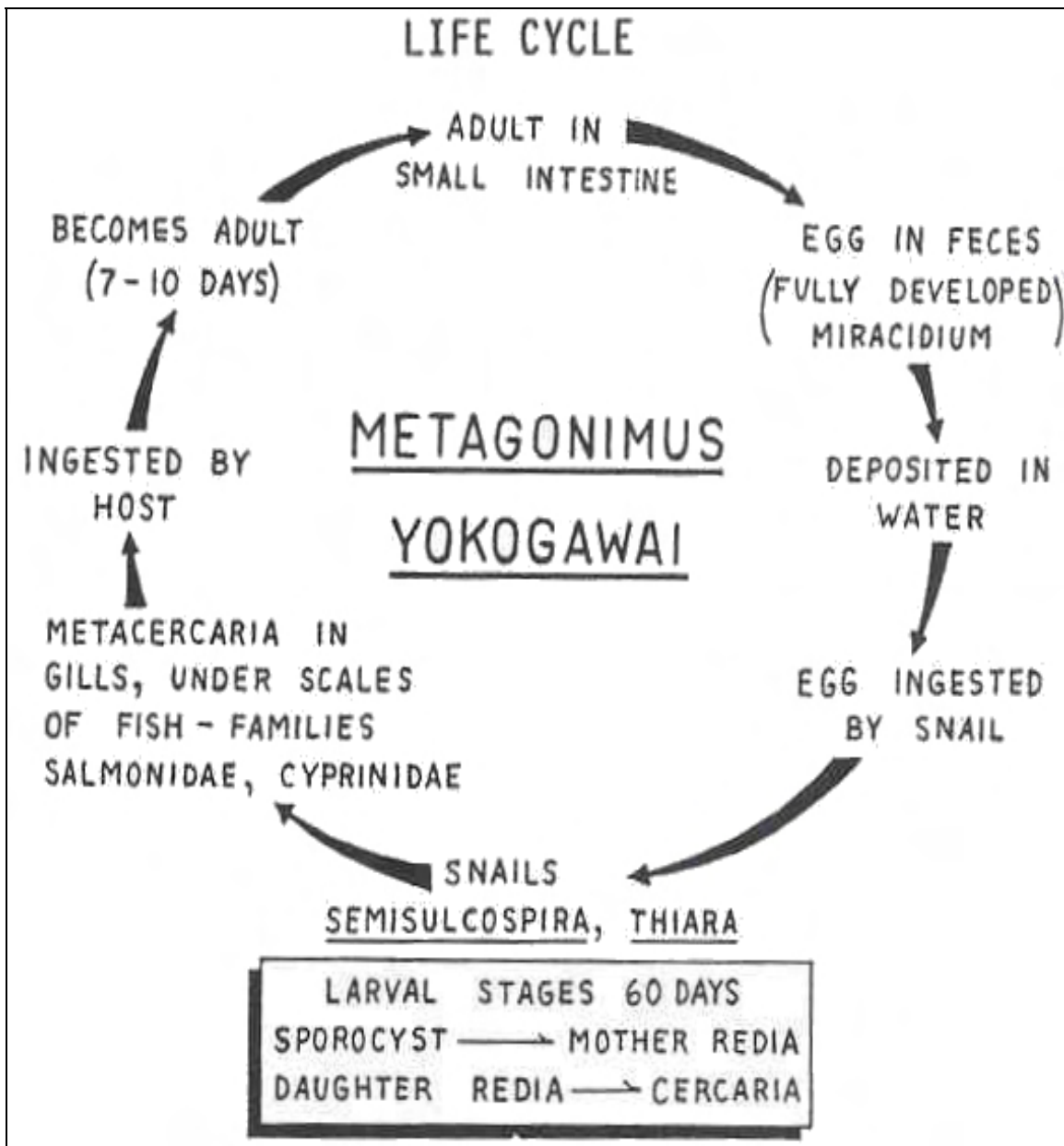


Figure 3-38. Life cycle of Metagonimus yokogawai.

Metagonimus yokogawai

OVA

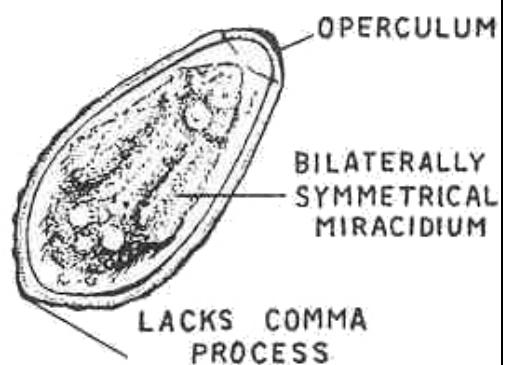
SIZE: 30 x 15 μ (small, 12 end to end per HPF), resemble ova of the Opisthorchis sp.

SHAPE: Vase-like.

COLOR: Yellowish-brown.

OPERCULUM: Present, pronounced.

CONTENT: Miracidium (symmetrical).



ADULT

SIZE: 0.8 to 1.4 mm long by 0.4 to 0.7 mm wide.

SHAPE: Gourd-like

COLOR: Grayish

INTESTINAL CECA: Straight

TESTES: Oval and oblique

OFF-CENTER ACETABULUM

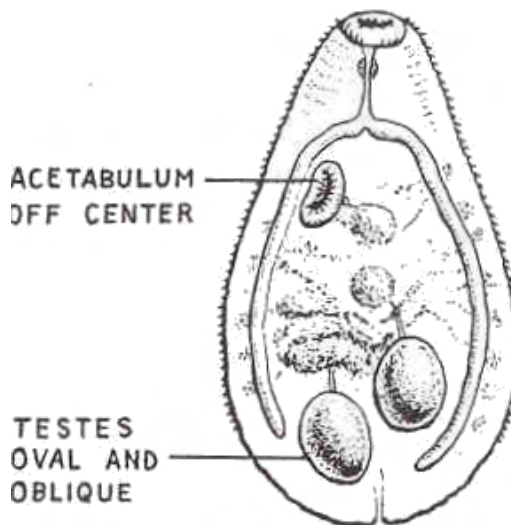


Figure 3-39. Stages of Metagonimus yokogawai.

ORGANISM 11--Heterophyes heterophyes

GENERAL CHARACTERISTICS

COMMON NAME: Small intestinal fluke.

GEOGRAPHICAL DISTRIBUTION: Egypt, (same as M. yokogawai) Palestine, Far East.

HABITAT: Small intestines.

INTERMEDIATE HOST

FIRST: Snail.

SECOND: Fish.

RESERVOIR HOST: Piscivores and birds.

INFECTIVE FORM: Metacercaria.

MODE OF INFECTION: Ingestion.

SPECIMEN OF CHOICE: Feces.

Figure 3-40. Information on Heterophyes heterophyes.

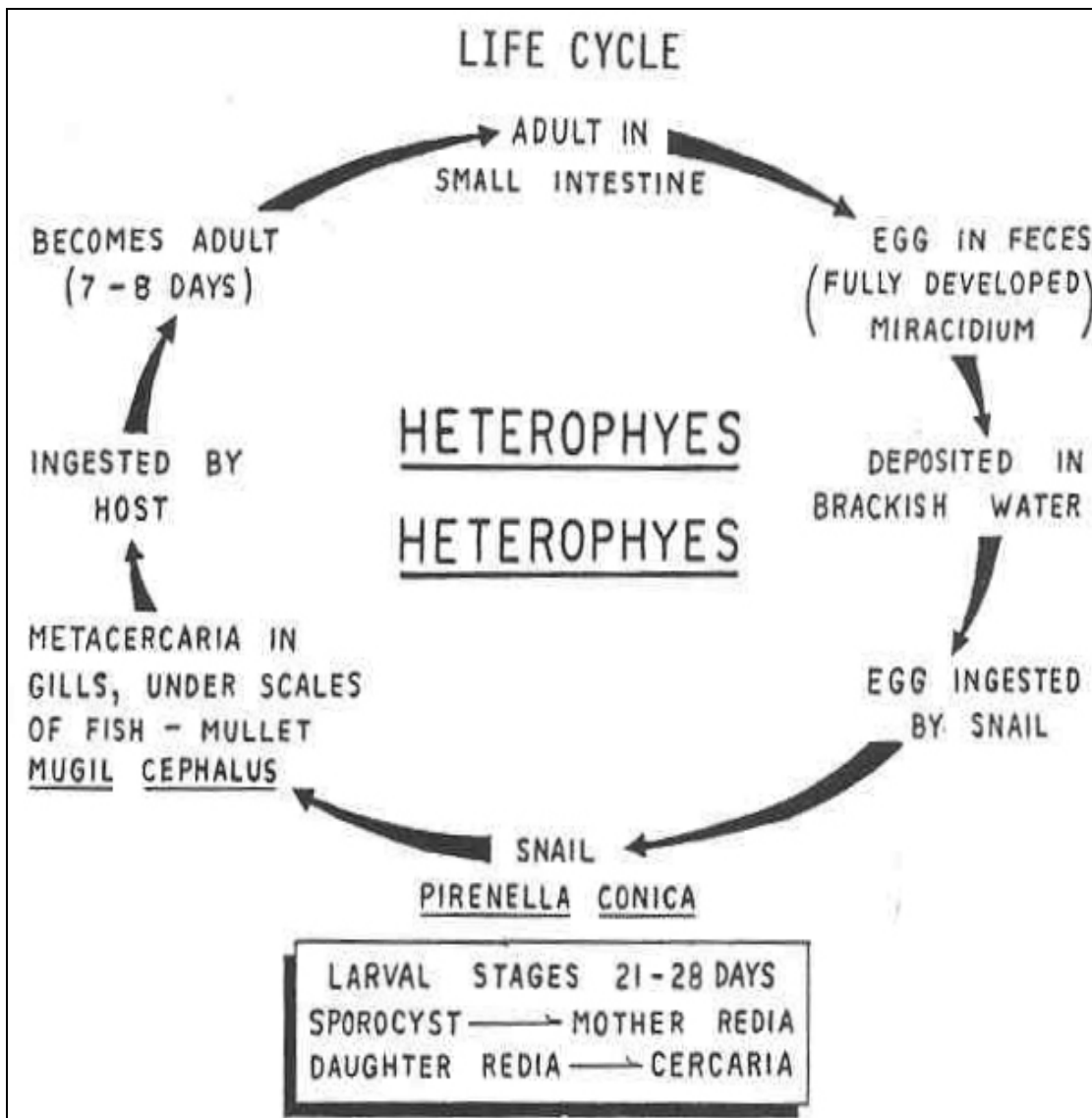


Figure 3-41. Life cycle of Heterophyes heterophyes.

Heterophyes heterophyes

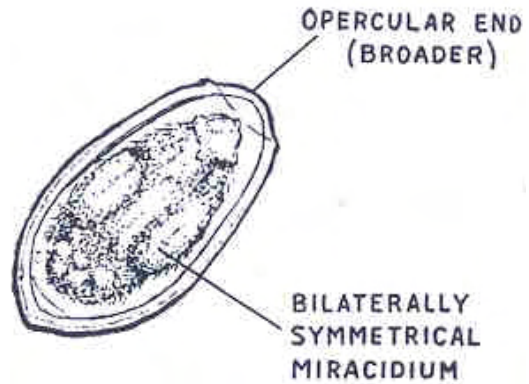
OVA

SIZE: 30 x 15 μ (small, 12 end to end per HPF), resemble ova of the Opisthorchis sp.
SHAPE: Vase-like.

COLOR: Yellowish-brown.

OPERCULUM: Present, pronounced.

CONTENT: Miracidium.



ADULT

SIZE: 1.0 to 1.7 mm long by 0.3 to 0.7 mm wide (very small).

SHAPE: Gourd-like.

COLOR: Grayish.

INTESTINAL CECA: Straight.

CENTERED ACETABULUM

GONOTYL IS PRESENT

Retractile sucker-like structure.
Armed with hooklets.

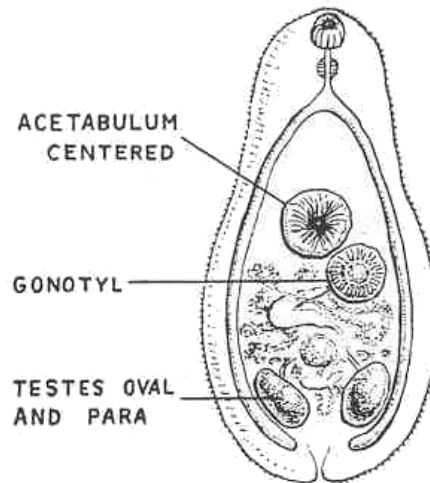


Figure 3-42. Stages of Heterophyes heterophyes.

ORGANISM 12--Gastrodiscoides hominis

GENERAL CHARACTERISTIC

COMMON NAME: Colonic fluke.

GEOGRAPHICAL DISTRIBUTION--India, Viet Nam.

PATHOGENESIS: Mucosal inflammation of cecum and ascending colon.

HABITAT: large intestines; cecum and colon.

INTERMEDIATE HOST

FIRST--Snail.

SECOND--Aquatic vegetation.

RESERVOIR HOST--Hogs and Napu mouse deers.

INFECTIVE FORM--Metacercaria.

MODE OF INFECTION--Ingestion.

SPECIMEN OF CHOICE--Feces.

Figure 3-43. Information on Gastrodiscoides hominis.

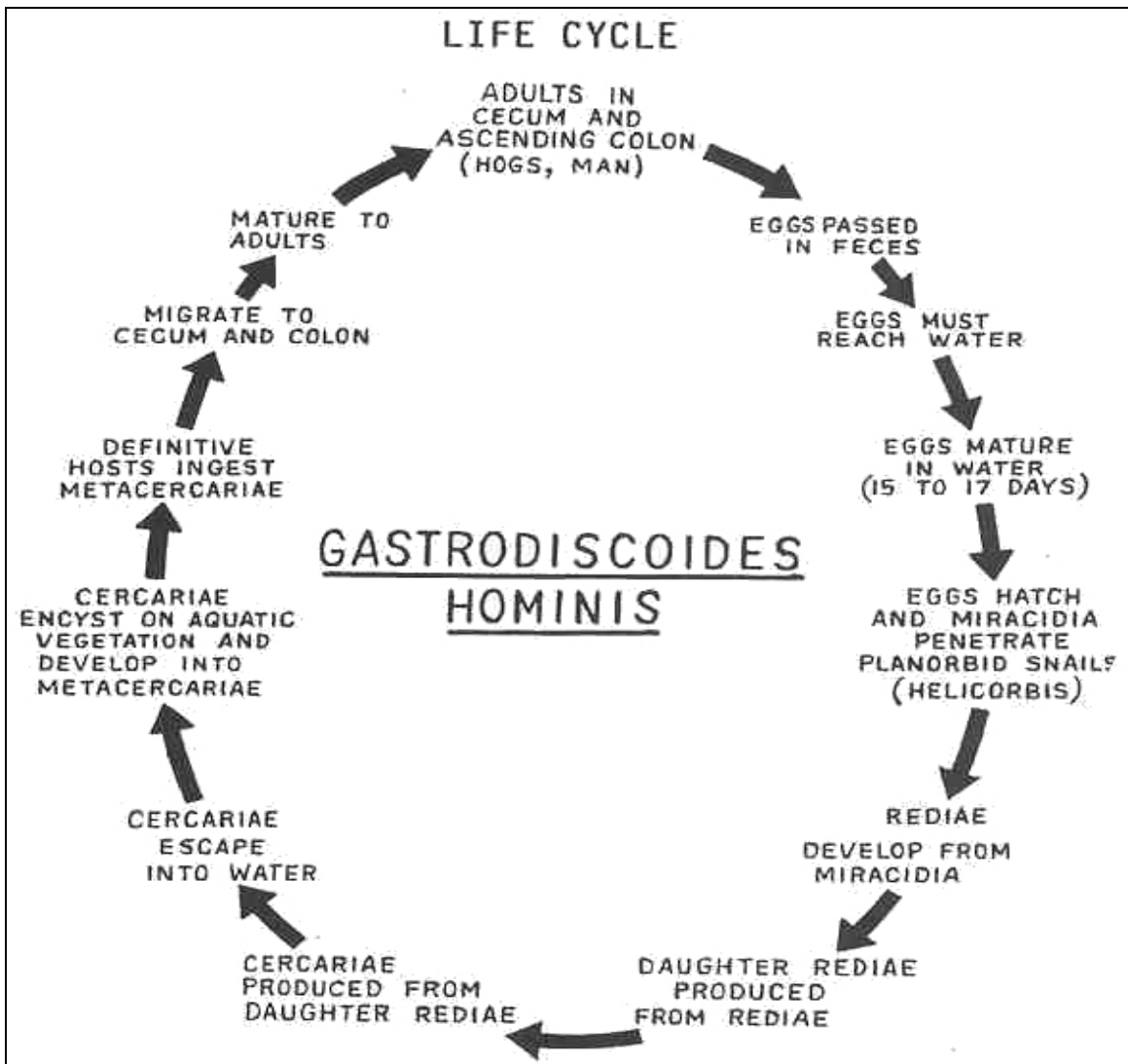


Figure 3-44. Life cycle of Gastrodiscoides hominis.

Gastrodiscoides hominis

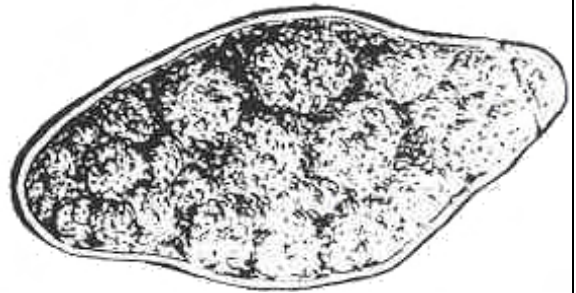
OVA

SIZE--160 x 65 μ (large).
SHAPE--Spindle-shaped.

COLOR--Light brown.

OPERCULUM--Present, distinct.

CONTENT--Yolk mass.



ADULT

SIZE--5 to 10 mm long by 2 to 5 mm wide (medium).

SHAPE--Gourd-like.

COLOR--Reddish.

INTESTINAL CECA--Straight.

TESTES--Anterior, lobate, and tandem.

ACETABULUM--Very wide and posterior.

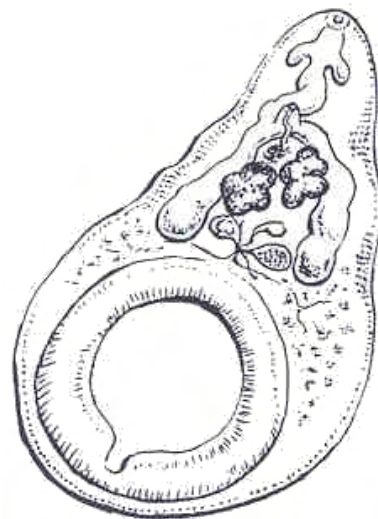


Figure 3-45. Stages of Gastrodiscoides hominis.

ORGANISM 13--Echinostoma species

GENERAL CHARACTERISTICS

COMMON NAME--Spiny fluke.

GEOGRAPHICAL DISTRIBUTION: Asia.

PATHOGENESIS--Heavy infections induce catarrhal inflammations; necrosis of mucosa.

HABITAT--Small intestines.

INTERMEDIATE HOST

FIRST--Snail.

SECOND--Clam or snail.

RESERVOIR HOST--Dogs, cats, rats, and birds.

INFECTIVE FORM--Metacercaria.

MODE OF INFECTION--Ingestion.

SPECIMEN OF CHOICE--Feces.

Figure 3-46. Information on Echinostoma.

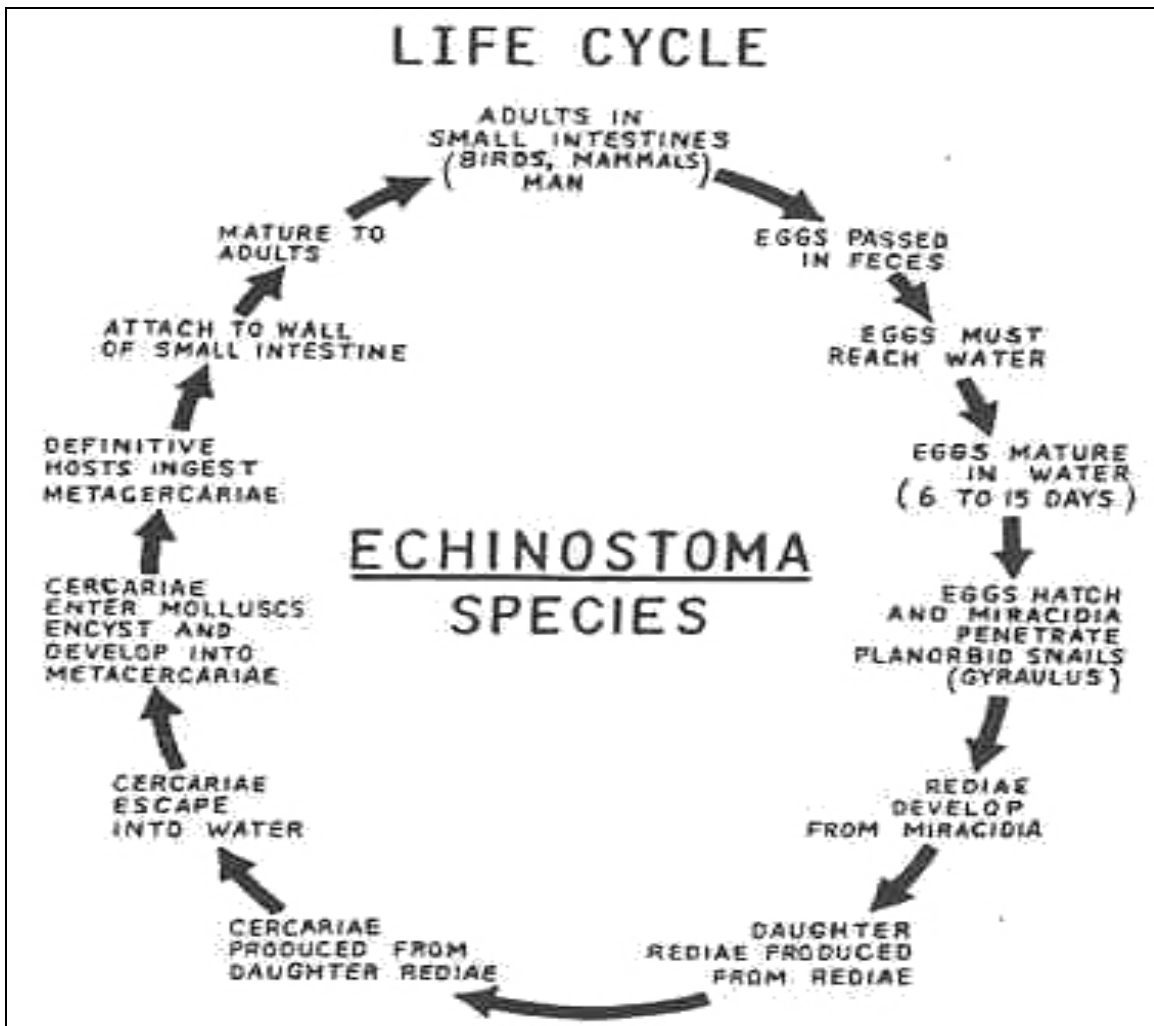


Figure 3-47. Life cycle of Echinostoma species.

Echinostoma species

OVA

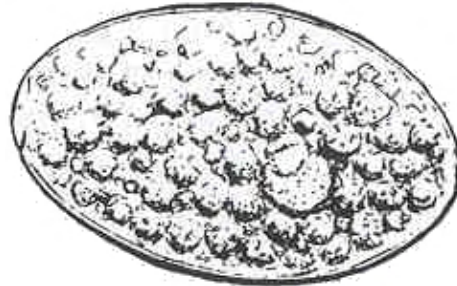
SIZE: 90 x 60 μ (large, smaller than F. hepatica).

SHAPE: Hen's egg, similar to F. hepatica.

COLOR: Straw.

OPERCULUM: Present, indistinct.

CONTENT--Yolk mass.



ADULT

SIZE: 5 to 20 mm long by 2 to 5 mm wide (medium).

SHAPE: Oval, elongated.

COLOR: Reddish-gray

INTESTINAL CECA: Straight

TESTES: Lobate and tandem.

CIRCUMORAL DISK: Circlet of spines around the oral sucker.

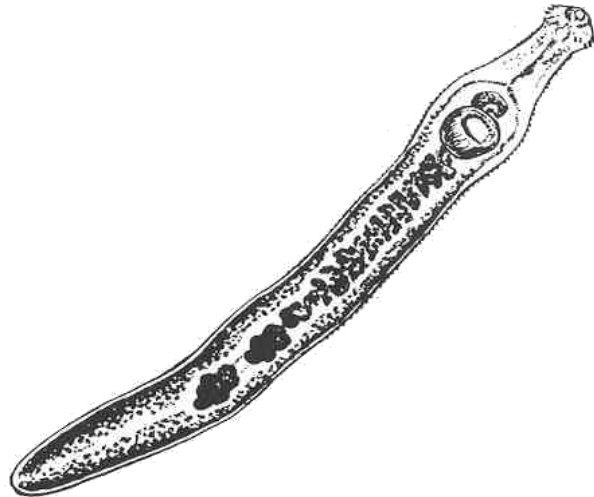


Figure 3-48. Stages of Echinostoma species.

Section III. CLASS CESTODA

3-8. GENERAL COMMENTS

This class consists of polyzoic (many body parts) flat worms commonly known as tapeworms. Evolution has rendered these organisms as strict parasites incapable of a free living condition. The digestive tract is absent and the worms absorb their nutrients from the surroundings. The muscular system is poorly developed. The reproductive system, on the other hand, has been developed to such an extent that over 90 reproductive structures. Both male and female organs are found in each individual segment which is called a proglottid. Excretion is handled by a pair of longitudinal excretory canals which run the entire length of the proglottid. Longitudinal nerve cords are also found to be shared by the complete worm. Reproduction is sexual and it is performed internally. Most times, the tapeworms cross-fertilize between two different worms, but fertilization may take place between two individual proglottids of the same organism. They have a complex life cycle requiring, in most instances, at least one intermediate host where the larval stages must develop prior to infecting the definitive host again. Each individual life cycle will be discussed with the corresponding organism.

3-9. ORDERS

There are two orders within this class. The order Pseudophyllidea contains Diphyllobothrium latum and Spirometra species. Cyclophyllidea contains members of Taenia, Taeniarhynchus, Echinococcus, Hymenolepsis, and Dipylidium.

NOTE: See figures 3-49 and 3-50; see table 3-2.

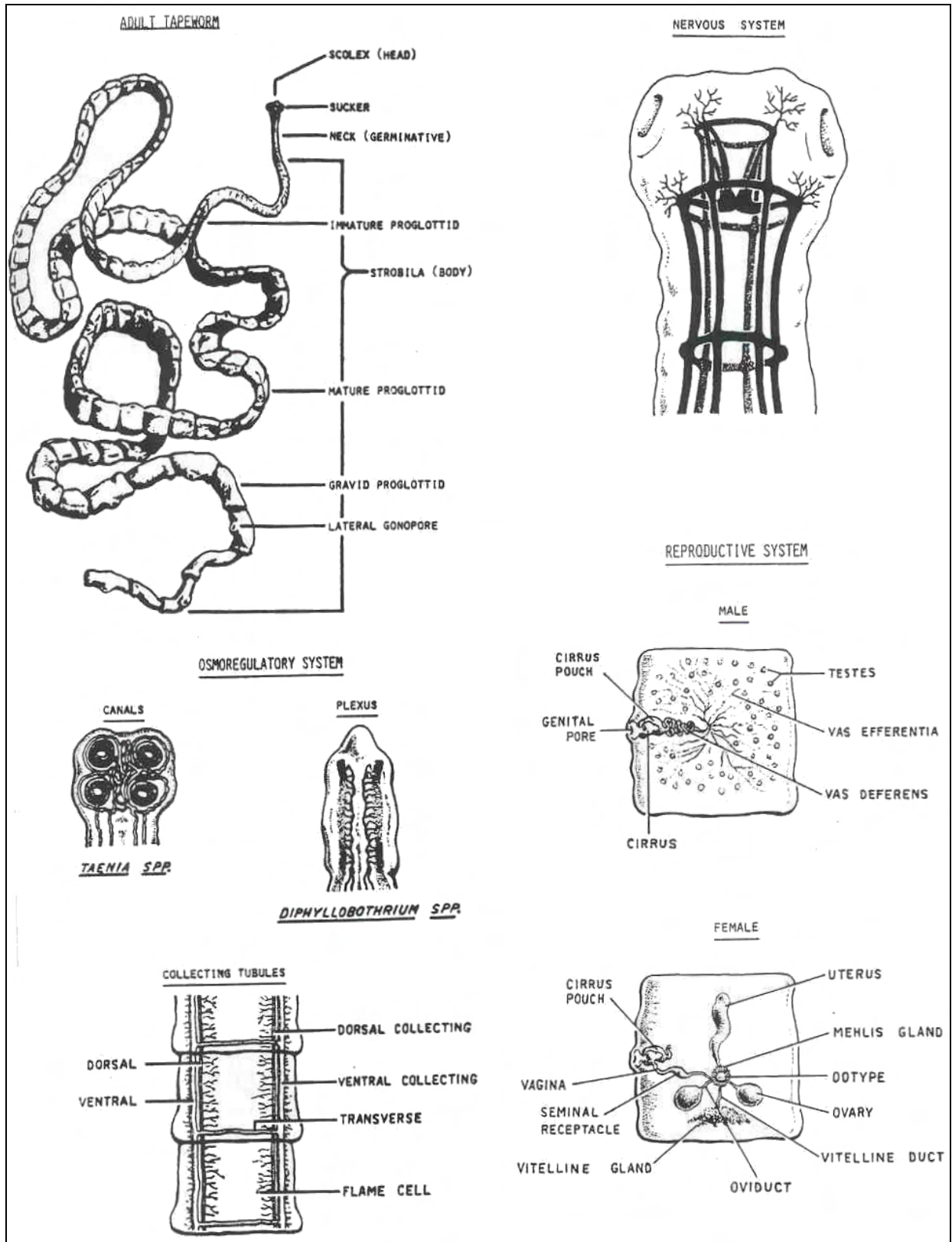


Figure 3-49. Typical tapeworm.

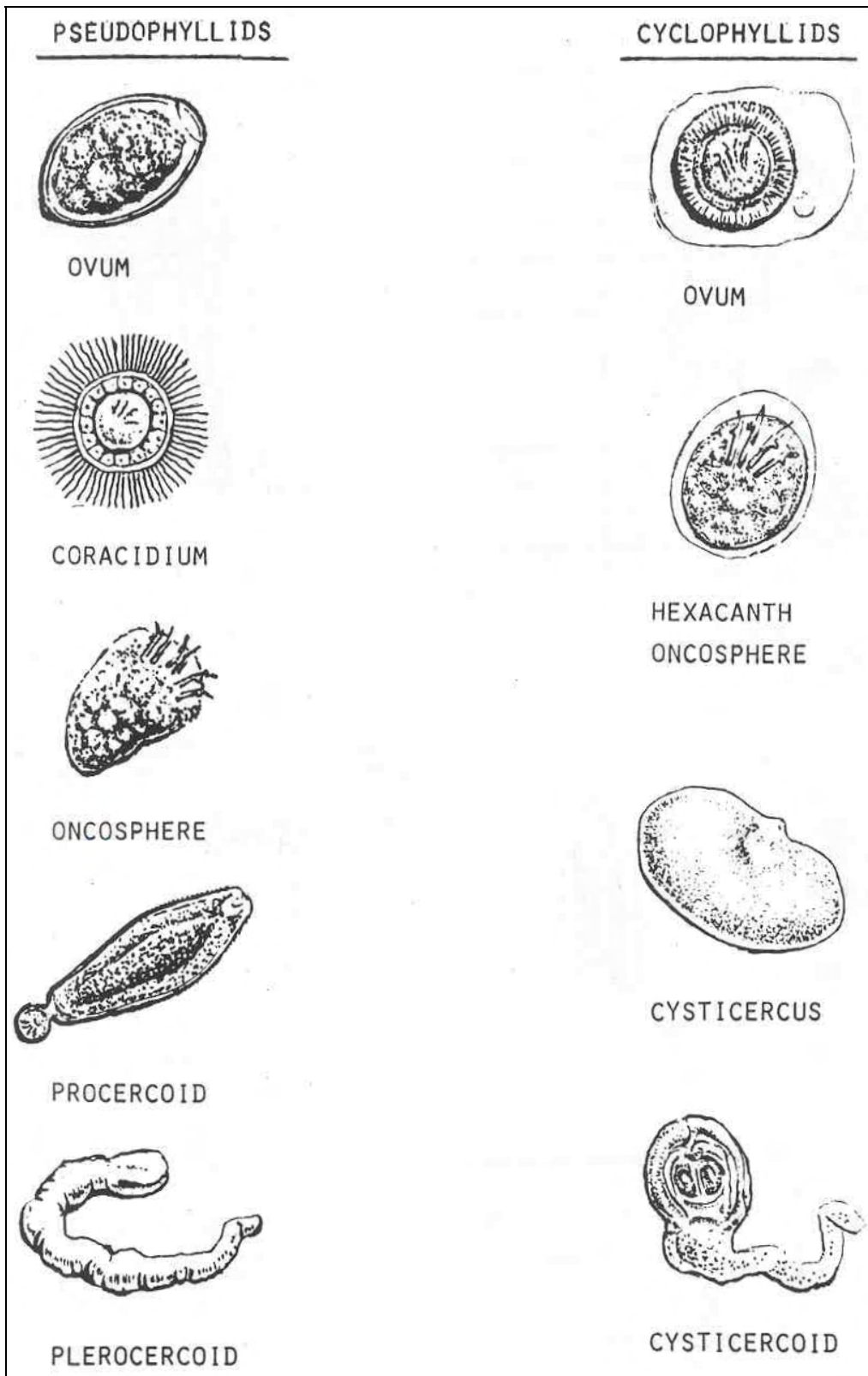


Figure 3-50. Examples of Cestoda ova and larval stages.

KEY TO IMPORTANT ADULT HUMAN CESTODES

1.	Scolex "head" recovered.....	2
	Gravid proglottids recovered.....	5
	Complete worm (scolex & 3 proglottids: immature, mature, and gravid).....	<u>Echinococcus</u> species
2.	Large scolex (about 1-2 mm).....	3
	Small scolex (0.3 to 0.5 mm).....	4
3.	Scolex with two longitudinal, slit-like grooves or suckers.....	<u>Diphyllobothrium latum</u>
	Scolex with four round suckers, unarmed.....	<u>Taeniarhynchus saginatus</u>
	Scolex with four round suckers, armed.....	<u>Taenia solium</u>
4.	Scolex club-shaped about 0.5 mm, unarmed.....	<u>Hymenolepis diminuta</u>
	Scolex armed with one row of large hooks, about 0.3 mm in diameter	<u>Hymenolepis nana</u>
	Scolex armed with 3-7 rows of small hooks, 0.25 to 0.5 mm in diameter.....	<u>Dipylidium caninum</u>
5.	Segments broader than long.....	6
	Segments longer than broad.....	8
6.	Single ventral genital pore, rosette uterus.....	<u>Diphyllobothrium latum</u>
	Single lateral genital pore, uterus: transverse elongated sac.....	7
7.	Segments less than 1 mm in breadth.....	<u>Hymenolepis nana</u>
	Segments about 2.5 mm in breadth.....	<u>Hymenolepis diminuta</u>
8.	Uterus composed of a large number of egg's packets, bilateral genital pores.....	<u>Dipylidium caninum</u>
	Uterus with a median stem and lateral branches, single genital pore.....	9
9.	Uterus with 7 to 13 lateral uterine branches per side.....	<u>Taenia solium</u>
	Uterus, with 15-30 lateral uterine branches per side..	<u>Taeniarhynchus saginatus</u>

Table 3-2. Key to important adult human cestodes.

3-10. COMMON PARASITES OF CLASS CESTODA

See figures 3-51 through 3-77.

ORGANISM 1--Diphyllobothrium latum

GENERAL CHARACTERISTICS

COMMON NAME: Fish tapeworm.

GEOGRAPHICAL DISTRIBUTION: Worldwide.

PATHOGENESIS: Often asymptomatic; intestinal obstruction, eosinophilia, toxemia, malnutrition, vitamin B₁₂ deficiency, pernicious anemia.

HABITAT: Small intestines.

INTERMEDIATE HOST

FIRST: Copepod.

SECOND: Fresh water fish.

RESERVOIR HOST: Piscivores.

INFECTIVE FORM: Plerocercoid larva (sparganum).

MODE OF INFECTION: Ingestion.

SPECIMEN OF CHOICE: Feces.

Figure 3-51. Information on Diphyllobothrium latum.

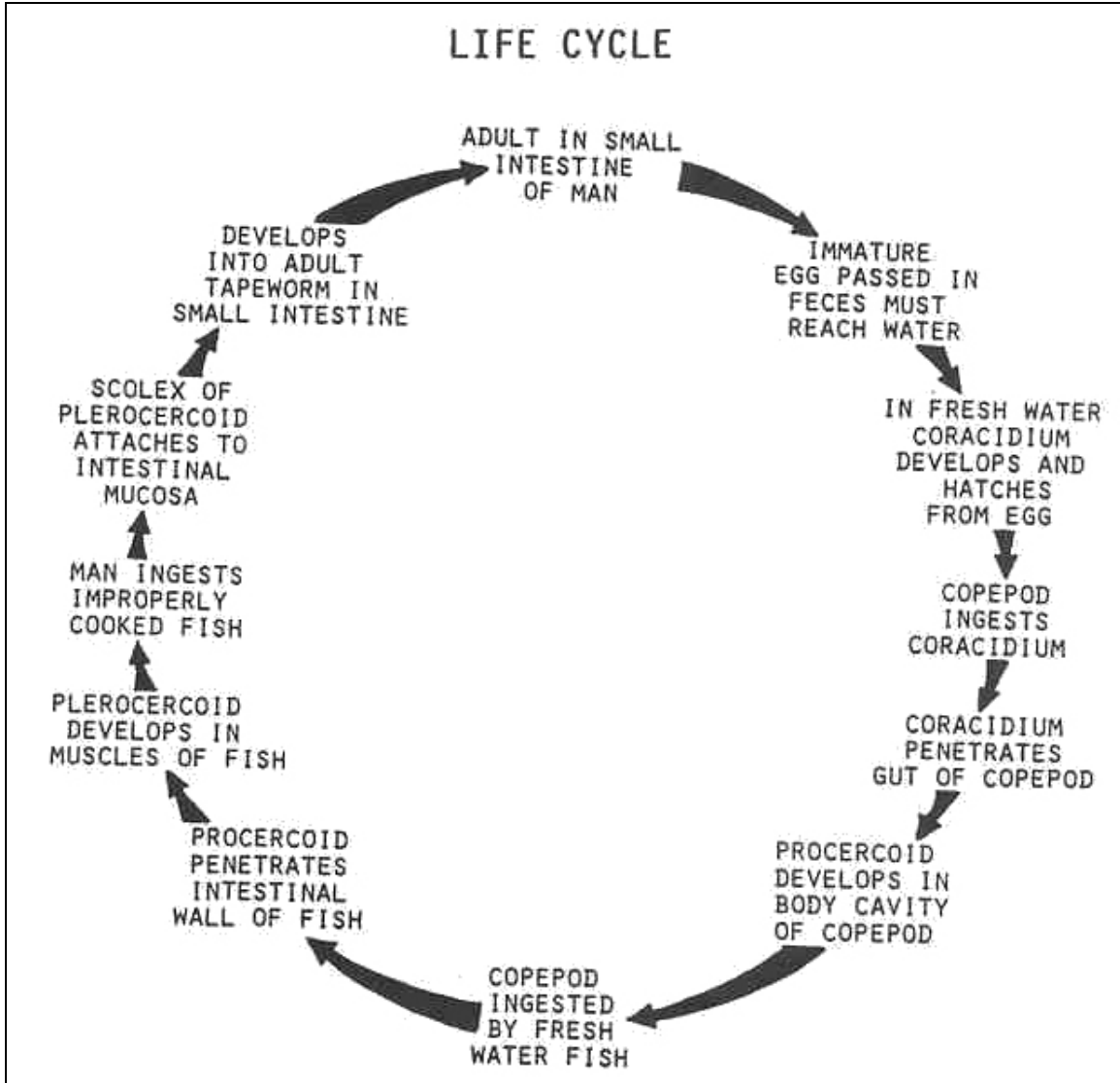


Figure 3-52.. Life cycle of Diphylobothrium latum.

Diphyllobothrium latum

OVA

SIZE: 45 x 65 μ (medium).

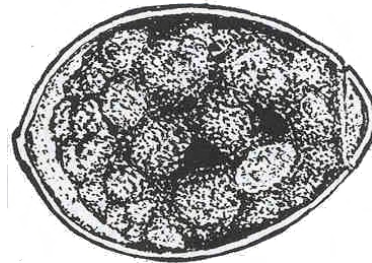
SHAPE: Ovoid.

COLOR: Hyaline to light yellow.

OPERCULUM: Distinct.

CONTENTS: Yolk mass.

ABOPERCULAR PROCESS PRESENT.



ADULT

SIZE: Up to 30 meters.

COLOR: Ivory.

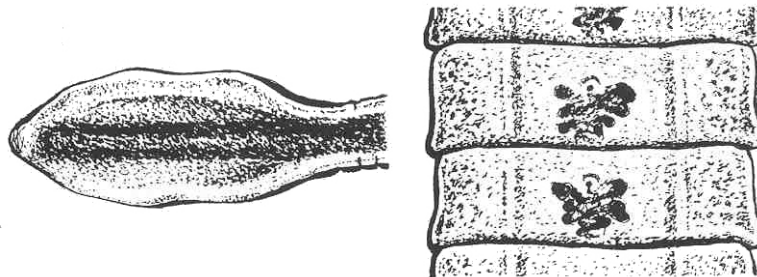
SCOLEX

SIZE: 2.5 x 1.0

mm.

SHAPE: Elliptical, spoon-shaped, almond-shape, spatulate.

SUCKERS: longitudinal slit-like grooves (two).



PROGLOTTID

SIZE: 2 to 4 mm by 10 to 12 mm.

SHAPE: Rectangular, broader than long.

GENITAL PORE: Single, ventral.

UTERUS: Rosette-shape (highly visible).

OVARIES: Bilobed.

TESTES: Minute spherical.

Figure 3-53. Stages of Diphyllobothrium latum.

ORGANISM 2--Spirometra species

Organisms (plerocercoid larvae) of the genus Spirometra and also other species of Diphyllbothrium, parasites of cats and other mammals which are unable to mature in an abnormal host (man), are responsible for the disease known as sparganosis. Infections are initiated when man swallows infected copepods in drinking water which then develop into the sparganum; they may be initiated when fish, amphibians (frogs, tadpoles) or snakes are consumed raw, transferring the sparganum larva; or they may be introduced when the flesh of frogs or snakes is used as a poultice applied to a lesion or wound. As the sparganum larvae localize in the abnormal site, they cause a painful inflammatory reaction in adjacent tissues. Depending upon the site, these organisms may cause intense and serious disease processes, particularly in certain species which seem to proliferate by budding or splitting and result in many individual larvae. Diagnosis is made by recognition of larval forms from tissue biopsies.

GENERAL CHARACTERISTICS

COMMON NAME: Sparganosis.

GEOGRAPHICAL DISTRIBUTION: Worldwide.

PATHOGENESIS: Inflammatory edema and necrosis of adjacent tissues; conjunctivitis; ocular inflammation; eosinophilia.

HABITAT: Small intestine of cats, dogs, tissues of man.

INTERMEDIATE HOST

FIRST: Copepod.

SECOND: Frogs, tadpoles, snakes.

ABNORMAL HOST: Man.

INFECTIVE FORM: Plerocercoid larva (sparganum).

MODE OF INFECTION: Poultices, ingestion.

SPECIMEN OF CHOICE: Biopsy.

Figure 3-54. Information on Spirometra.

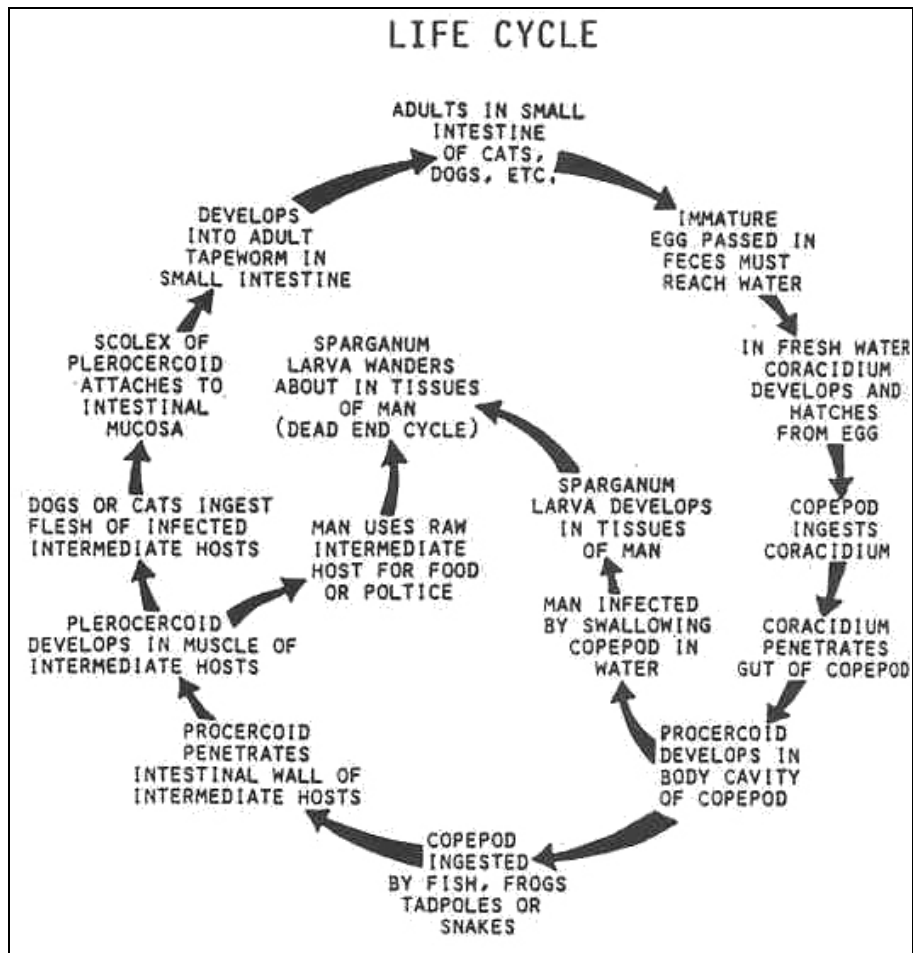


Figure 3-55. Life cycle of Spirometra species.

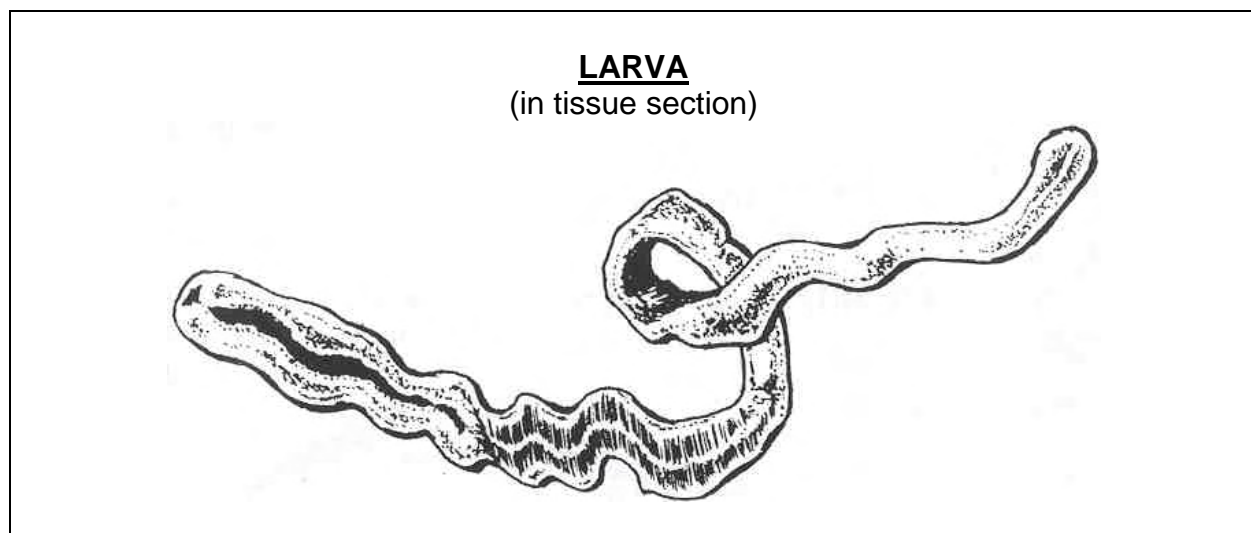


Figure 3-56. Spirometra larva.

ORGANISM 3--Taeniarhynchus saginatus

GENERAL CHARACTERISTICS

COMMON NAME: Beef tapeworm.

GEOGRAPHICAL DISTRIBUTION: Worldwide.

PATHOGENESIS: Frequently asymptomatic; appendiceal mucosal lesions with secondary appendicitis, rare intestinal obstruction; moderate eosinophilia.

HABITAT: Small intestines.

INTERMEDIATE HOST: Usually herbivores, mainly cattle.

RESERVOIR HOST: Man is the only basic definitive host.

INFECTIVE FORM: Cysticercus larva.

MODE OF INFECTION: Ingestion.

SPECIMEN OF CHOICE: Feces.

Figure 3-57. Information on Taeniarhynchus saginatus.

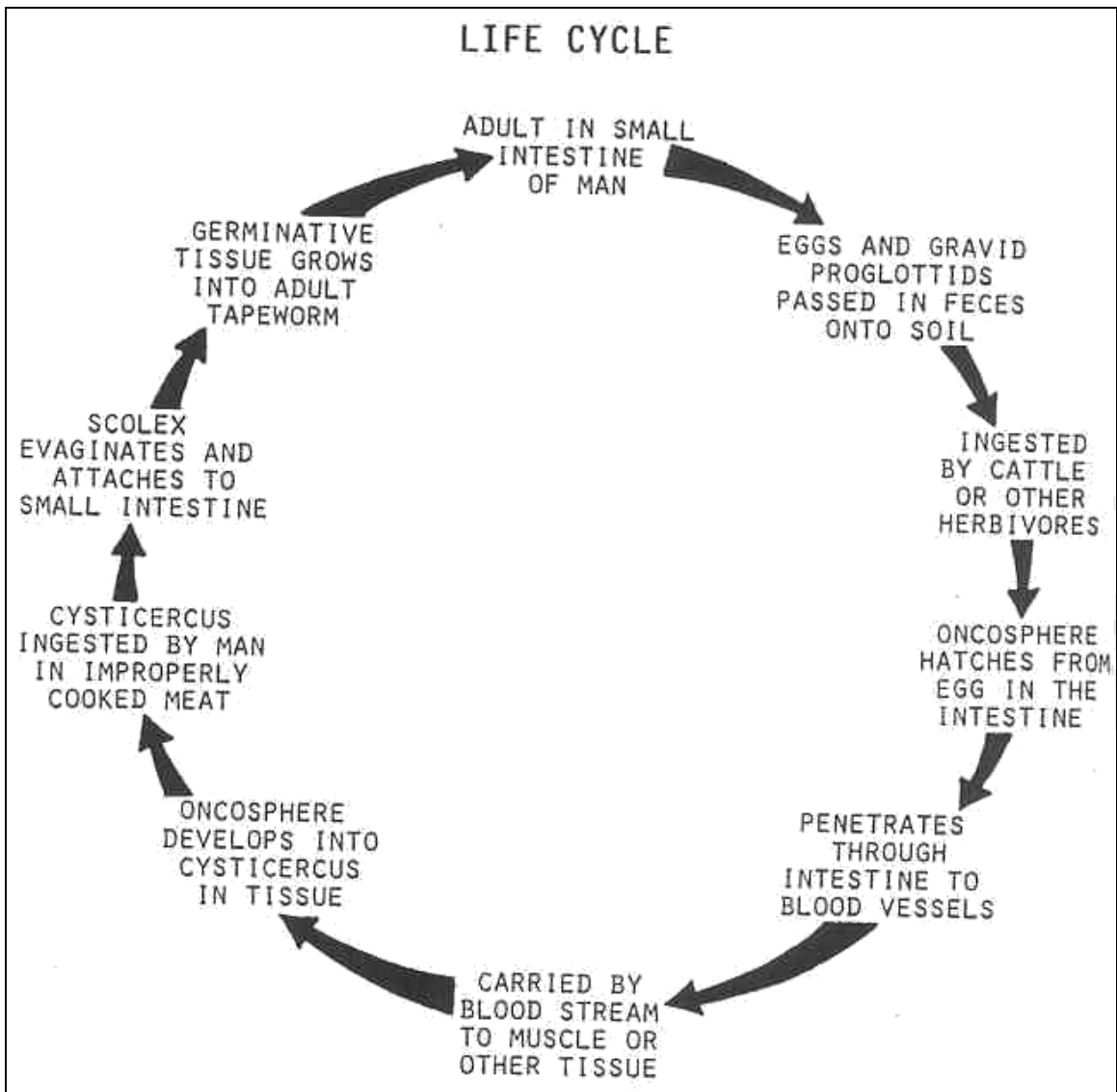


Figure 3-58. Life cycle of Taeniarhynchus saginatus.

Taeniarhynchus saginatus

OVA

SIZE: 30 to 40 μ (small to medium).

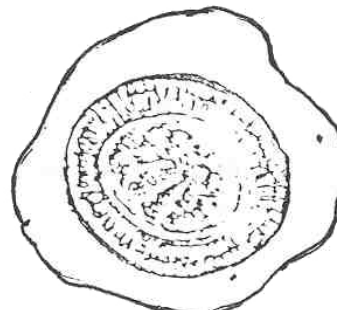
SHAPE: Ovoid to round.

COLOR: Brown.

OPERCULUM: Absent.

Contents: Hexacanth oncosphere.

MISCELLANEOUS: Embryophore with double layer and a radially striated outer layer.



ADULT

SIZE: 5 to 10 meters.

COLOR: Ivory.

SCOLEX

SIZE: 1 to 2 mm in diameter, large.

SHAPE: Round, unarmed.

PROGLOTTID

SIZE: 5 to 7 mm by 20 mm.

SHAPE: rectangular, longer than broad.

GENITAL PORE: Single, lateral.

UTERUS: Tubular when mature, gravid proglottid contains 15 to 30 branches.

OVARIES: Two, round.

TESTES: Minute, spherical.

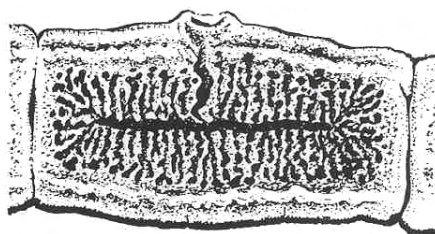
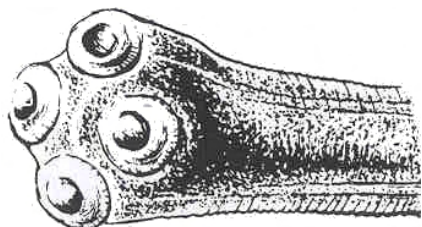


Figure 3-59. Stages of Taeniarhynchus saginatus.

ORGANISM 4--Taenia solium

GENERAL CHARACTERISTICS

COMMON NAME: Pork tapeworm.

GEOGRAPHICAL DISTRIBUTION: Worldwide.

PATHOGENESIS: Inflammation of intestinal mucosa, intestinal perforation, anemia, eosinophilia, toxemia, cysticercal lesions, fibrous capsules, CNS malfunction, chorioretinitis, blindness, lesions of brain, calcification in tissues.

HABITAT: Small intestines.

INTERMEDIATE HOST

USUALLY: Swine.

CYSTICERCOSIS: Man may become the intermediate host by ingesting the egg, in which case the cysticercus larva encysts in muscle.

RESERVOIR HOST: Man is the only definitive host.

INFECTIVE: Cysticercus larva.

MODE OF INFECTION: Ingestion.

SPECIMEN OF CHOICE: Feces.

Figure 3-60. Information on Taenia solium.

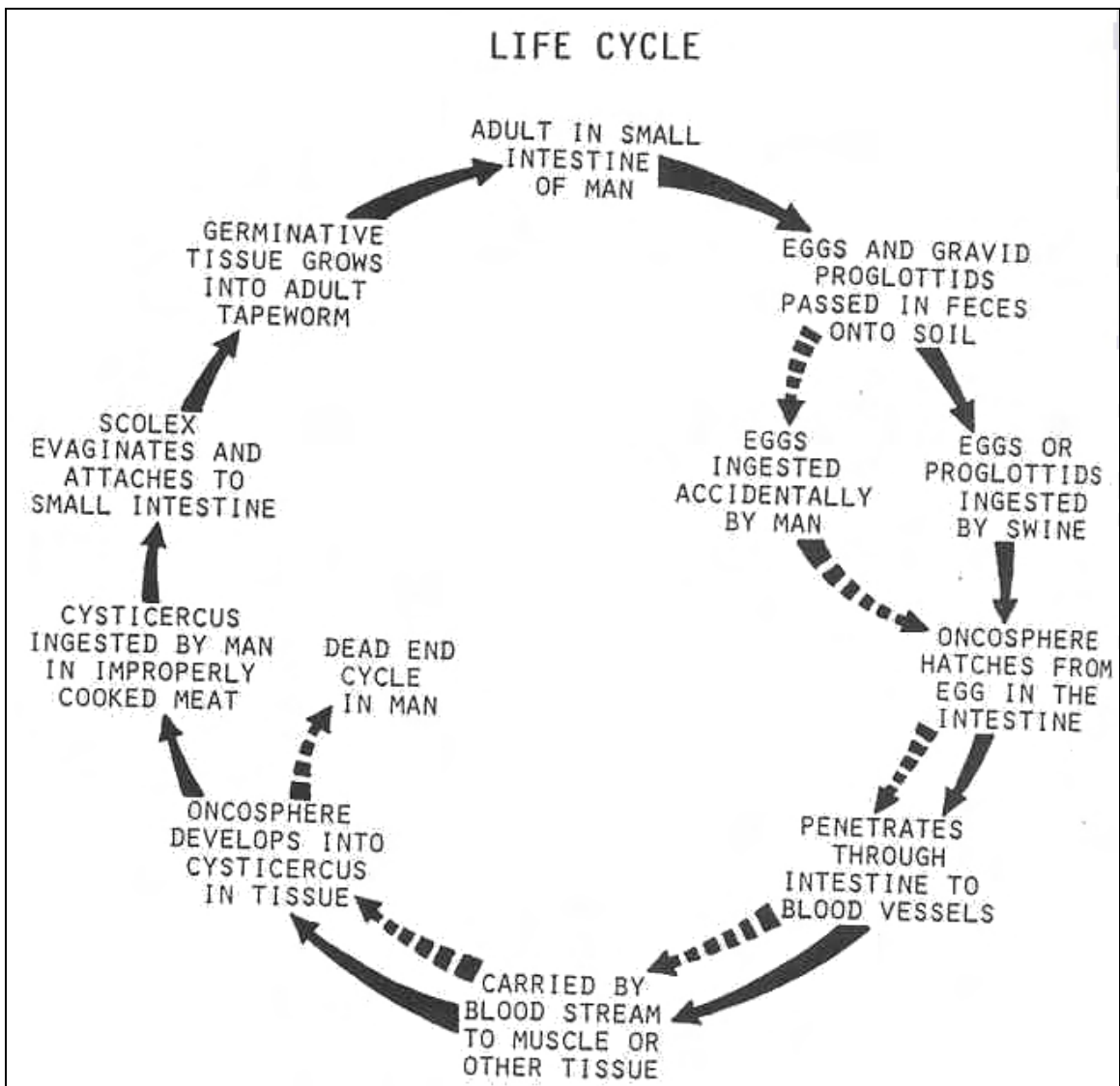


Figure 3-61. Life cycle of Taenia solium.

Taenia solium

OVA


SIZE: 30 to 40 μ (small to medium).

SHAPE: Ovoid to round.

COLOR: Brown.

OPERCULUM: Absent.

CONTENTS: Hexacanth oncosphere.

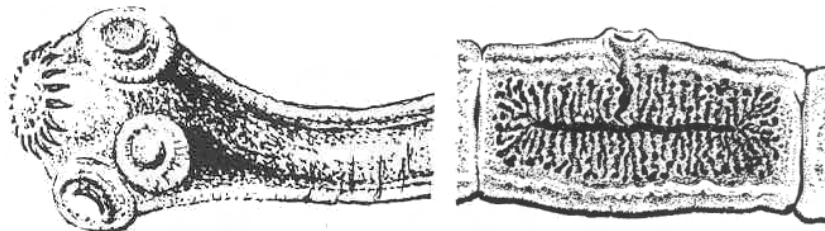


MISCELLANEOUS: Embryophore with double layer and a striated outer layer identical to the egg of T. saginatus (eggs should be reported as being taeinoid).

ADULT

SIZE: 2 to 7 meters.

COLOR: Ivory.



SCOLEX

SIZE: About 1 mm, large.

SHAPE: Round.

ROSTELLUM: Armed with alternating circles of large and small hooklets (22-32).

PROGLOTTID

SIZE: 4 to 7 mm by 12 mm.

SHAPE: Rectangular, longer than broad.

GENITAL PORE: Single, lateral.

UTERUS: Tubular when mature, gravid. proglottid contains 7 to 13 lateral uterine branches on one side of the main stem.

OVARIES: Two round.

TESTES: Minute, spherical.

Figure 3-62. Stages of Taenia solium.

ORGANISM 5--Hymenolepis nana

GENERAL CHARACTERISTICS

COMMON NAME: Dwarf tapeworm.

GEOGRAPHICAL DISTRIBUTION: Worldwide.

PATHOGENESIS: Often asymptomatic, variable enteritis, secondary anemia, eosinophilia.

HABITAT--Small intestines.

INTERMEDIATE HOST: Insects or none (autoinfective).

RESERVOIR HOST: Rodents.

INFECTIVE FORM: Cysticercoid larva.

MODE OF INFECTION: Ingestion.

SPECIMEN OF CHOICE: Feces.

Figure 3-63. Information on Hymenolepis nana.

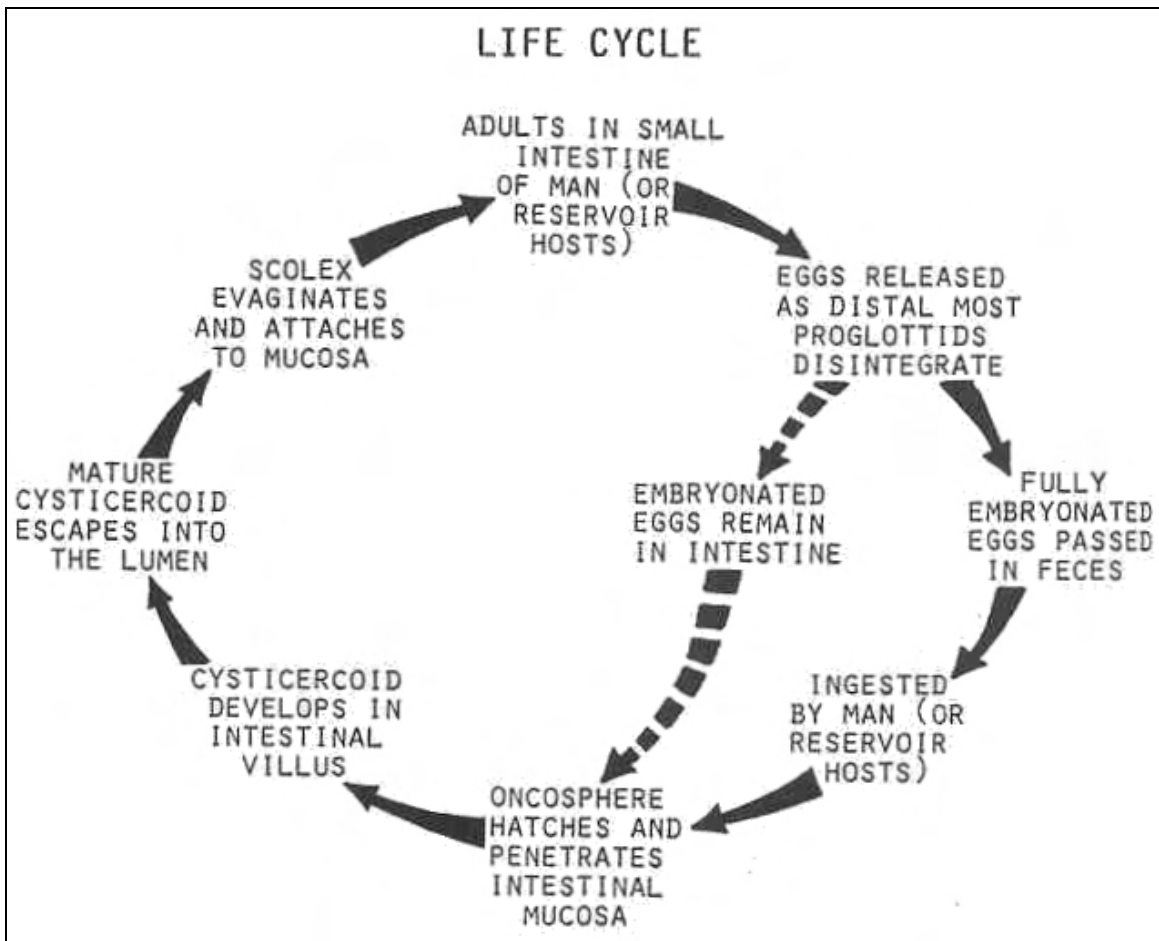


Figure 3-64. Life cycle of Hymenolepis nana.

Hymenolepis nana

OVA

SIZE: 35 x 45 μ (medium).

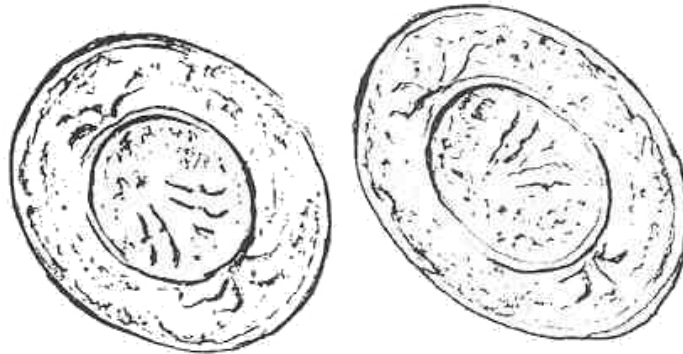
SHAPE: Round to ovoid.

COLOR: Hyaline.

OPERCULUM: Absent.

CONTENTS: Hexacanth oncosphere.

MISCELLANEOUS: 4 to 8 bipolar filaments.



ADULT

SIZE: 7 to 40 mm, inversely proportional to the number of parasites.

COLOR: Cream.

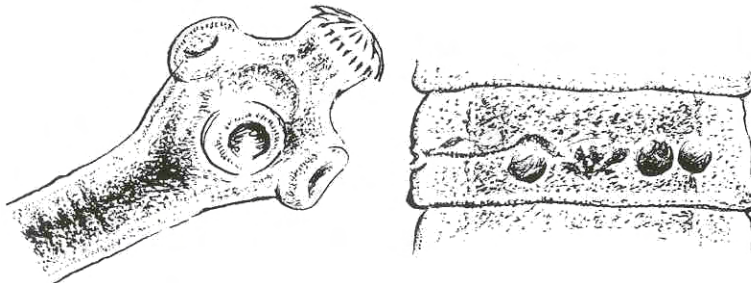
SCOLEX

SIZE: 0.3 mm in diameter (small).

SHAPE: Round.

ROSTELLUM:

Retractile, armed with a row of large hooklets.



PROGLOTTID

SIZE: Less than 1.0 mm wide.

SHAPE: Trapezoidal, four times wider than long.

GENITAL PORE: Single, lateral

UTERUS: Tubular.

OVARIES: Bilobed.

TESTES: Three, round, and large.

Figure 3-65. Stages of Hymenolepis nana.

ORGANISM 6--Hymenolepis diminuta

GENERAL CHARACTERISTICS

COMMON NAME: Rat tapeworm.

GEOGRAPHICAL DISTRIBUTION: Worldwide.

PATHOGENESIS: No significant pathology.

HABITAT: Small intestines.

INTERMEDIATE HOST: Insects (tenebrio molitor--grain beetle) or none (autoinfective).

RESERVOIR HOST: Rodents.

INFECTIVE FORM: Cysticercoid larva.

MODE OF ENTRY: Ingestion.

SPECIMEN SOURCE: Feces.

Figure 3-66. Information on Hymenolepis diminuta.

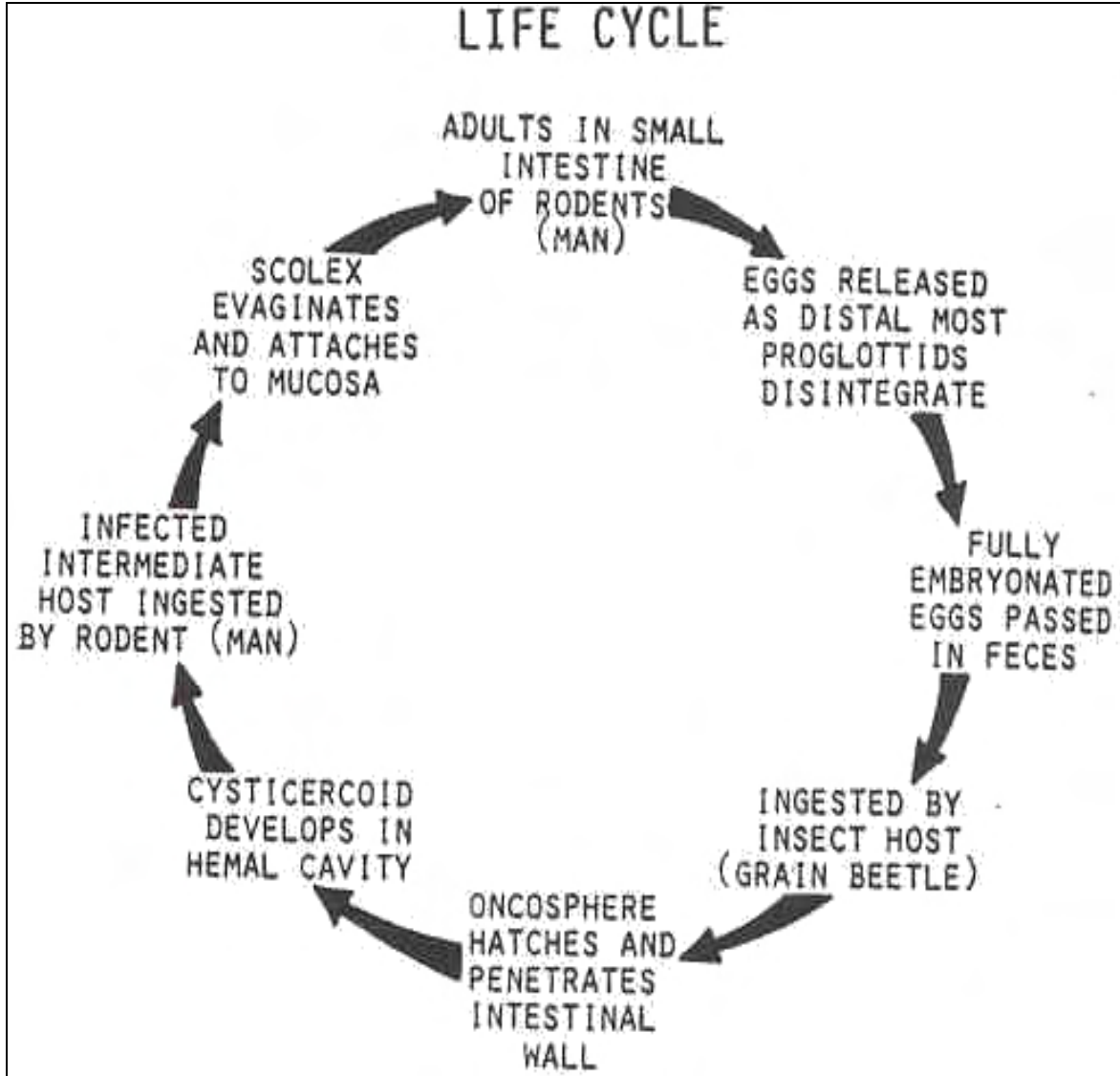


Figure 3-67. Life cycle of Hymenolepis diminuta.

Hymenolepis diminuta

OVA

SIZE: about 70 μ (medium to large).

SHAPE: Round to ovoid.

COLOR: Brown.

OPERCULUM: Absent.

CONTENTS: Hexacanth oncosphere.

MISCELLANEOUS: Sculptured outer shell, no bipolar filaments.

ADULT

SIZE: 20 to 60 cm.

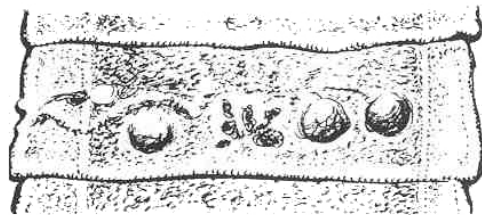
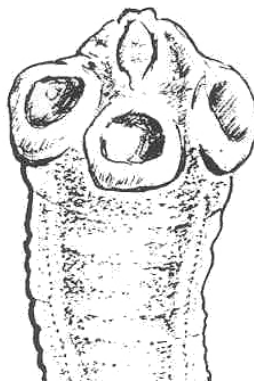
COLOR: Grayish white.

SCOLEX

SIZE: 0.5 by 0.8 mm
(small).

SHAPE: Club-
shaped.

ROSTELLUM: Rudimentary, with apical process, unarmed.



PROGLOTTID

SIZE: 2.5 mm wide.

SHAPE: Trapezoidal.

GENITAL PORE: Single, lateral.

UTERUS: Tubular.

OVARIES: Bilobed.

TESTES: Three, round, and large.

Figure 3-68. Stages of Hymenolepis diminuta.

ORGANISM 7--Dipylidium caninum

GENERAL CHARACTERISTICS

COMMON NAME: Dog tapeworm.

GEOGRAPHICAL DISTRIBUTION: Worldwide.

PATHOGENESIS: No significant pathology.

HABITAT: Small intestines.

INTERMEDIATE HOST: Fleas and lice.

RESERVOIR HOST: Dogs and cats.

INFECTIVE FORM: Cysticercoid larva.

MODE OF INFECTION: Ingestion.

SPECIMEN SOURCE: Feces.

Figure 3-69. Information on Dipylidium caninum.

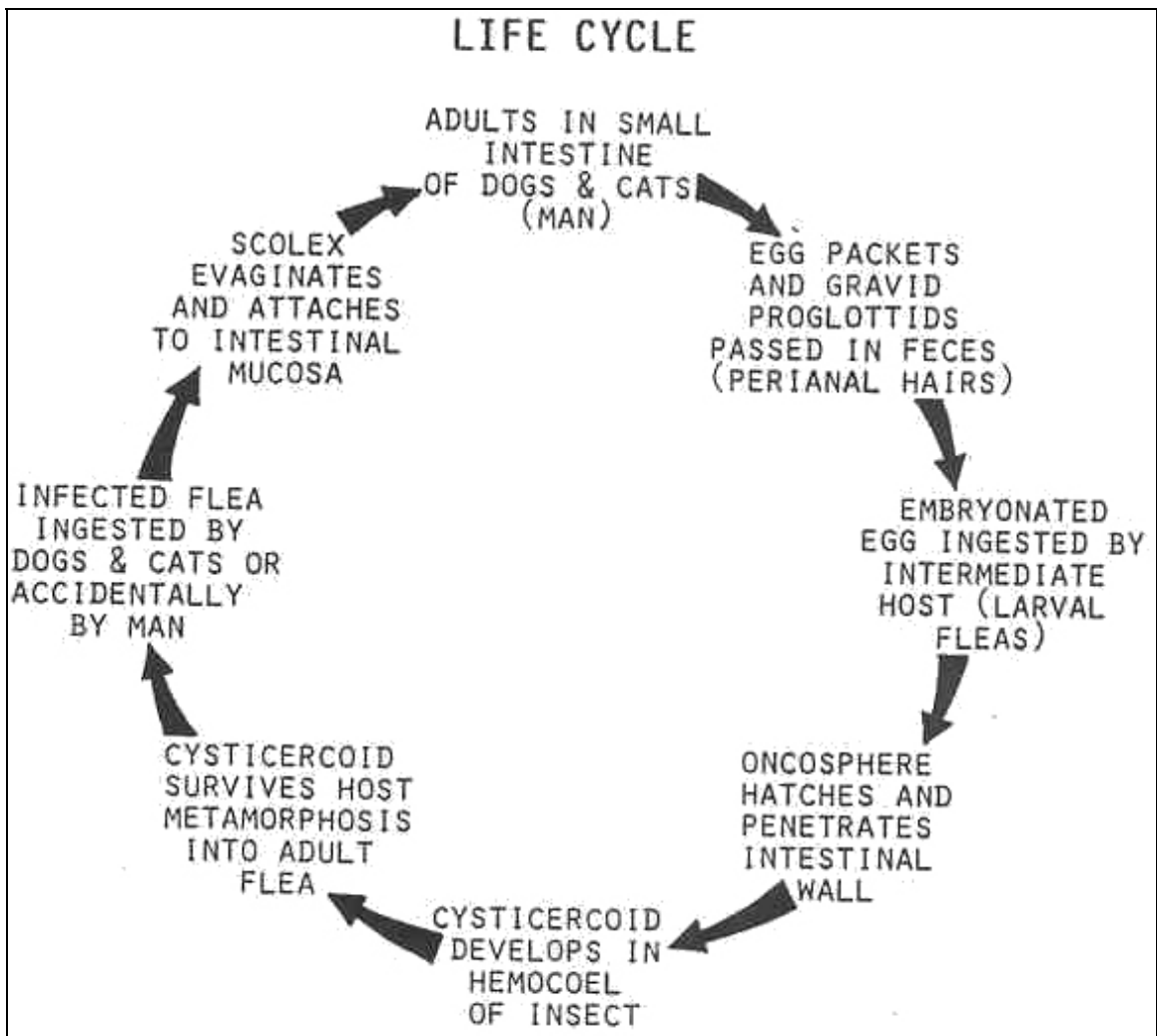


Figure 3-70. Life cycle of Dipylidium caninum.

Dipylidium caninum

OVA

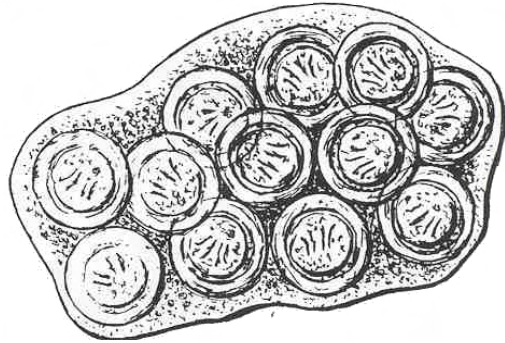
SIZE: About 35 μ (medium).

SHAPE: Round to ovoid.

COLOR: Light brown.

OPERCULUM: Absent.

CONTENTS: Hexacanth oncosphere.



Found in packets of 15 to 20 ova which are similar to T. saginatus but without the striated outer shell.

ADULT

SIZE: Up to 70 cm.


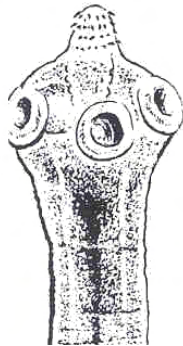
COLOR: Ivory.

SCOLEX

SIZE: 0.25 to 0.5 mm (small).

SHAPE: Club-shaped.

ROSTELLUM: armed with 3 to 7 rows of small hooklets.



PROGLOTTID

SIZE: 3.2 mm wide.

SHAPE: Longer than wide, "pumpkin seed" shape.

GENITAL PORE: Bilateral (two).

UTERUS: Paired with 16 to 20 radial branches each which disappear early; replaced by egg capsules.

OVARIES: Paired.

TESTES: Minute, spherical.

Figure 3-71. Stages of Dipylidium caninum.

ORGANISM 8--Echinococcus granulosus

GENERAL CHARACTERISTICS

COMMON NAME: Hydatid cyst tapeworm.

GEOGRAPHICAL DISTRIBUTION: Worldwide

PATHOGENESIS: Varies with location of cysts, inflammation reactions, fibrous cysts, pressure necrosis of adjacent tissue, hepatic cysts often in right lobe; cysts also in lung, kidneys, bones, brain, and other organs; secondary infections; eosinophilia.

HABITAT: Intestine of canines (adult worm); soft tissue and bones of intermediate host (larval stage).

INTERMEDIATE HOST: Man and herbivores, sheep.

RESERVOIR HOST: Carnivores (dogs).

INFECTIVE FORM: Egg for intermediate hosts; protoscolices for dogs or other canines.

MODE OF INFECTION: Ingestion.

SPECIMEN SOURCE: Dog feces or tissue (surgical).

Figure 3-72. Information on Echinococcus granulosus.

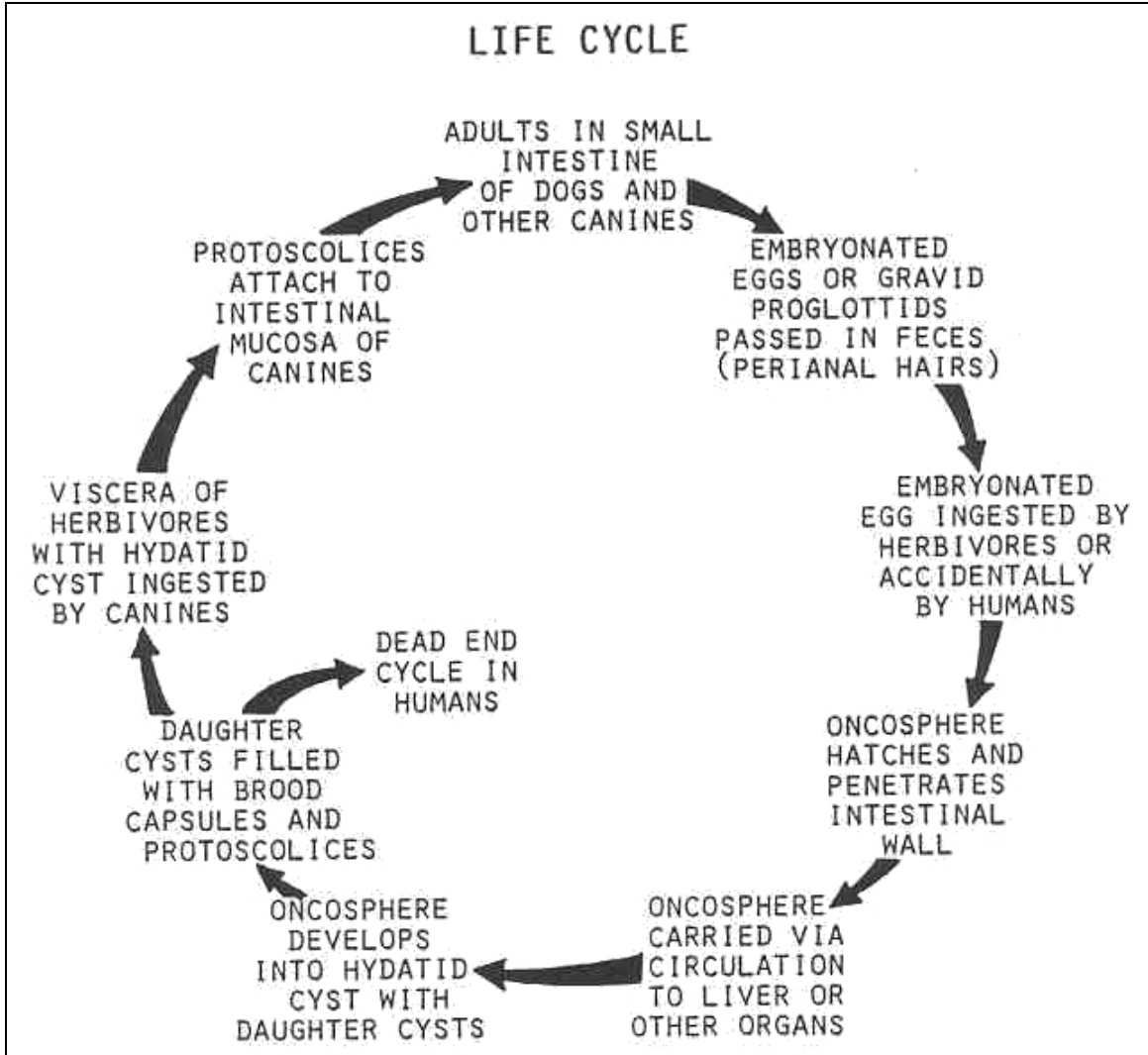


Figure 3-73. Life cycle of Echinococcus granulosus.

Echinococcus granulosus

OVA

SIZE: 30 to 40 μ .

SHAPE: Ovoid to round.

COLOR: Brown.

OPERCULUM: Absent.

CONTENTS: Hexacanth oncosphere.

MISCELLANEOUS: Embryophore with double layer and a striated outer layer; indistinguishable from taenioid ova.



ADULT

SIZE: 3 to 6 mm.

COLOR: Grayish white.

SCOLEX

SIZE: 0.3 mm.

SHAPE: Pyriform.

ROSTELLUM: Armed with 28 to 50 hooklets.

PROGLOTTID

USUALLY THREE: Immature, mature, and gravid.

SIZE: 1.3 to 2.5 mm by 0.5 mm.

SHAPE: Longer than broad.

GENITAL PORE: Lateral, single, equatorial.

UTERUS: Irregular longitudinal sac.

OVARIES: Two, oval.

TESTES: Minute, spherical (45 to 60).

Figure 3-74. Stages of Echinococcus granulosus. (continued)

Echinococcus granulosus adult (continued)

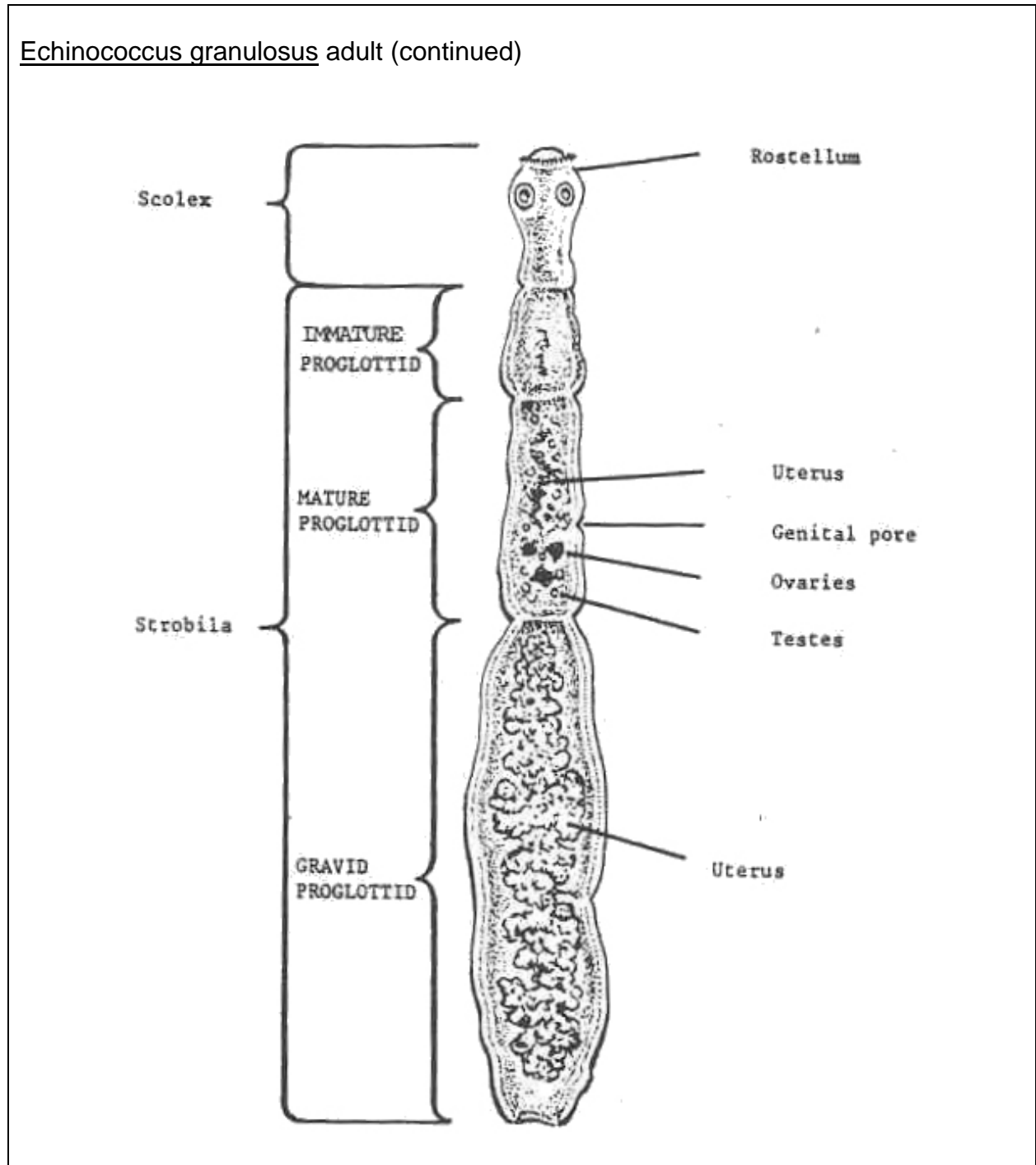


Figure 3-74. Stages of Echinococcus granulosus. (concluded)

ORGANISM 9--Echinococcus multilocularis

GENERAL CHARACTERISTICS

COMMON NAME: Hydatid cyst tapeworm.

GEOGRAPHICAL DISTRIBUTION: Northern Hemisphere, in cold or arctic climates.

PATHOGENESIS: Varies with location of cyst; inflammatory reactions; fibrous cysts; hemorrhages; cyst pressure; necrosis of adjacent tissues; hepatic cysts often in the right lobe; cysts also in lung, kidneys, bones, brain and other organs; may metastasize like a cancer; secondary infections; eosinophilia; grave prognosis.

HABITAT: Intestine of canines (adult worm); soft tissue and bones of intermediate hosts (larval stage).

INTERMEDIATE HOST: Man and mice, moles and herbivores.

RESERVOIR HOST: Carnivores (dogs).

INFECTIVE FORM: Egg for intermediate hosts; protoscolices for dogs or other canines.

MODE OF INFECTION: Ingestion.

SPECIMEN SOURCE: Dog feces or tissue (surgical).

Figure 3-75. Information on Echinococcus multilocularis

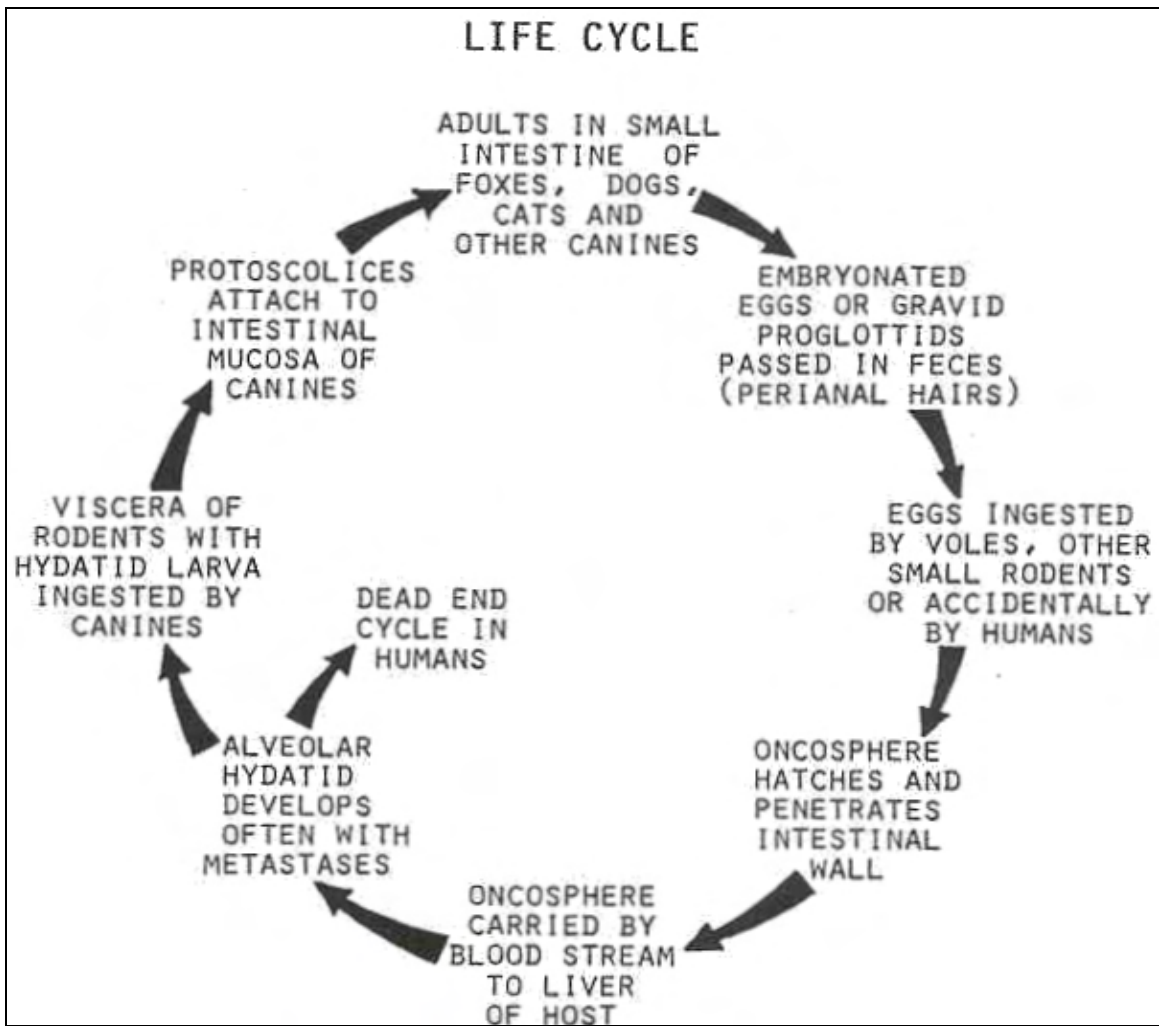


Figure 3-76. Life cycle of *Echinococcus multilocularis*.

Echinococcus multilocularis

OVA

SIZE: 30 to 40 μ .

SHAPE: Ovoid to round.

COLOR: Brown.

OPERCULUM: Absent.

CONTENTS: Hexacanth oncosphere.

MISCELLANEOUS: Embryophore with double layer and a striated outer layer; indistinguishable from taenioid ova.



ADULT

SIZE: 1.2 to 3.7 mm by 0.3 mm.

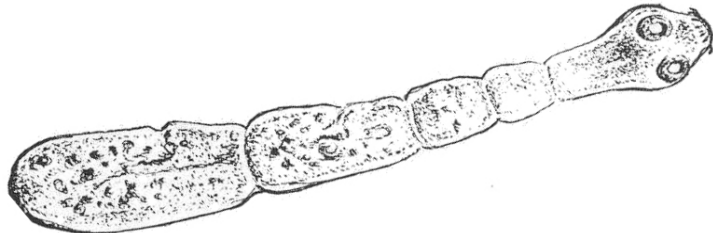
COLOR: Ivory.

SCOLEX

SIZE: 0.1 mm.

SHAPE: Pyriform.

ROSTELLUM: Armed with 30 to 36 hooklets.



PROGLOTTID

USUALLY THREE: immature, mature, and gravid.

SIZE: 0.1 mm by 0.4 mm.

SHAPE: Longer than broad.

GENITAL PORE: Lateral; preequatorial.

UTERUS: Longitudinal sac.

OVARIES: Two, oval.

TESTES: Minute, spherical (15 to 30).

Figure 3-77. Stages of Echinococcus multilocularis (continued).

Echinococcus multilocularis

UNILOCULAR CYST

CHARACTERISTIC OF E. granulosus

SIZE: Up to 200 mm.

CYST WALL: Limiting membrane.

THICK OUTER: Laminated acellular layer.

THIN INNER: Nucleated germinal layer.

PROTOSCOLICES: Miniature invaginated scolices on germinal layer of cyst wall.

BROOD CAPSULES: Formed from germinal layer; contain protoscolices.

DAUGHTER CYSTS: Replica of mother cyst, formed as germinal cells penetrate laminated layer; contain protoscolices and brood capsules (rarely seen with this organism).

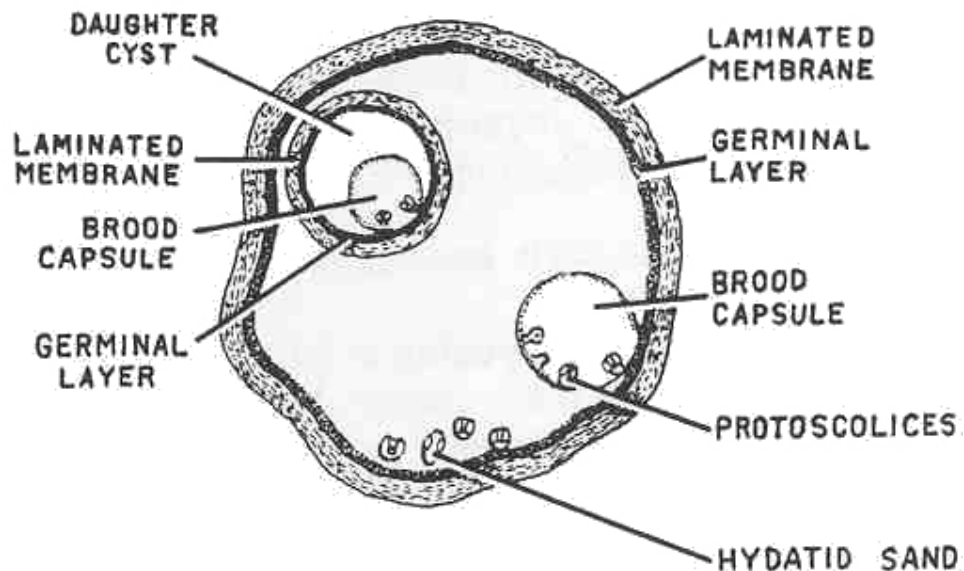


Figure 3-77. Stages of Echinococcus multilocularis (continued).

Echinococcus multilocularis

MULTILOCULAR CYST

CHARACTERISTIC OF E. multilocularis

SIZE: Usually poorly defined.

CYST WALL: Unlimiting membrane.

THIN OUTERvOutgrowing processes of germinal cells.

PROTOSCOLICES: Miniature invaginated scolices; formed in fluid-filled pockets; few in number in human infections.

BROOD CAPSULES: Absent.

DAUGHTER CYSTS: Replica of mother cyst, formed as alveolar pockets separate from the cyst wall; numerous in number and frequency; direct metastases.

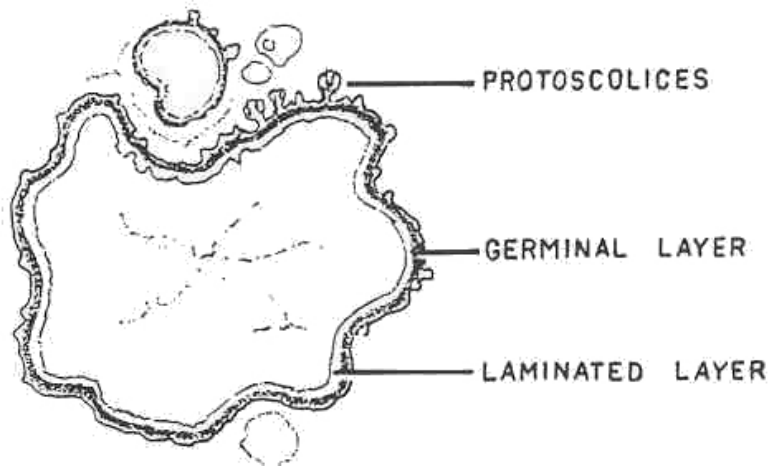


Figure 3-77. Stages of Echinococcus multilocularis (concluded).

Continue with Exercises

EXERCISES, LESSON 3

INSTRUCTIONS: Answer the following exercises by marking the lettered response that best answers the exercise, by completing the incomplete statement, or by writing the answer in the space provided at the end of the exercise.

After you have completed all the exercises, turn to "Solutions to Exercises" at the end of the lesson and check your answers. For each exercise answered incorrectly, reread the material referenced with the solution.

1. The definitive host for Taeniarhynchus saginatus is/are:
 - a. Man.
 - b. Piscivores.
 - c. Rodents.
 - d. Carnivores.

2. The common name for members of the Class Cestoda is:
 - a. Blood fluke.
 - b. Fluke.
 - c. Roundworm.
 - d. Tapeworm.

3. What is the habitat of Schistosoma haematobium?
 - a. Venules surrounding the small intestines.
 - b. Small intestine.
 - c. Liver.
 - d. Venules surrounding urinary bladder.

4. If you recover a scolex which is armed and has four round suckers, you would report:
- a. Taeniarhynchus saginatus.
 - b. Taenia solium.
 - c. Diphyllobothrium latum.
 - d. None of the above.
5. The subclass of flukes which contains members parasitic to humans is:
- a. Monogenea.
 - b. Digenea.
 - c. Aspidobothria.
 - d. Prosostomatea.
6. The structure in which the internal organs of Platyhelminthes are embedded is the:
- a. Flame cell.
 - b. Ganglion.
 - c. Parenchyma.
 - d. Proglottid.
7. Members of the Class Cestoda have a highly developed _____system.
- a. Digestive.
 - b. Respiratory.
 - c. Reproductive.
 - d. Muscular.

8. The specimen of choice for recovery of Paragonimus westermani is:
- Lung biopsy.
 - Urine.
 - Tissue.
 - Sputum.
9. The adult form of Fasciola hepatica is distinguished by:
- Large size.
 - A prominent cephalic cone.
 - Highly branched digestive ceca.
 - All of the above.
10. The form of Echinococcus multilocularis which is responsible for infecting man is the:
- Hydatid larva.
 - Ovum.
 - Protoscolex.
 - Adult.
11. Which of the following structures is helpful when identifying ova of Opisthorchis sinensis?
- Thickening of the abopercular end.
 - Abopercular comma.
 - Operculated at the broadest end.
 - All of the above.

12. Which of the following terms is one of the general characteristics of flukes?
- a. Polyzoic.
 - b. Segmented.
 - c. Monozoic.
 - d. None of the above.
13. Clinical data reveals that _____ produces the most embolic eggs and more severe lesions in man.
- a. Schistosoma japonicum.
 - b. Avian Schistosoma.
 - c. Schistosoma mansoni.
 - d. Schistosoma haematobium.
14. Infections of Schistosoma mansoni are acquired by:
- a. Ingestion of the mature egg.
 - b. Consumption of infected fish.
 - c. Active penetration of the cercaria larva.
 - d. Drinking water containing metacercaria larva.
15. Second intermediate hosts of the Opisthorchis species are:
- a. Pigs.
 - b. Aquatic plants.
 - c. Crabs and crayfish.
 - d. Fish.

16. The testes of Dicrocoelium dendriticum are:
- Highly dendritic.
 - In the posterior half of the body.
 - In the anterior half of the body.
 - Tandem in position.
17. The adults of Fasciolopsis buski can be readily distinguished from Fasciola hepatica by:
- The undulating ceca.
 - The lack of a cephalic cone.
 - The flushy color of the body.
 - All of the above.
18. What is the habitat of Metagonimus yokogawai?
- Liver.
 - Small intestine.
 - Lungs.
 - Large intestine.
19. Which of the following flukes has an off-set gonotyl as one of the distinguishing characteristics?
- Schistosoma species.
 - Heterophyes heterophyes.
 - Dicrocoelium dendriticum.
 - Metagonimus yokogawai.

20. Hogs and the Napu mouse deer are the reservoir hosts for:
- Paragonimus westermani.
 - Opisthorchis sinensis.
 - Gastrodiscoides hominis.
 - Echinostoma species.
21. The terminal (distal) segments of a tapeworm are called:
- Gravid proglottids.
 - Gonopores.
 - Mature proglottids.
 - Strobila.
22. The infective form of Diphyllobothrium latum ingested with improperly cooked fish is the:
- Plerocercoid.
 - Cysticercoid.
 - Procercoid.
 - Cysticercus.
23. The scolex of Hymenolepis nana could be described as being:
- Armed with a row of hooklets on a retractile rostellum.
 - Unarmed with an apical process.
 - Armed with 3-7 rows of hooklets.
 - Unarmed with no rostellum.

24. Which of the organisms listed below is the rat tapeworm?
- a. Diphyllobothrium latum.
 - b. Hymenolepis diminuta.
 - c. Dipylidium caninum.
 - d. Hymenolepis nana.
25. Egg packets containing 15 to 20 eggs are significant for:
- a. Echinococcus granulosus.
 - b. Dipylidium caninum.
 - c. Spirometra species.
 - d. Diphyllobothrium latum.
26. The specimen source for the recovery of Echinococcus species is:
- a. Canine feces.
 - b. Bone marrow.
 - c. Tissue biopsies.
 - d. All of the above.

Check Your Answers on Next Page

SOLUTIONS TO EXERCISES, LESSON 3

1. a (para 3-10; org 3)
2. d (para 3-8)
3. d (para 3-7; org 3)
4. b (para 3-10; org 4)
5. b (para 3-6)
6. c (para 3-2)
7. c (para 3-8)
8. d (para 3-7; org 4)
9. d (para 3-7; org 8)
10. b (para 3-10; org 9)
11. b (para 3-7; org 5;)
12. c (para 3-5)
13. a (para 3-7; org 1)
14. c (para 3-7; org 2)
15. d (para 3-7; org 6)
16. c (para 3-7; org 7)
17. d (para 3-7; org 9)
18. b (para 3-7; org 10)
19. b (para 3-7; org 11)
20. c (para 3-7; org 12)
21. a (para 3-9; fig 3-36)
22. a (para 3-10; org 1)

- 23. a (para 3-10; org 5)
- 24. b (para 3-10; org 6)
- 25. b (para 3-10; org 7)
- 26. d (para 3-10; org 8 & 9)

End of Lesson 3

LESSON ASSIGNMENT

LESSON 4

Phylum Aschelminthes; Phylum Acanthocephelminthes; Arthropods and Vectors

LESSON ASSIGNMENT

Para 4-1 through 4-7.

LESSON OBJECTIVES

After completing this lesson, you should be able to:

- 4-1. Identify the general characteristics of members of Phylum Aschelminthes.
- 4-2. Identify the organism characteristics of members of Class Nematoda that are parasitic to human intestines.
- 4-3. Select a statement that best describes the life cycle of an intestinal nematode.
- 4-4. Identify the organism characteristics of tissue-dwelling Nematodes.
- 4-5. Select a statement that best describes the life cycle of a tissue dwelling Nematode.
- 4-6. Identify the organism characteristics of nematodes that are parasitic to human blood and tissue.
- 4-7. Select a statement that best describes the life cycle of a blood or tissue Nematode.
- 4-8. Identify the specimen of choice for recovery of specific Nematodes.
- 4-9. Identify the special techniques for recovery of specific Nematodes.
- 4-10. Identify general characteristics of members of Phylum Acanthocephelminthes.
- 4-11. Select a statement that best describes the life cycle of a pathogenic Acanthocephalan.
- 4-12. Identify the morphological characteristics of arthropod and vectors.

SUGGESTION

After completing the assignment, complete the exercises of this lesson. These exercises will help you to achieve the lesson objectives.

LESSON 4

PHYLUM ASCHELMINTHES; PHYLUM ACANTHOCEPHELMINTHES; ARTHROPODS AND VECTORS

Section I: PHYLUM ASCHELMINTHES

4-1. GENERAL COMMENTS

This phylum consists of thousands of free living and parasitic species. They are round with tapering ends and unsegmented. Members of this phylum have been found to be parasitic in nearly every type of organism and in every system of the body. All of the human parasitic round worms belong to the class Nematoda. The life cycle of nematodes varies from simple autoinfection to a complicated cycle that carries the larval organism through different systems of the host before arriving at the natural habitat. Reproduction is sexual and two organisms, one of each sex, are required (dioecious). The female is considerably larger than the male, and the males have curved tails and/or specialized copulatory organs that aid in grasping the female for copulation. The outer covering, the cuticle, is relatively impermeable, used for protection, and molting from one larval stage to another begins here. The digestive tract is complete and consists of a mouth, a specialized pharyngeal area, intestines, rectum, and an anus. These organisms possess a sophisticated osmoregulatory/excretory system based on ammonia waste that exits through the anus. Some species may have excretory pores and/or renette glands. The nervous system consists of two nerve rings (anterior and posterior) that lead to receptors (sense organs) for light, chemical, and mechanical stimulation, and a pair of longitudinal nerves located laterally.

NOTE: See figures 4-1 and 4-2.

4-2. NEMATODE GROUPS

Nematodes parasitic to man can be grouped according to life cycles, as intestinal nematodes, tissue dwelling nematodes, and blood and tissue nematodes. See figures 3-3 through 3-xx.

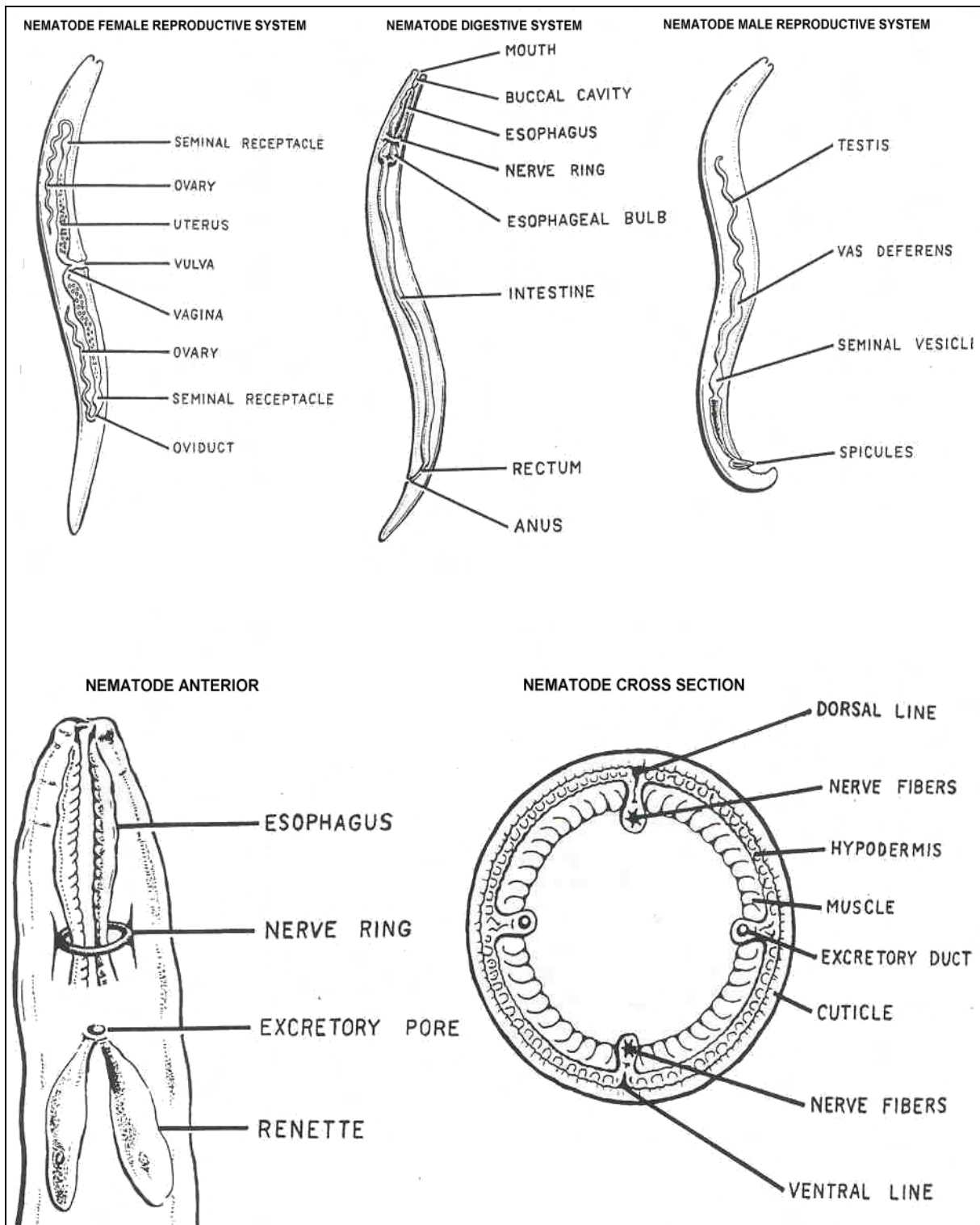


Figure 4-1. Typical nematode.

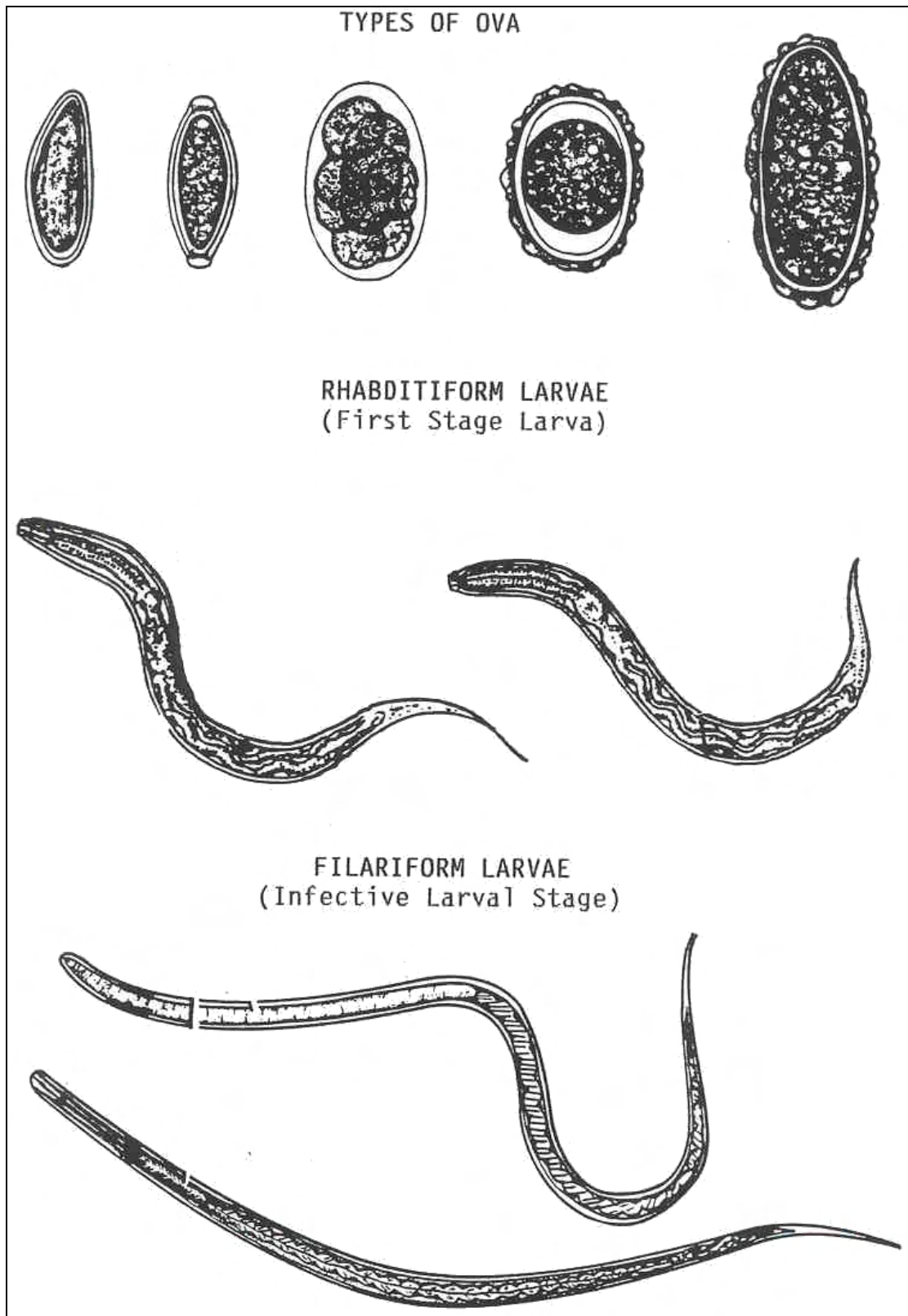


Figure 4-2. Nematode ova and larval stages.

a.. **Intestinal Nematodes.** See figures 4-3 through 4-26.

ORGANISM 1: Ascaris lumbricoides

COMMON NAME: Giant intestinal roundworm.

GEOGRAPHICAL DISTRIBUTION: Worldwide.

PREVALENCE: Most prevalent helminth infection, 25% of lumen helminthiasis.

PATHOGENESIS: Enteritis, inflammation, obstruction, toxicity, eosinophilia, hemorrhage, trauma by penetrating adults.

HABITAT: Small intestines.

INTERMEDIATE HOST: None.

RESERVOIR HOST: Swine.

INFECTIVE FORM: Embryonated egg.

MODE OF INFECTION: Ingestion.

SPECIMEN OF CHOICE: Feces.

Figure 4-3. Information on Ascaris lumbricoides.

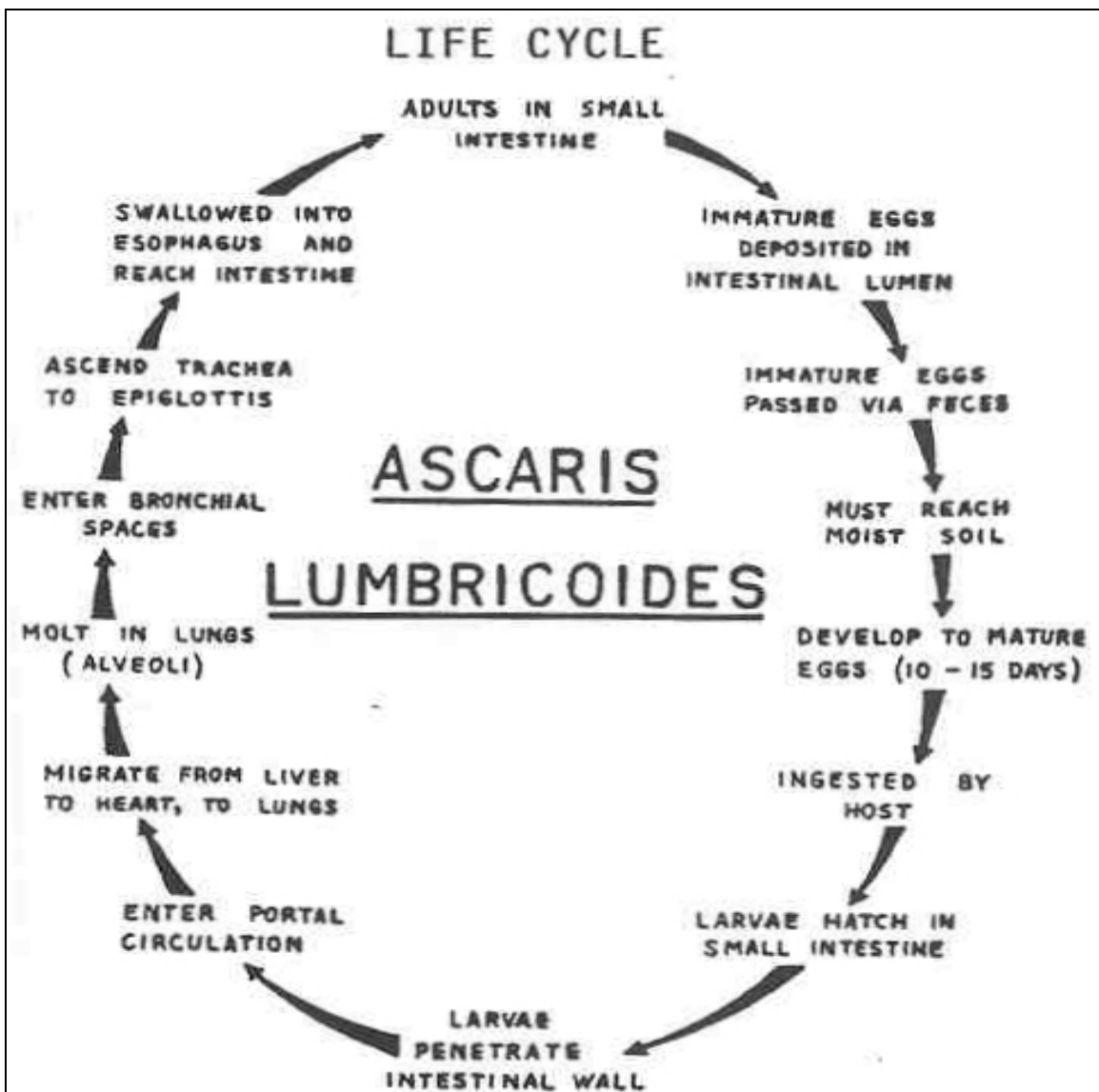


Figure 4-4. Life cycle of Ascaris lumbricoides.

Ascaris lumbricoides

OVA

DECORTICATED

SIZE: 35 x 50 μ .
SHAPE: Oval to round.
COLOR: Hyaline.
OPERCULUM: None.

CORTICATED

SIZE: 45 x 60 μ .
SHAPE: Oval, elongated, somewhat rectangular.
COLOR: Brown cortication, hyaline shell wall.
OPERCULUM: None.
CONTENT: Yolk mass.
FERTILIZED: Organized; pulled away from wall.
UNFERTILIZED: Disorganized; fills the shell.

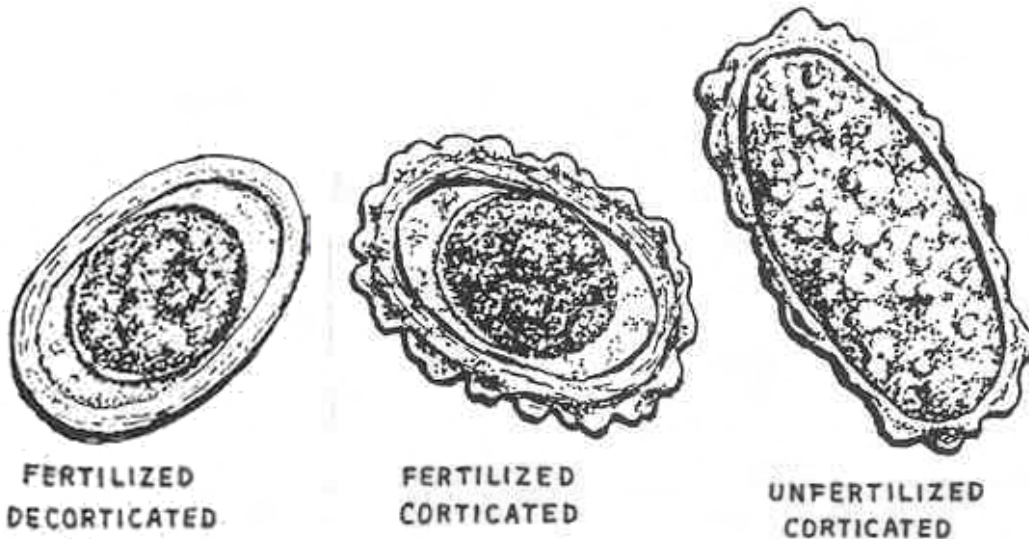


Figure 4-5. Stages of Ascaris lumbricoides. (continued).

Ascaris lumbricoides

ADULT

SIZE

MALE: 15 to 30 cm.

FEMALE: 20 to 35 cm.

SHAPE: Round and slender, male has curved tail.

COLOR: Creamy-white with a pinkish cast.

BUCCAL STRUCTURES: Three lips.

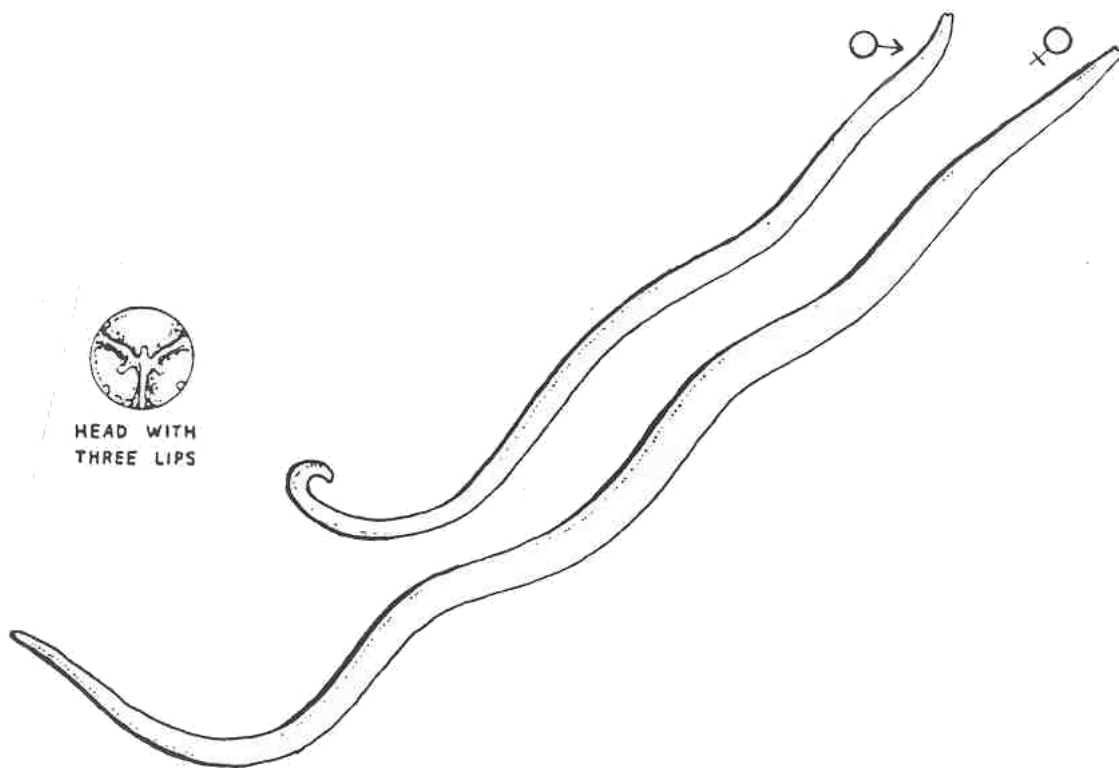


Figure 4-5. Stages of Ascaris lumbricoides. (concluded).

ORGANISM 2: Trichuris trichiura

GENERAL CHARACTERISTICS

COMMON NAME: Whipworm.

GEOGRAPHICAL DISTRIBUTION: Worldwide.

PATHOGENESIS: Eosinophilia, severe anemia, hemorrhage, rectal prolapse in extreme cases.

HABITAT: Large intestines, cecum.

INTERMEDIATE HOST: None.

RESERVOIR HOST: Monkey, swine.

INFECTIVE FORM: Embryonated egg.

MODE OF INFECTION: Ingestion.

SPECIMEN OF CHOICE: Feces.

Figure 4-6. Information on Trichuris trichiura.

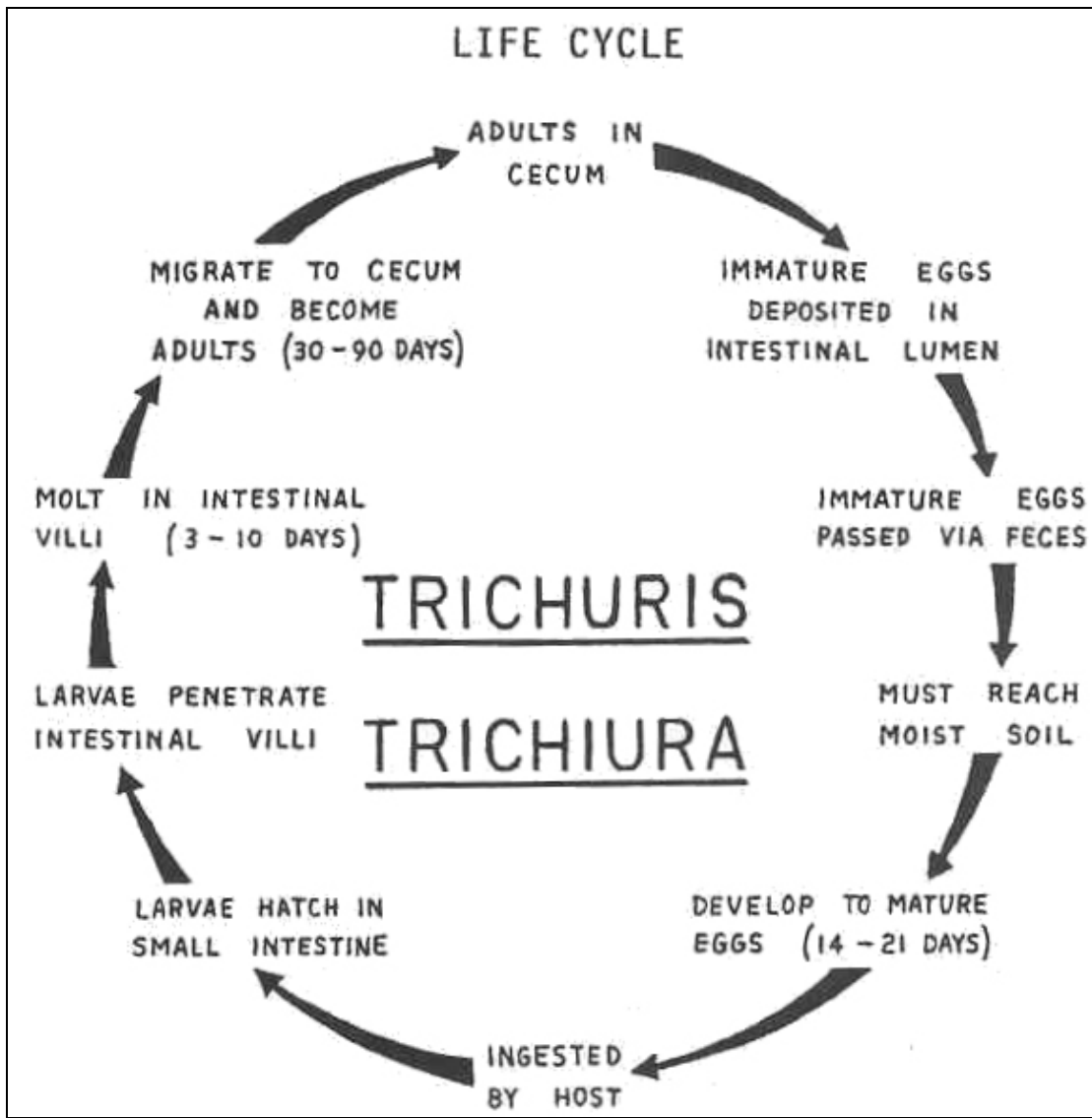


Figure 4-7. Life cycle of Trichuris trichiura.

Trichuris trichiura

OVA

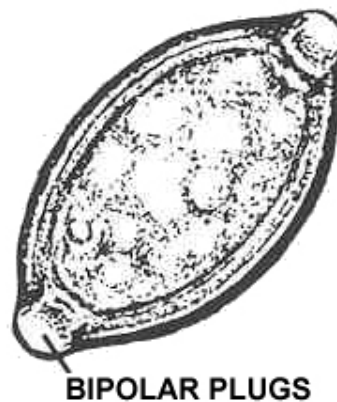
SIZE: 20 x 55 μ .

SHAPE: Football, barrel-shape with bipolar plugs.

COLOR: Golden brown.

OPERCULUM: Absent.

CONTENT: Yolk mass (rare larva seen).



ADULT

SIZE

MALE: 30 to 45 mm.

FEMALE: 35 to 50 mm.

SHAPE: Thick posterior and whip-like anterior.

COLOR: Flesh-colored.

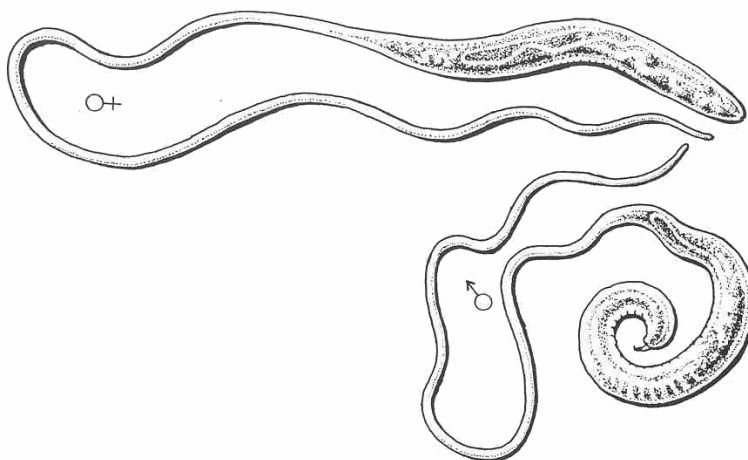


Figure 4-8. Stages of Trichuris trichiura.

ORGANISM 3: Enterobius vermicularis

GENERAL CHARACTERISTICS

COMMON NAME: Pinworm, seatworm.

GEOGRAPHICAL DISTRIBUTION: Worldwide.

PATHOGENESIS: Slight eosinophilia (4 to 12 percent); secondary infections, perianal irritations.

HABITAT: Large intestine, cecum.

INTERMEDIATE HOST: None.

RESERVOIR HOST: None known.

INFECTIVE FORM: Embryonated egg (Rhabditiform larva).

SPECIMEN SOURCE: Perianal swab or "scotch tape prep."

Figure 4-9. Information on Enterobius vermicularis.

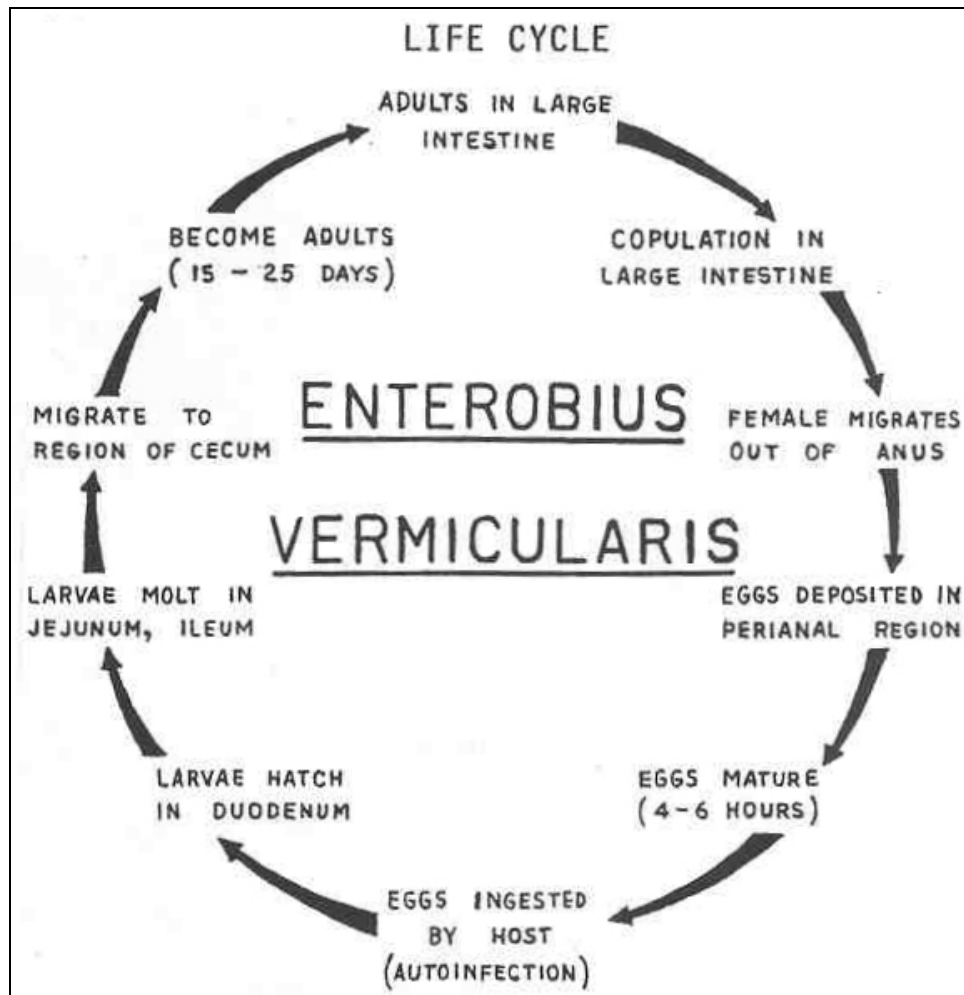


Figure 4-10. Life cycle of Enterobius vermicularis.

Enterobius vermicularis

OVA

SIZE: 25 x 55 μ .

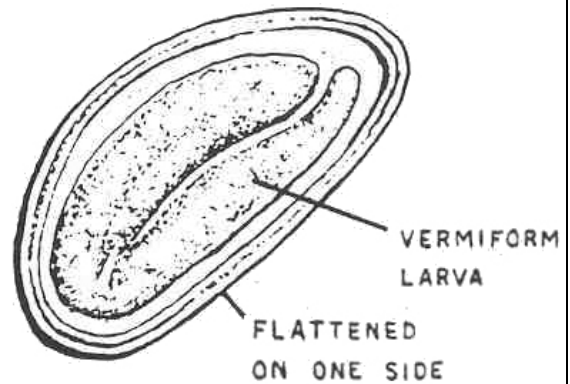
SHAPE: "D" shape (oval); one flattened side.

COLOR: Hyaline.

OPERCULUM: Absent.

CONTENT: First stage vermiform larva, may contain undeveloped larva known as tadpole larva.

SHELL WALL: Triple layer.



ADULT

SIZE

MALE: 2 to 5 mm.

FEMALE: 8 to 13 mm.

SHAPE: Sharply pointed tail in the female.

COLOR: White.

CEPHALIC ALAE: Wing-like structures.

ESOPHAGEAL BULB: Prominent.

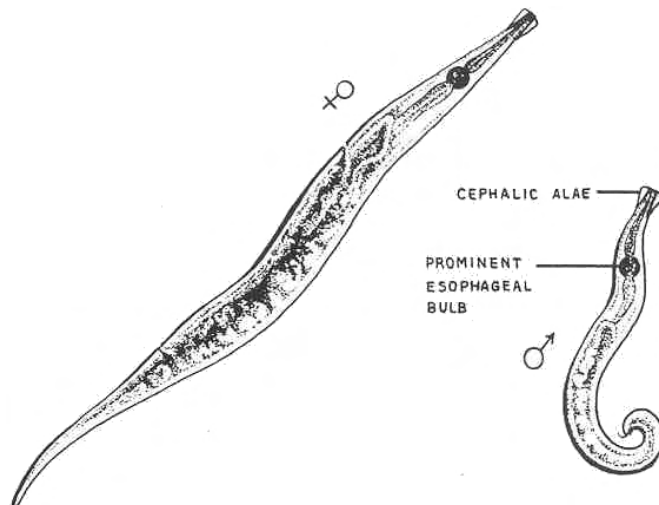


Figure 4-11. Stages of Enterobius vermicularis.

ORGANISM 4: Trichostrongylus species

GENERAL CHARACTERISTICS

COMMON NAME: None.

GEOGRAPHICAL DISTRIBUTION: Worldwide.

PATHOGENESIS: Inflammation of the intestinal mucosa and gallbladder in heavy infections; secondary anemia, transient eosinophilia; usually asymptomatic.

HABITAT: Small intestines.

INTERMEDIATE HOST: None.

RESERVOIR HOST: Dependant on the species.

INFECTIVE FORM: Semi-filariform larva.

MODE OF INFECTION: Ingestion.

SPECIMEN OF CHOICE: Feces.

Figure 4-12. Information on Trichostrongylus.

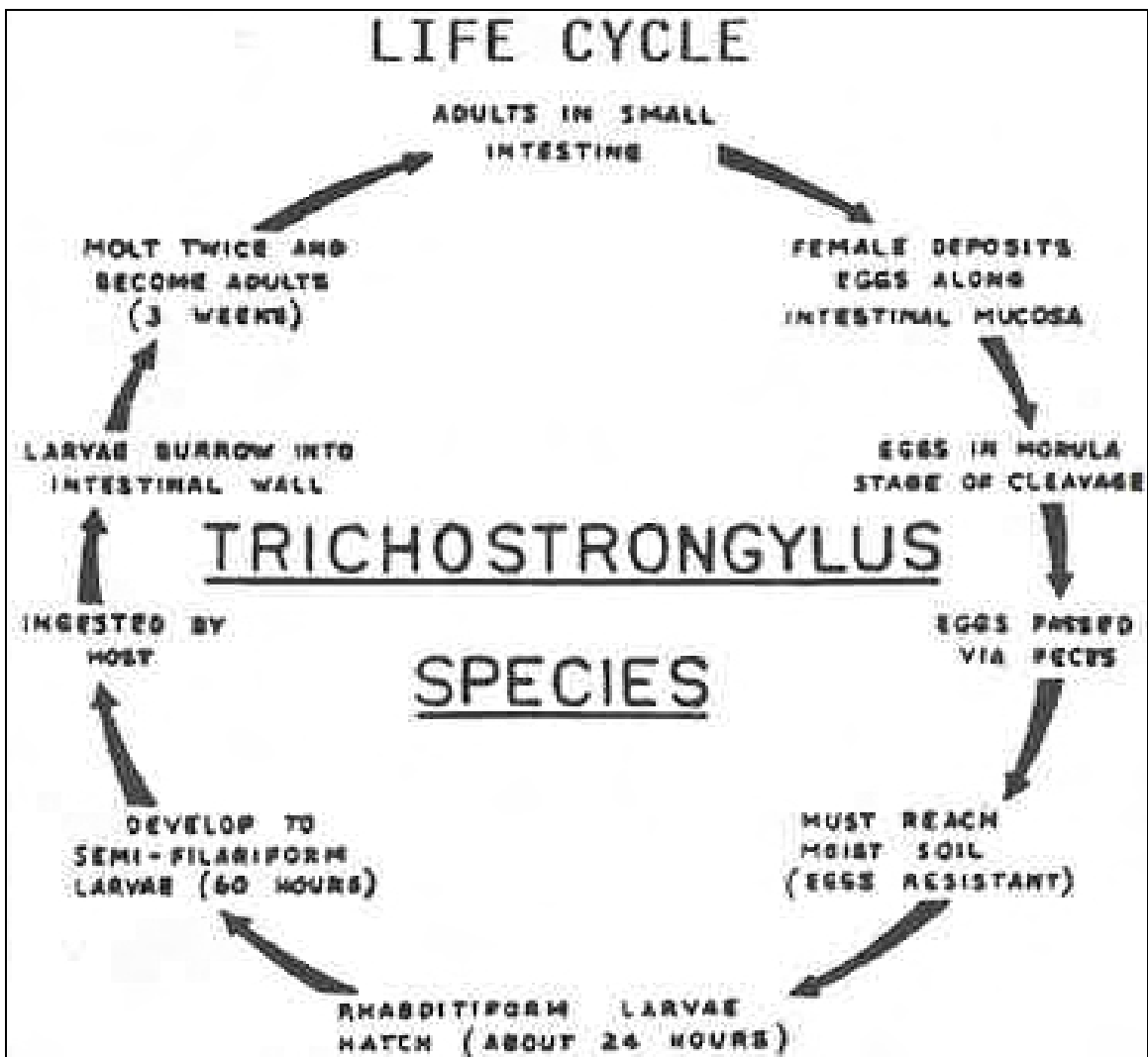


Figure 4-13. Life cycle of Trichostrongylus species.

Trichostrongylus species

OVA

SIZE: 40 x 90 μ .

SHAPE: Ellipsoidal, slightly pointed ends.

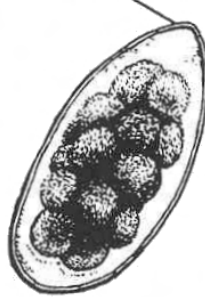
COLOR: Hyaline.

OPERCULUM: Absent.

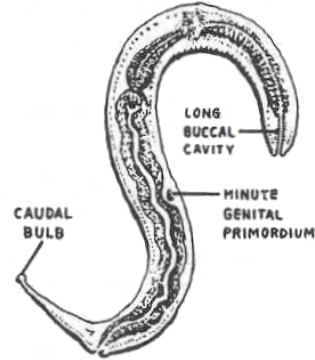
CONTENT: Yolk mass.

SHELL WALL: Thin, double.

SLIGHTLY POINTED END



RHABDITIFORM LARVA



ADULT

SIZE

MALE: 4 to 6 mm.

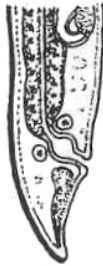FEMALE: 5 to 8 mm.

SHAPE: Round and slender.

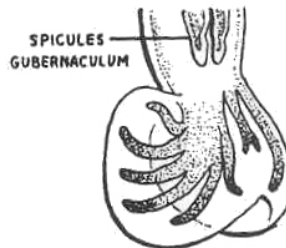
COLOR: Colorless.

BUCCAL STRUCTURES: Minute.

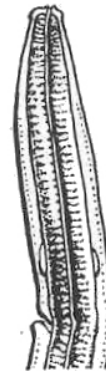
COPULATORY BURSA: Present.



POSTERIOR END - FEMALE



POSTERIOR END - MALE
WITH COPULATORY BURSA



ANTERIOR END WITH
VENTRAL NOTCH
(EXCRETORY PORE)

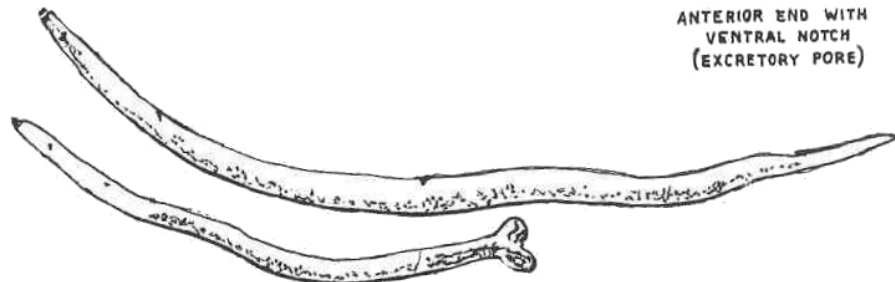


Figure 4-14. Stages of Trichostrongylus species.

ORGANISM 5: Capillaria philippinensis

GENERAL CHARACTERISTICS

COMMON NAME: None.

GEOGRAPHICAL DISTRIBUTION: Philippines, Thailand.

PATHOGENESIS: Persistent diarrhea, acute intestinal inflammation, malabsorption; tissue destruction; cardiac abnormalities.

HABITAT: Small intestines.

INTERMEDIATE HOST: Fish, none.

RESERVOIR HOST: Rodents.

INFECTIVE FORM: Filariform larva.

MODE OF INFECTION: Ingestion, autoinfective.

SPECIMEN OF CHOICE: Feces.

Figure 4-15. Information on Capillaria philippinensis.

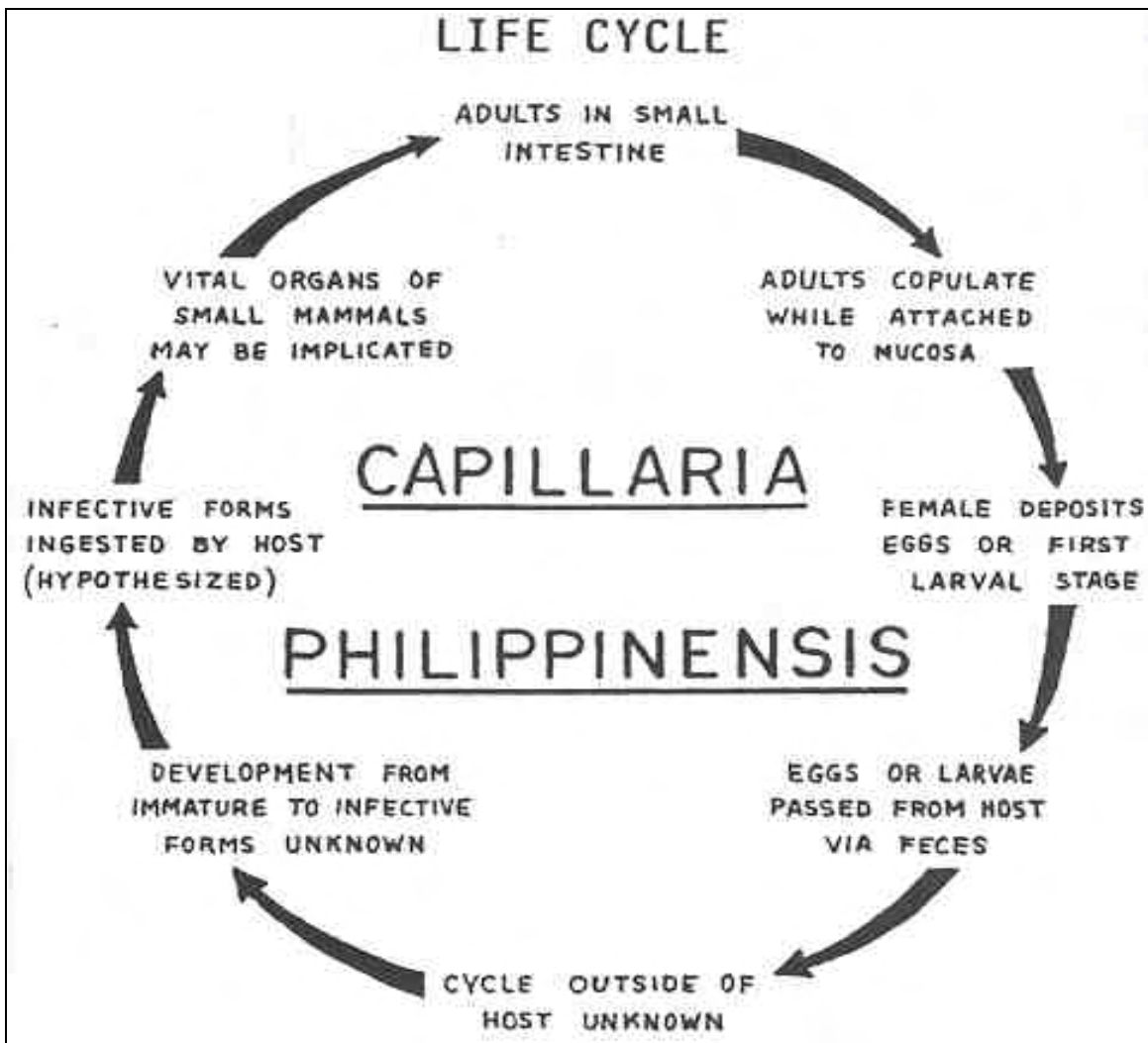


Figure 4-16. Life cycle of Capillaria philippinensis.

Capillaria philippinensis

OVA

SIZE: 20 x 45 μ .

SHAPE: Ovoid, irregular shape.

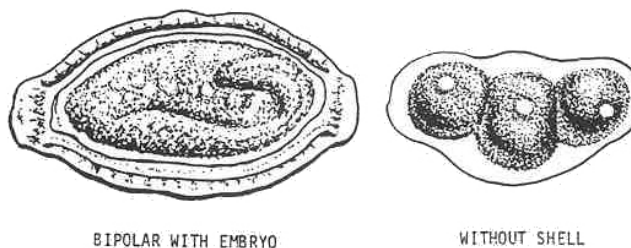
COLOR: Hyaline.

OPERCULUM: Absent.

CONTENT: Yolk mass, developing embryo, larva.

SHELL WALL: If present, thick or thin; with shallow pits.

BIPOLAR PLUGS: Flattened.



ADULT

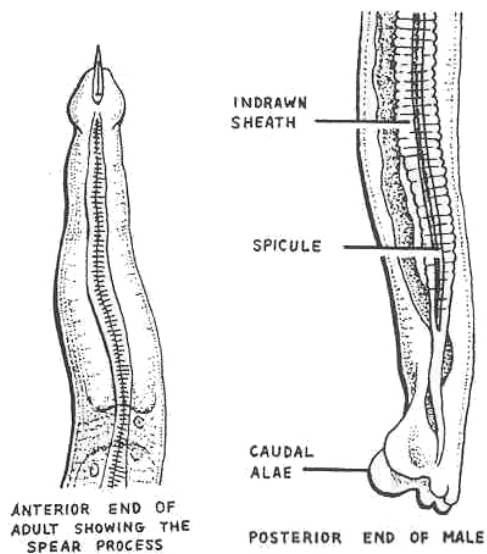
SIZE

MALE: About 2.5 mm.

FEMALE: About 3.5 mm.

SHAPE: Slender and round.

COLOR: Light yellow.



FREE LARVA

Bluntly rounded at both ends.
Conspicuous genital primordium.

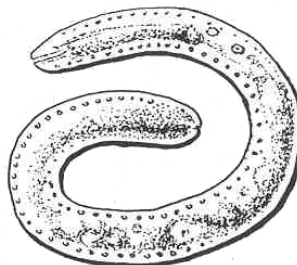


Figure 4-17. Stages of Capillaria philippinensis.

ORGANISM 6: Ancylostoma duodenale

GENERAL CHARACTERISTICS

COMMON NAME: Old world hookworm (archaic).

GEOGRAPHICAL DISTRIBUTION: Europe, Asia; becoming worldwide.

PATHOGENESIS: Lesions of intestinal mucosa, anemia (chronic nutritional deficiency type), eosinophilia, pneumonitis, erythema, dyspnea.

HABITAT: Small intestines.

INTERMEDIATE HOST: None.

RESERVOIR HOST: Hogs, dogs, cats, lions, tigers, and gorillas.

INFECTIVE FORM: Filariform larva.

MODE OF INFECTION: Penetration of the skin.

SPECIMEN OF CHOICE: Feces.

Figure 4-18. Information on Ancylostoma duodenale.

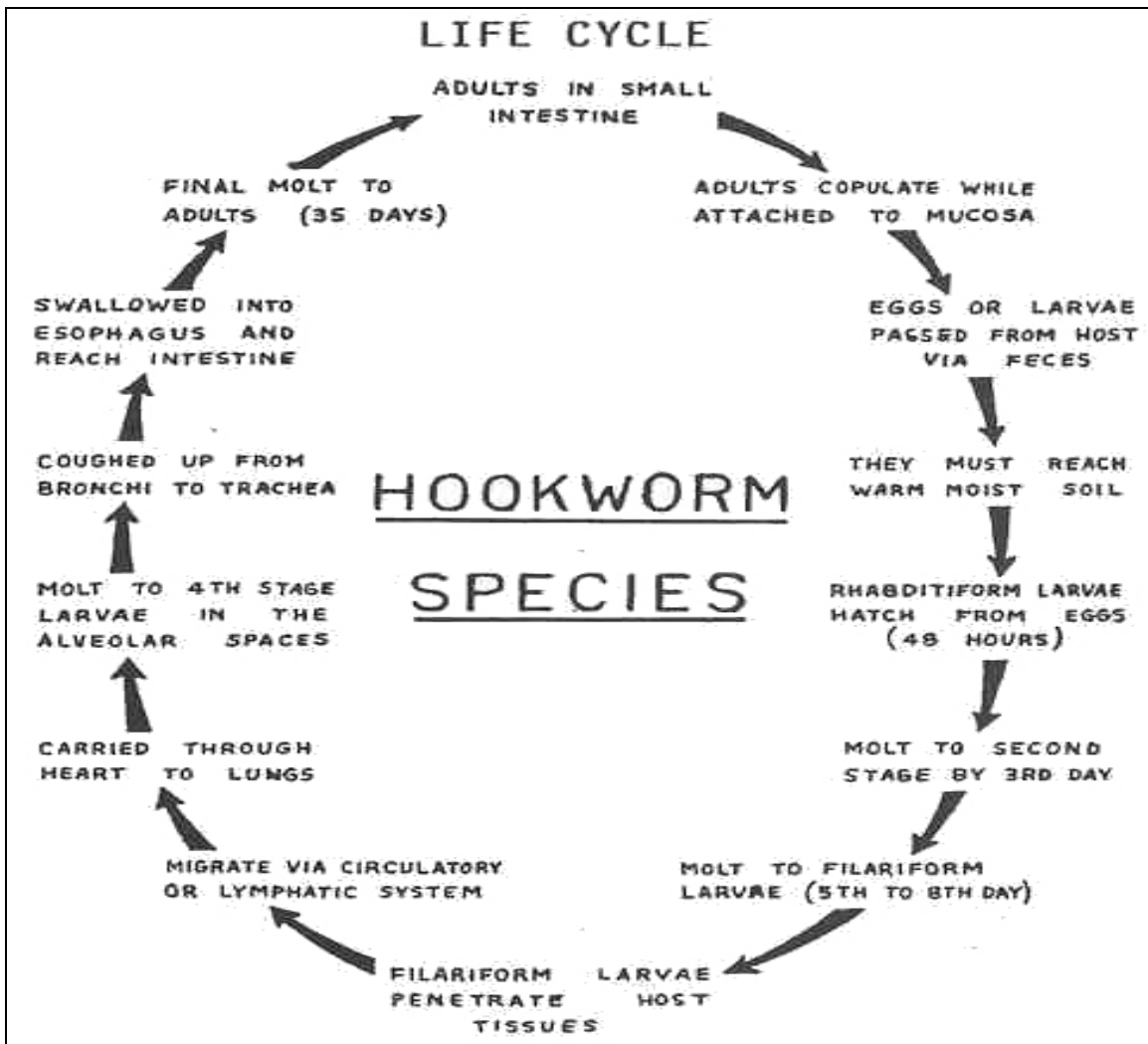


Figure 4-19. Life cycle of Ancylostoma duodenale.

Ancylostoma duodenale

OVA

SIZE: 40 by 60 μ .

SHAPE: Oval with bluntly rounded ends.

COLOR: Hyaline.

OPERCULUM: Absent.

CONTENT: Yolk mass usually in cleavage (larva).

SHELL WALL: Thin, single layer.

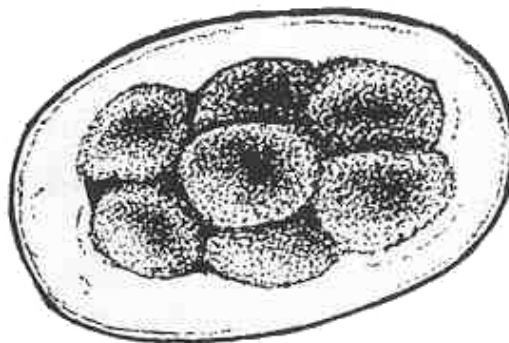


Figure 4-20. Stages of Ancylostoma duodenale (continued).

Ancylostoma duodenale

ADULT

SIZE

MALE: 8 to 11 mm.

FEMALE: 10 to 13 mm.

SHAPE: Cylindrical; head is curved dorsally.

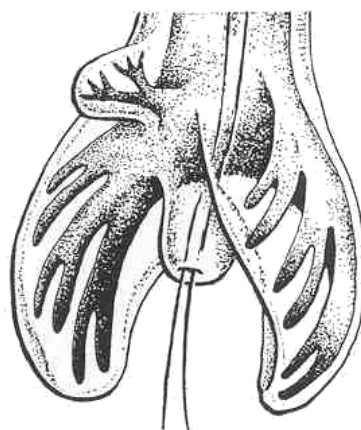
COLOR: Grayish-white.

BUCCAL STRUCTURES: Two prominent pairs of teeth.

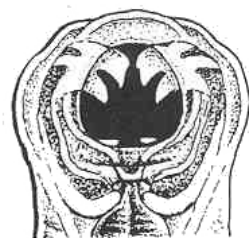COPULATORY BURSA: Male.

PAIRED COPULATORY SPICULES:
Separated.

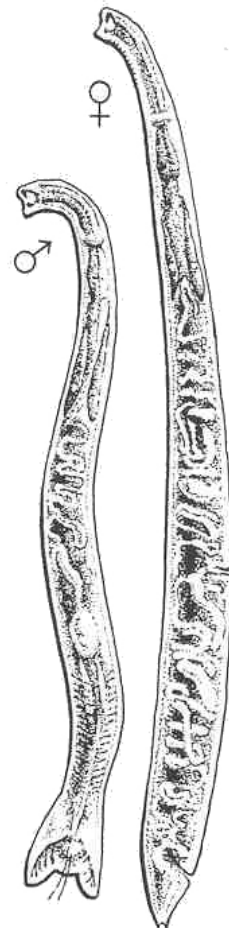
SMALL PAIRED DORSAL RAYS:
Tripartite.



ANCYLOSTOMA DUODENALE
WITH TRIPARTITE DORSAL RAYS
AND SEPARATED SPICULES



ANCYLOSTOMA DUODENALE
WITH PROMINENT TEETH



RHABDITIFORM LARVA: Same as Necator americanus.

Figure 4-20. Stages of Ancylostoma duodenale (concluded).

ORGANISM 7: Necator americanus

GENERAL CHARACTERISTICS

COMMON NAME: New World hookworm (archaic).

GEOGRAPHICAL DISTRIBUTION: Western hemisphere.

PATHOGENESIS: Inflammation of intestinal mucosa, anemia (chronic nutritional deficiency type) diarrhea, pneumonitis, eosinophilia, erythema, dyspnea. Same as A. duodenale.

HABITAT: Small intestines.

INTERMEDIATE HOST: None.

RESERVOIR HOST: None.

INFECTIVE FORM: Filariform larva.

MODE OF INFECTION: Active penetration.

SPECIMEN OF CHOICE: Feces.

Figure 4-21. Information on Necator americanus.

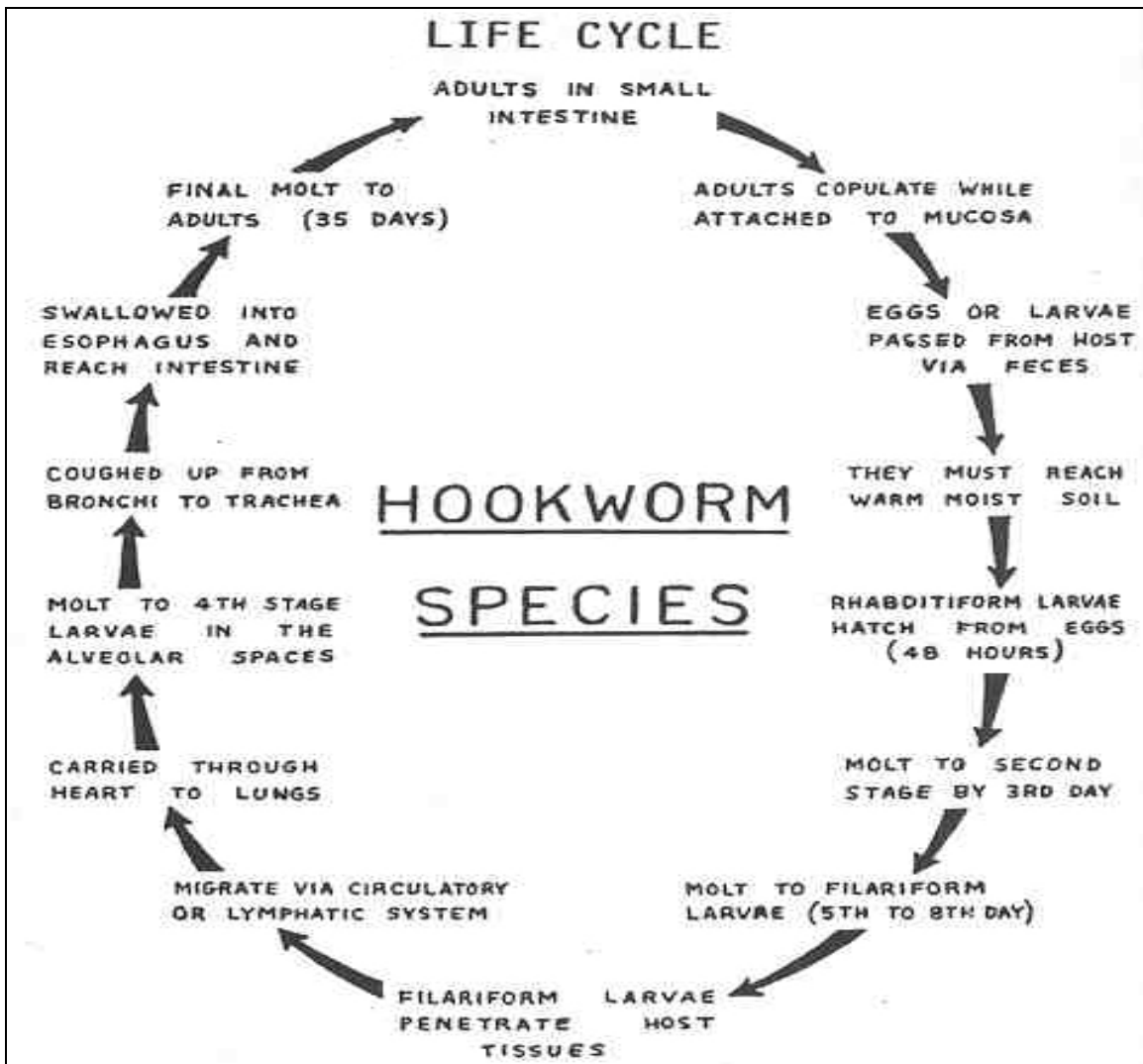
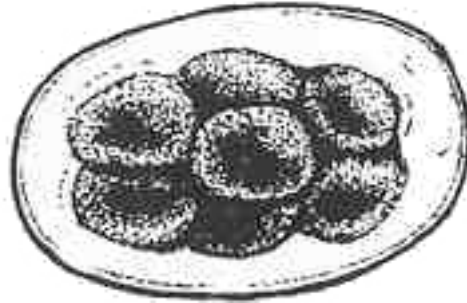


Figure 4-22. Life cycle of Necator americanus.

Necator americanus

OVA

Same as A. duodenale



ADULT

SIZE: Smaller than A. duodenale.

Male: 5 to 9 mm.

FEMALE: 9 to 11 mm.

SHAPE: Cylindrical; head is sharply dorsally curved.

COLOR: Grayish-white.

BUCCAL STRUCTURES: Prominent ventral and dorsal semilunar cutting plates.

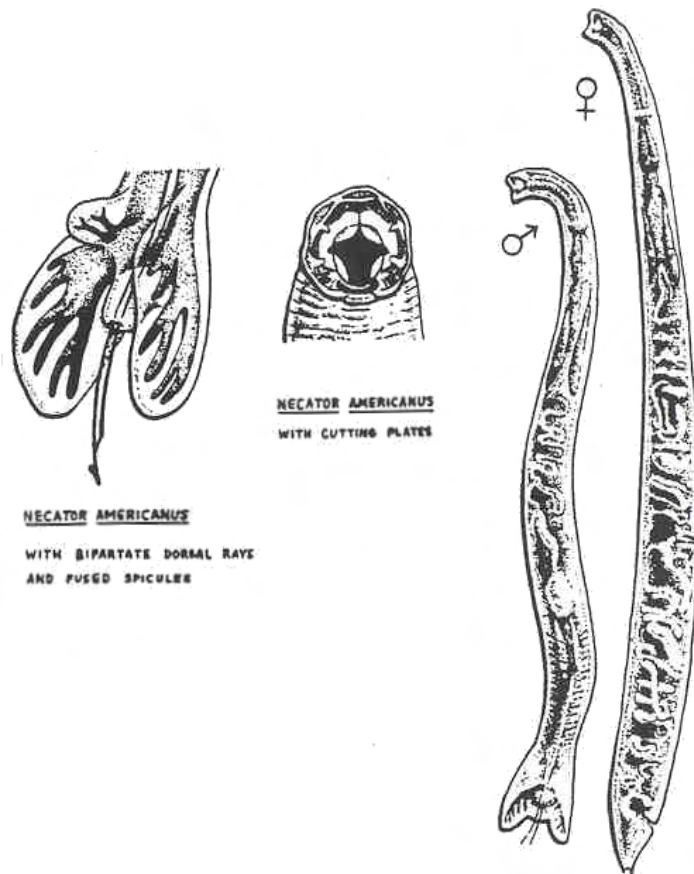
COPULATORY BURSA: Male.

PAIRED COPULATORY SPICULES: Fused with a terminal barb.

SMALL PAIRED DORSAL RAYS: Bipartite.

Figure 4-23. Stages of Necator americanus (continued).

Necator americanus adult
(continued)



RHABDITIFORM LARVAE

SIZE: 250 μ .

BUCCAL CAVITY: large
(longitudinal parallel lines).

GENITAL PRIMORDIUM: Small (inconspicuous).

TAIL: Slender, long, and tapering.

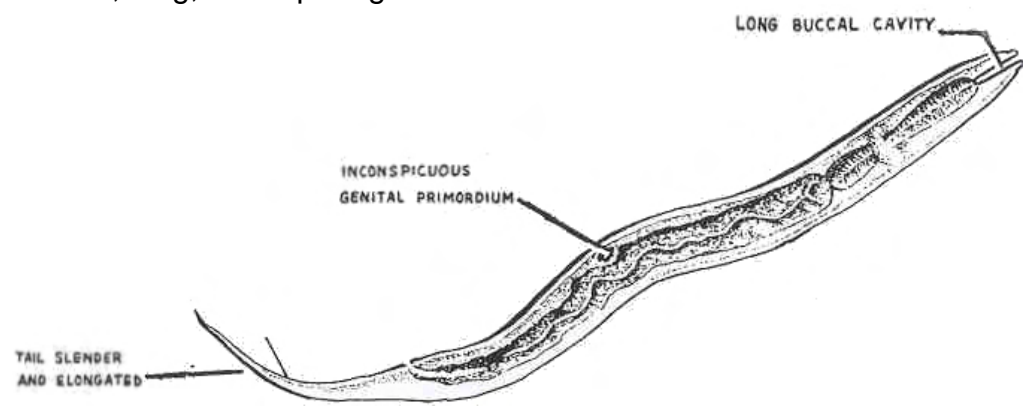


Figure 4-23. Stages of Necator americanus (concluded).

ORGANISM 8: Strongyloides stercoralis

GENERAL CHARACTERISTICS

COMMON NAME: Threadworm.

GEOGRAPHICAL DISTRIBUTION: Worldwide.

PATHOGENESIS: Chronic gastrointestinal inflammation, eosinophilia, anemia, recurrent diarrhea, secondary bacterial infections, biliary and pancreatic inflammation.

HABITAT: Small intestine.

INTERMEDIATE HOST: None.

RESERVOIR HOST: Perhaps dogs and apes.

INFECTIVE FORM: Filariform larva.

MODE OF INFECTION: Active penetration.

SPECIMEN OF CHOICE: Feces.

Figure 4-24. Information on Strongyloides stercoralis.

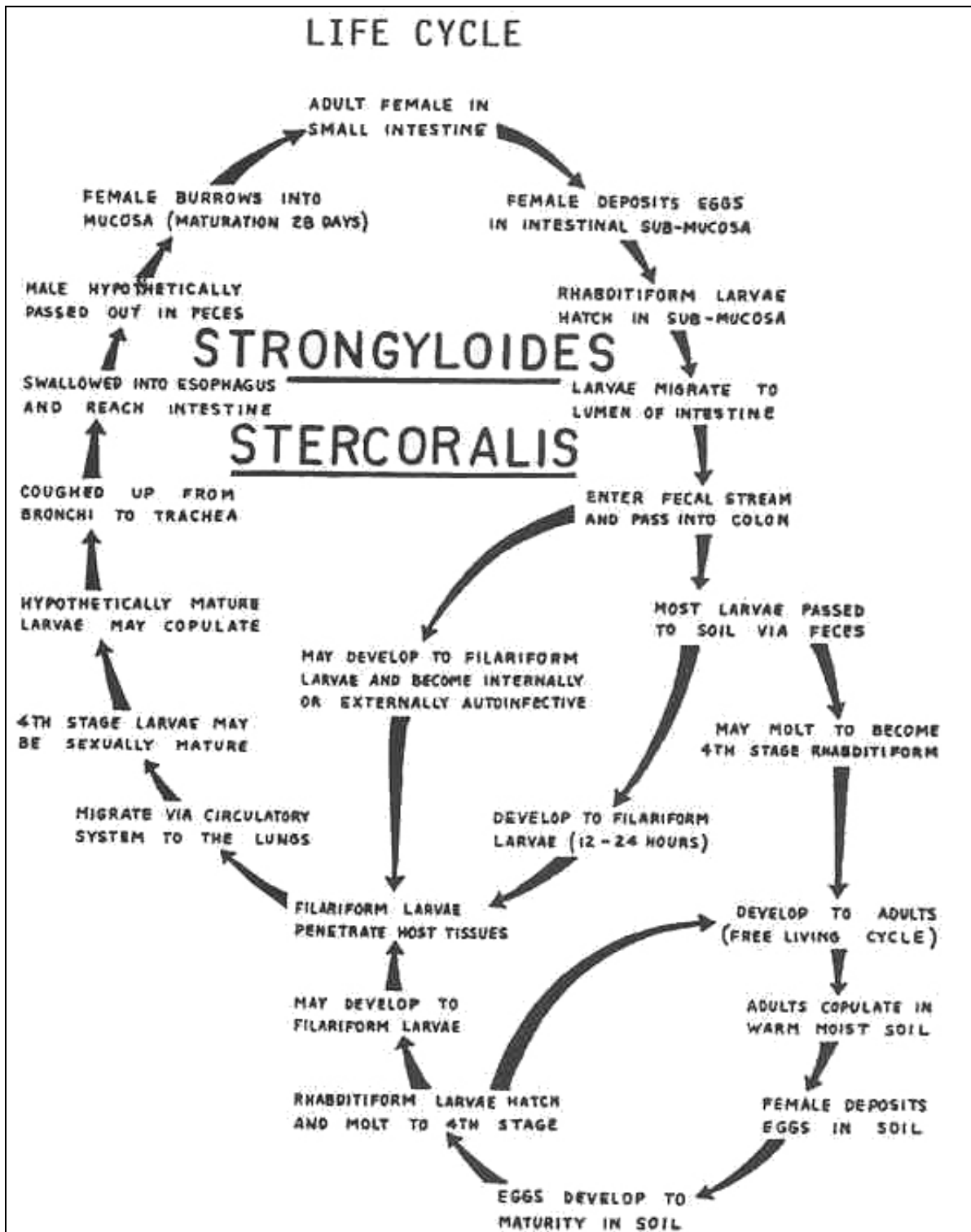


Figure 4-25. Life cycle of Strongyloides stercoralis. Parasitic and free living cycles.

Strongyloides stercoralis

OVA

Rarely seen; similar to Hookworm species eggs; may contain a larva.

ADULT

SIZE

MALE: Less than 1 mm; seen only in free living cycle.

FEMALE: 1 mm for the free living; 2 mm for the parasitic.

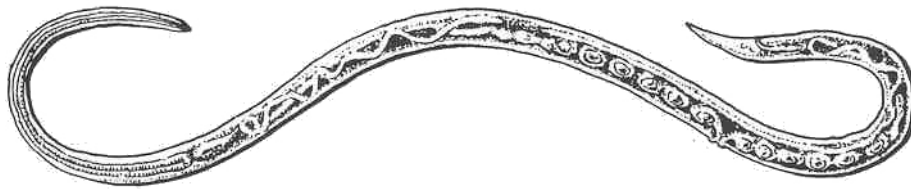SHAPE: Very slender, threadlike, male has a curved tail.

COLOR: Colorless; semitransparent.

BUCCAL STRUCTURES: Short buccal cavity.

COPULATORY BURSA: Absent.

SPICULES: Two.



RHABDITIFORM LARVA

SIZE: 250 μ .

BUCCAL CAVITY: Short.

GENITAL PRIMORDIUM: Large and conspicuous.

TAIL: Short and stubby.

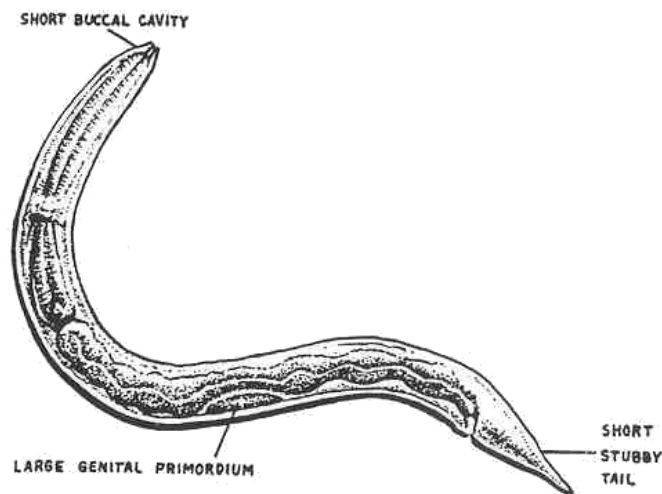


Figure 4-26. Stages of Strongyloides stercoralis.

b. **Tissue Dwelling Nematodes.** See figures 4-27 through 4-41.

ORGANISM 1: Toxocara species (T. canis and T. cati)

GENERAL CHARACTERISTICS

COMMON NAME: Visceral larval.

GEOGRAPHICAL DISTRIBUTION: Worldwide migrans.

PATHOGENESIS: Granulomatous lesions of liver, lungs and other organs, eosinophilia, anemia, hepatosplenomegaly, pneumonitis, dermatitis, neurological disturbances, tumors of eyes, spinal cord and heart in severe cases.

HABITAT

MAN: Any organs and tissues of the body.

DEFINITIVE HOST: Small intestines of dogs and cats.

INTERMEDIATE HOST: None.

RESERVOIR HOST: Same as definitive host, dogs and cats.

INFECTIVE FORM: Embryonated egg.

MODE OF INFECTION: Ingestion.

SPECIMEN OF CHOICE: Tissue biopsy and serological.

Figure 4-27. Information on Toxocara.

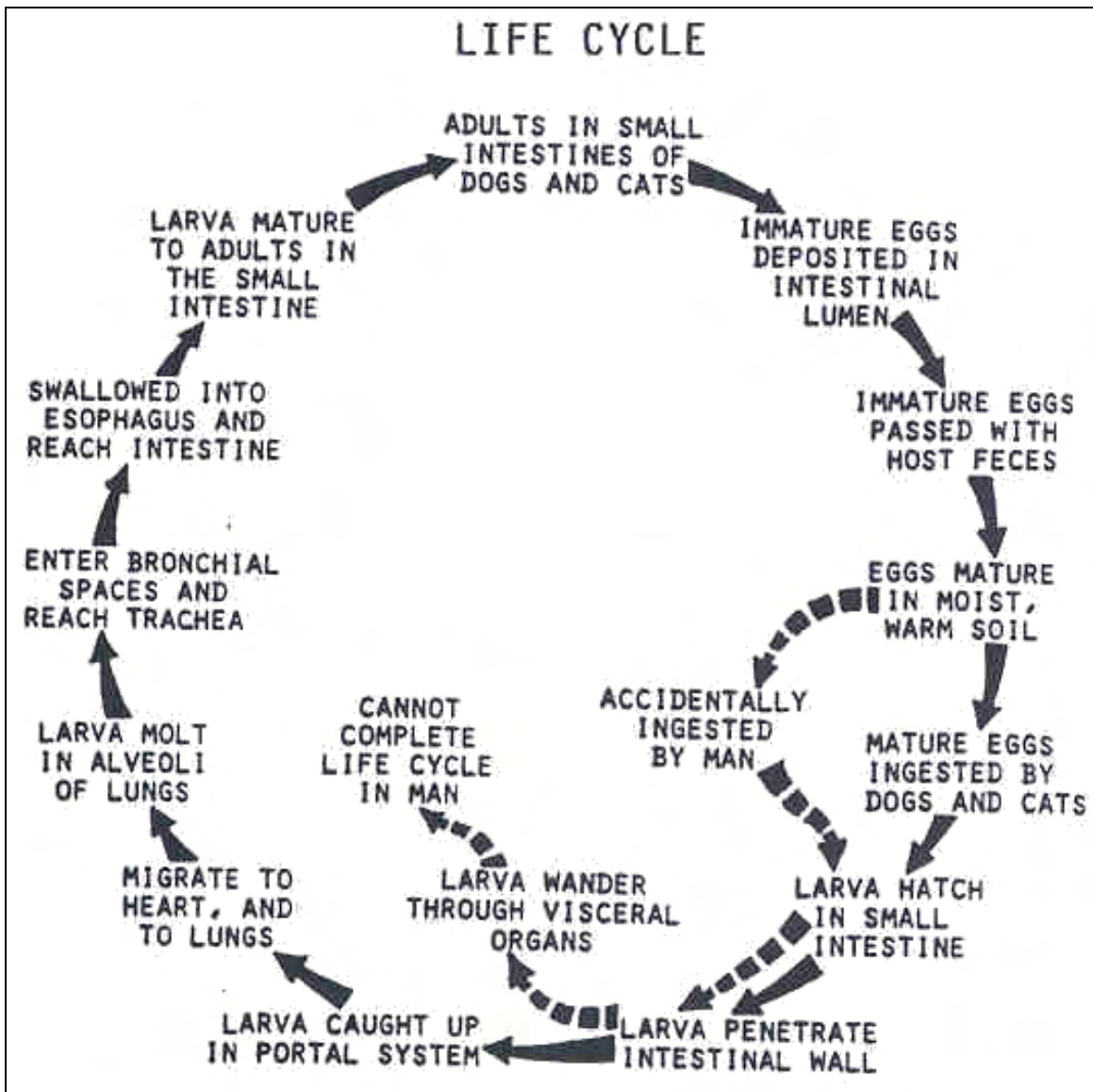


Figure 4-28. Life cycle of Toxocara species.

Toxocara

OVA

Seen in feces of infected pets.
SIZE: 85 by 75 μ .
SHAPE: Spherical.
COLOR: Light brown.
OPERCULUM: Absent.
CONTENT: Developing larva (yolk mass)



ADULT

Seen in definitive host.
SIZE
MALE: 4 to 6 cm.
FEMALE: 6.5 to 10 cm.
SHAPE: Elongated, cylindrical.
COLOR: Pinkish-white.
BUCCAL STRUCTURES: Three characteristic lips.
CERVICAL ALAE



LARVA

Seen in tissues of man:
larval section surrounded by granuloma.




Figure 4-29. Stages of Toxocara species.

ORGANISM 2: Ancylostoma species

GENERAL CHARACTERISTICS

COMMON NAME: Cutaneous larva migrans, creeping eruption.

GEOGRAPHICAL DISTRIBUTION: Worldwide; tropics and subtropics.

PATHOGENESIS: Eosinophilia, cellular infiltration, reddish serpiginous intracutaneous tunnels, secondary bacterial infections.

HABITAT

MAN: Cutaneous and subcutaneous tissue.

DEFINITIVE HOST: Small intestines (usually cats and dogs).

INTERMEDIATE HOST: None.

RESERVOIR HOST: Same as the definitive host.

INFECTIVE FORM: Filariform larva.

MODE OF INFECTION: Penetration.

SPECIMEN OF CHOICE: Clinical evidence is diagnostic.

Figure 4-30. Information on Ancylostoma.

Ancylostoma species (continued)

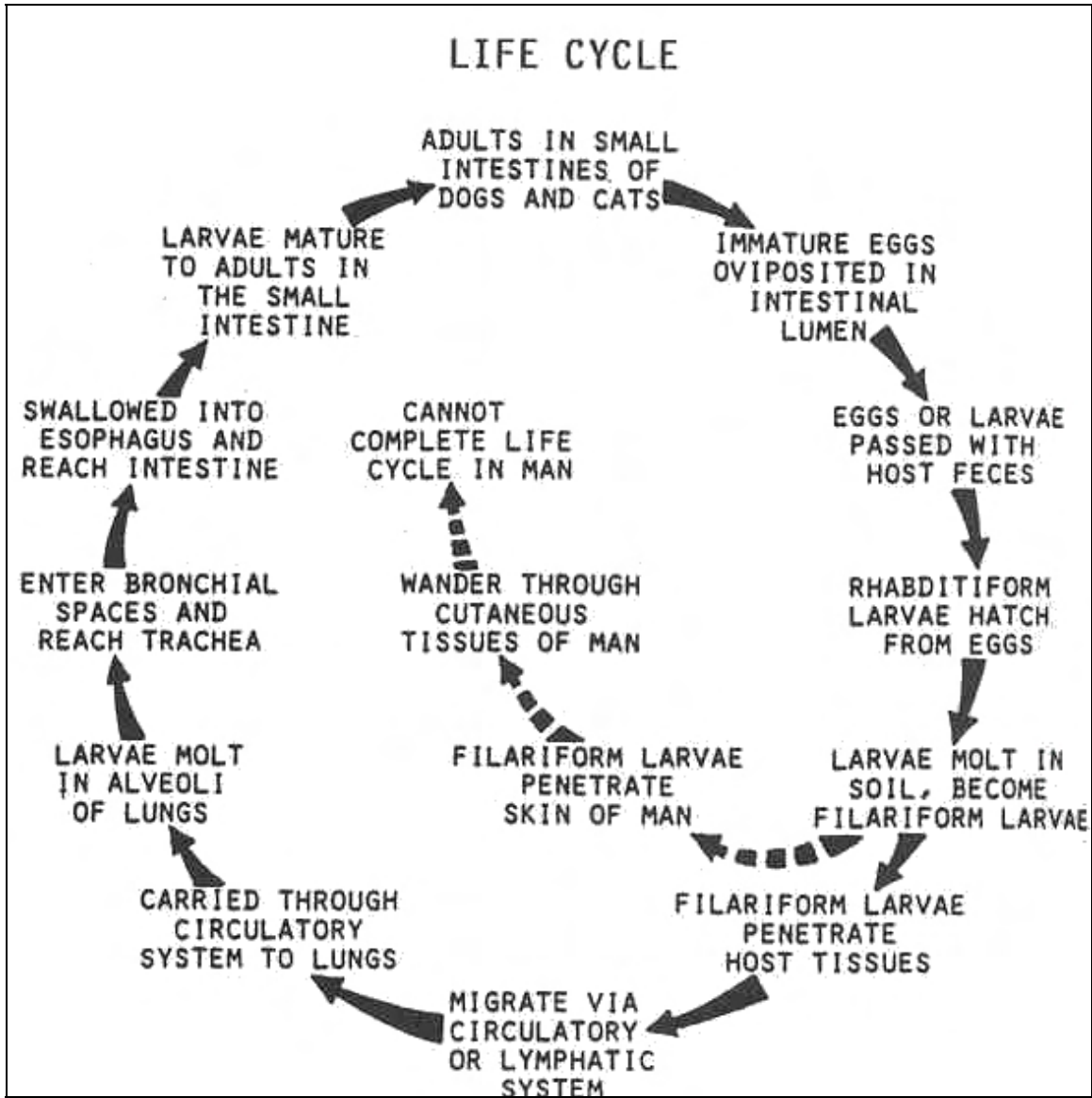


Figure 4-31. Life cycle of Ancylostoma species.

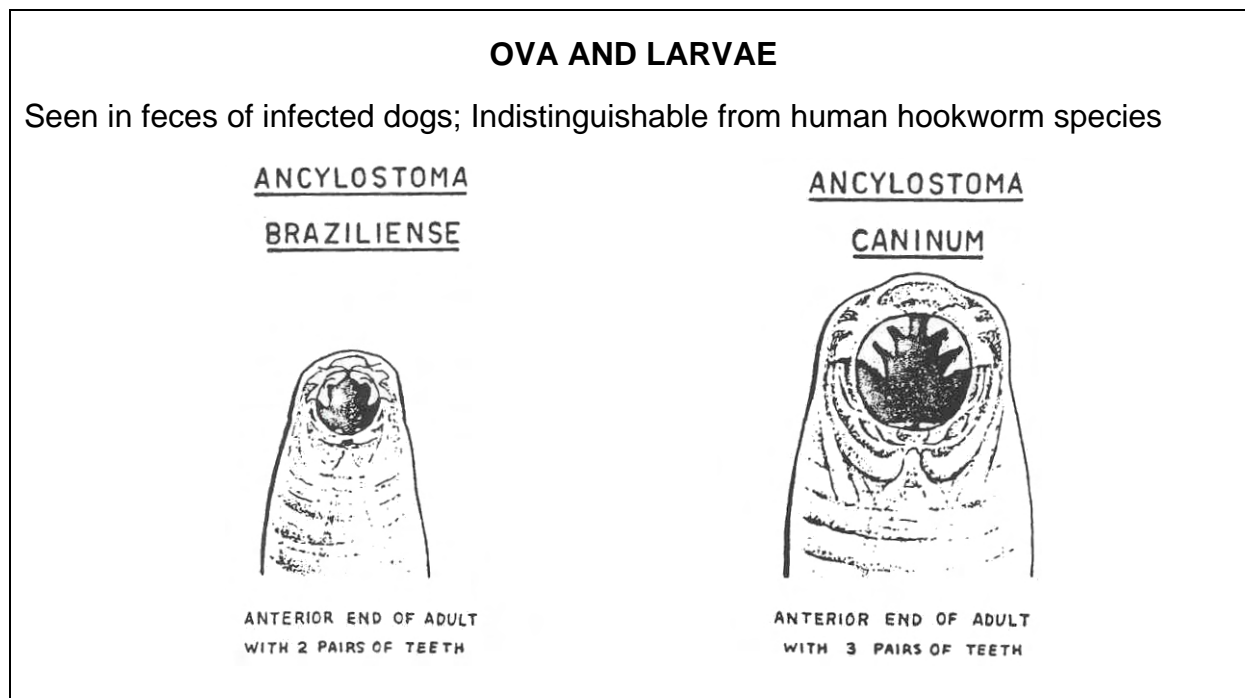


Figure 4-32. Stages of Ancylostoma species.

ORGANISM 3: Capillaria hepatica

GENERAL CHARACTERISTICS

COMMON NAME: None.

GEOGRAPHICAL DISTRIBUTION: Worldwide.

PATHOGENESIS: Inflammation of the liver, tissue destruction, cardiac abnormalities.

HABITAT: Liver.

TRANSPORT HOST: Same species as definitive host, carnivores.

RESERVOIR HOST: Mice, rats, prairie dogs, beavers, monkeys.

INFECTIVE FORM: Embryonated eggs.

MODE OF INFECTION: Ingestion of contaminated soil or food

SPECIMEN OF CHOICE: Liver biopsy.

Figure 4-33. Information on Capillaria hepatica.

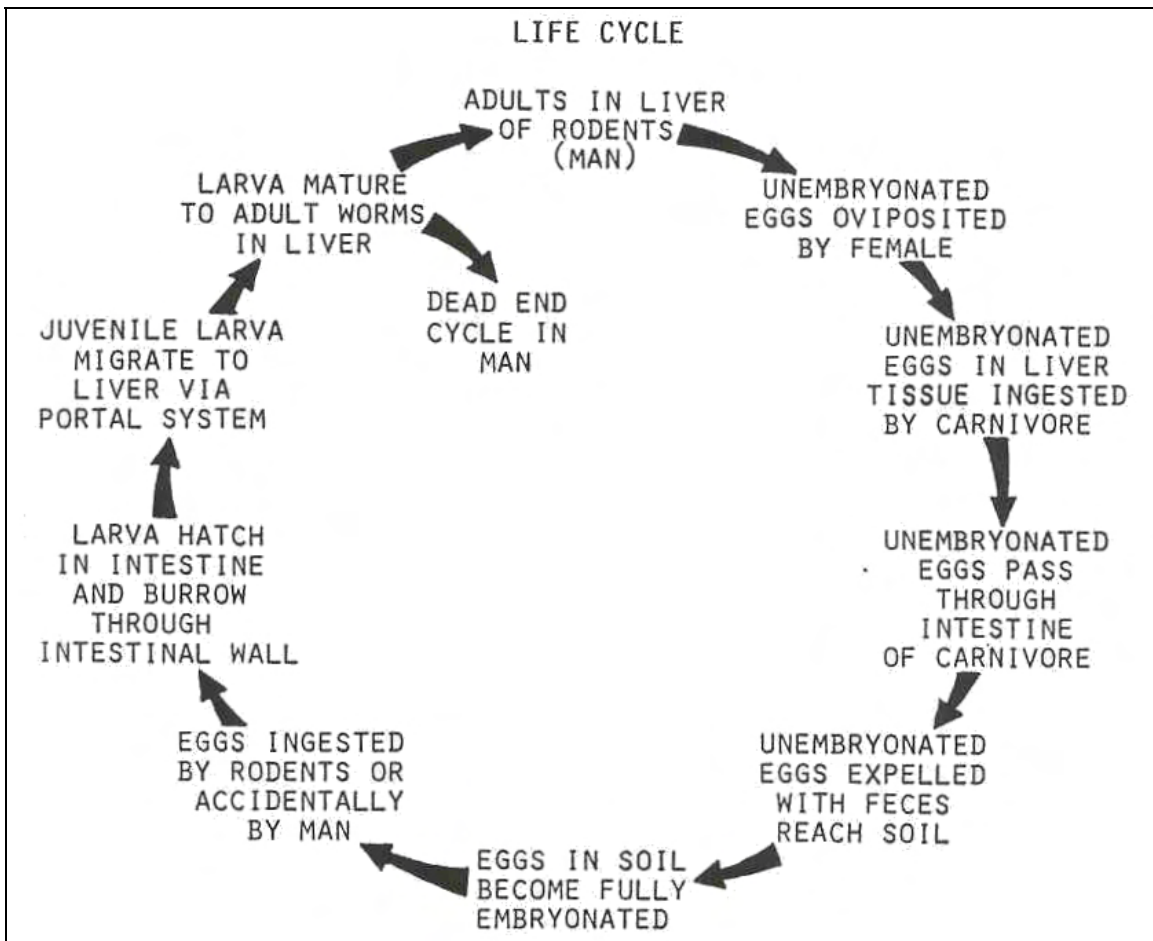


Figure 4-34. Life cycle of Capillaria hepatica.

Capillaria hepatica

OVA

SIZE: 30 x 60 μ .

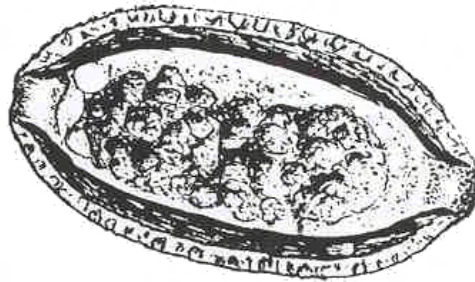SHAPE: Barrel-shaped.

COLOR: Brown.

OPERCULUM: Absent.

CONTENT: Yolk mass.

SHELL WALL: Thick and pitted; bipolar plug.



ADULT

SIZE

MALE: About 4 mm.

FEMALE: About 10 mm.

SHAPE: slender and round.

COLOR: Cream-colored.

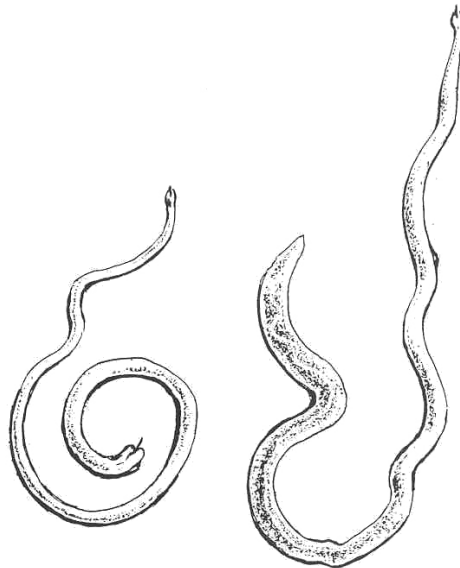


Figure 4-35. Stages of Capillaria hepatica.

ORGANISM 4: Trichinella spiralis

GENERAL CHARACTERISTICS

COMMON NAME: Trichina worm.

GEOGRAPHICAL DISTRIBUTION: Worldwide; prevalent in pork eating countries (USA and Europe).

PATHOGENESIS: Larval invasion of striated muscle and vital organs, eosinophilia, acute interstitial inflammation, pneumonitis, pleurisy, encephalitis (periorbital swelling), meningitis, nephritis, deafness, peritonitis, eye and brain trauma, myocarditis.

HABITAT

ADULTS: Small intestines.

LARVAE: Striated muscle.

INTERMEDIATE HOST: Carnivores; pigs. One host may serve as both definitive and intermediate host.

RESERVOIR HOST: Pigs, wild boars, rats, bears, walruses, and many other carnivores.

INFECTIVE FORM: Encysted larvae.

MODE OF INFECTION: Ingestion.

SPECIMEN OF CHOICE: Tissue biopsy.

Figure 4-36. Information on Trichinella spiralis.

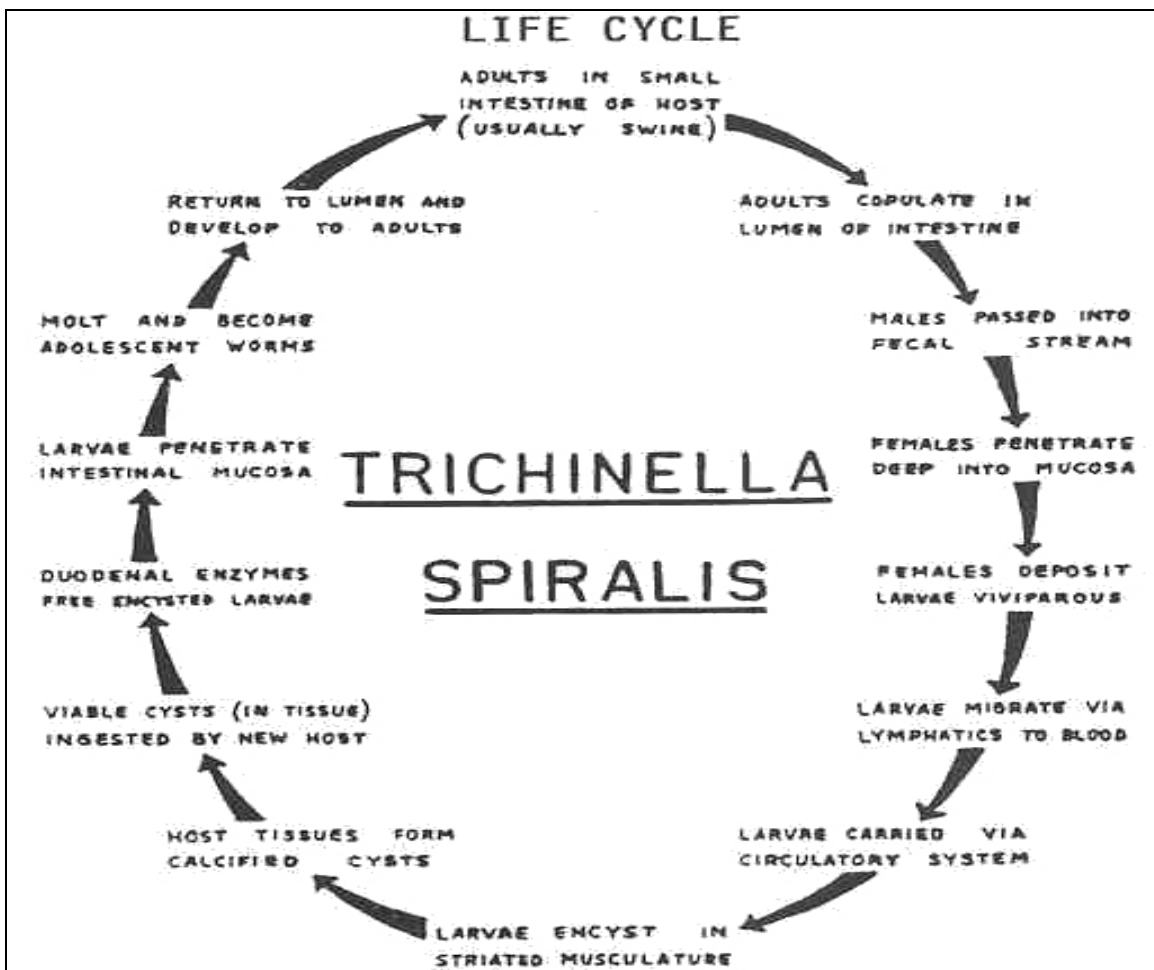


Figure 4-37. Life cycle of Trichinella spiralis.

Trichinella spiralis

ADULT

SIZE

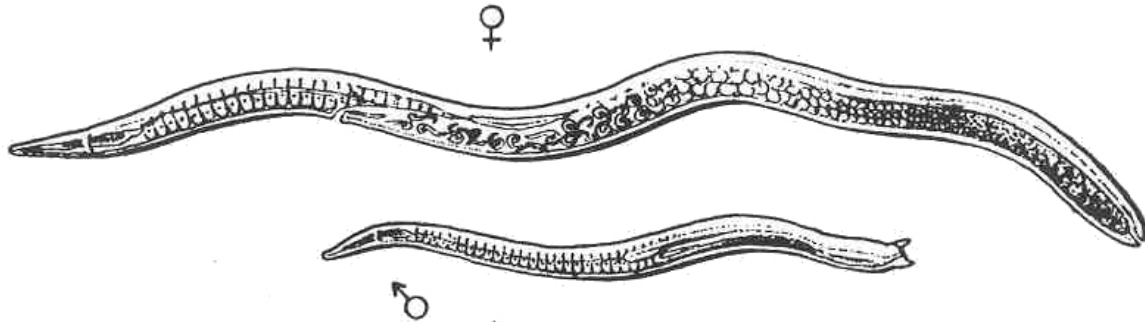
MALE: About 1.5 mm .

FEMALE: 3 to 4 mm.

SHAPE: Slender tapering to a large posterior end.

COLOR: Colorless.

MALE: Has two caudal appendages.



RHABDITIFORM LARVAE

SIZE: 6 x 100 μ .

SHAPE: Coiled.

COLOR: Colorless.

IN STRIATED MUSCLE: Surrounded by a longitudinal capsule.

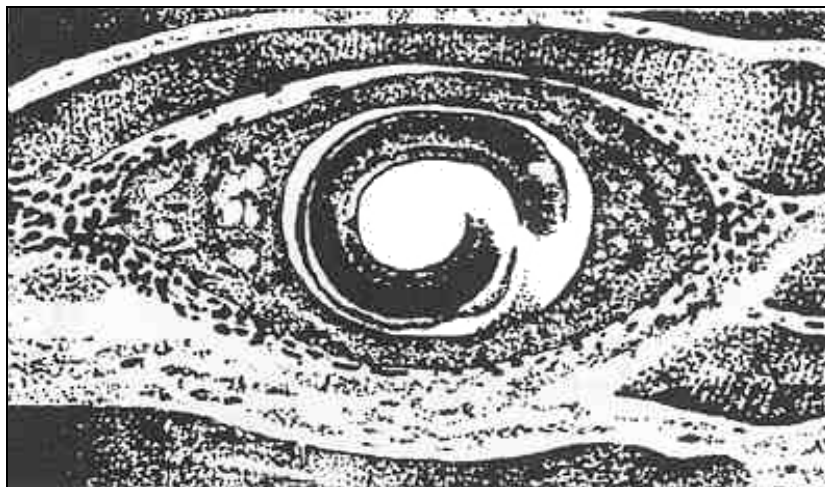

Figure 4-38. Stages of Trichinella spiralis.

ORGANISM 5: Dracunculus medinensis

GENERAL CHARACTERISTICS

COMMON NAME: Guinea worm.

GEOGRAPHICAL DISTRIBUTION: Africa, Asia (India).

PATHOGENESIS: Subcutaneous blisters, edema, abscesses, extensive ulceration, necrosis, eosinophilia.

HABITAT: Connective and subcutaneous tissue.

INTERMEDIATE HOST: Copepod (Cyclops species).

RESERVOIR HOST: Dogs, cats, apes, cattle, and horses.

INFECTIVE FORM: Third-stage larva.

MODE OF INFECTION: Ingestion.

SPECIMEN OF CHOICE: Exudate from irrigated lesions.

Figure 4-39. Information on Dracunculus medinensis.

Dracunculus medinensis

ADULT

SIZE

MALE: Inconspicuous, less than 3 cm.

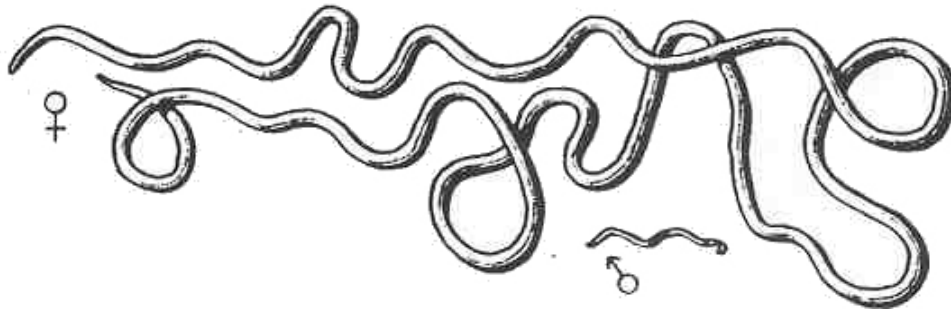
FEMALE: 75 to 120 cm.

SHAPE: Elongated, cylindrical, rope-like.

COLOR: White.

BUCCAL STRUCTURES: Small triangular mouth surrounded by a quadrangular sclerotized plate.

EXTRACTED from ulcerated lesion.



RHABDITIFORM LARVAE

SIZE: 500 to 750 μ .

SHAPE: Slender with a long filariform tail.

COLOR: colorless.

CUTICLE: Striated.

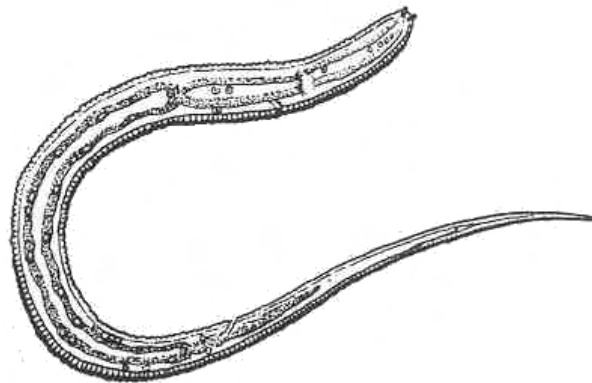


Figure 4-41. Stages of Dracunculus medinensis.

4-3. BLOOD AND TISSUE NEMATODES

This family consists of members which have a unique stage in their life cycle called the microfilaria. This stage is equivalent to the rhabditiform larva of other nematodes. This is the stage which is infective to the vectors and, therefore, it must reach either the circulatory or lymphatic system. The microfilariae of some species retain the elongated egg membrane which shows as a characteristic sheath. In other species, the membrane is discarded and these are referred to as being unshed.

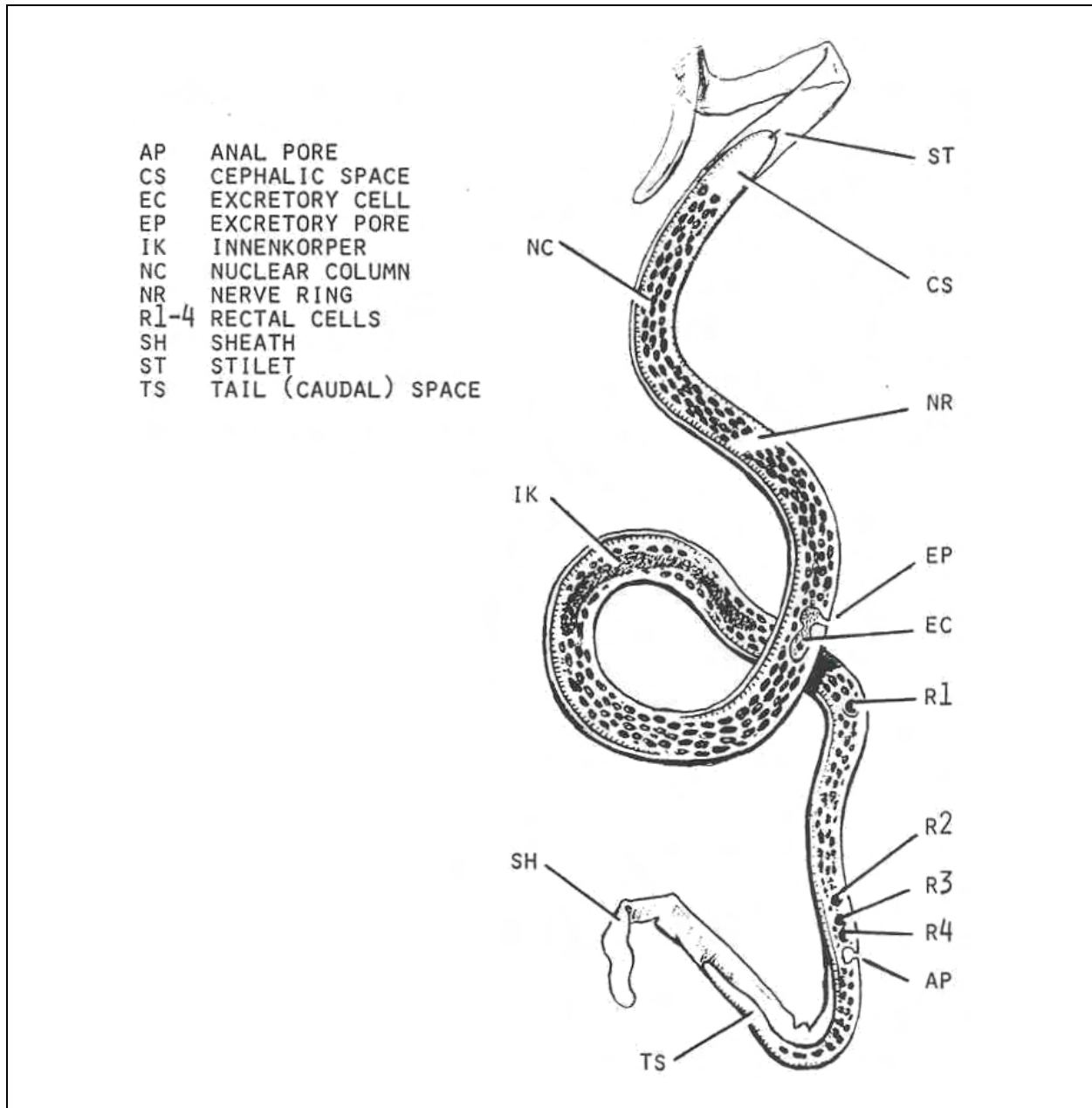


Figure 4-42. Typical microfilaria.

ORGANISM 1: Wuchereria bancrofti

GENERAL CHARACTERISTICS

COMMON NAME: Bancroft's filariasis, elephantiasis worm.

GEOGRAPHICAL DISTRIBUTION: Worldwide, prevalent in the tropics and subtropics.

PATHOGENESIS: Elephantiasis, fibrosis, thrombi, lymphatic inflammation, granulomatous infiltration.

HABITAT: Lymphatic system.

VECTOR: Mosquitoes.

RESERVOIR HOST: None.

INFECTIVE FORM: Filariform larva.

MODE OF INFECTION: Inoculation.

PERIODICITY: Nocturnal with subperiodic Pacific strains.

SPECIMEN OF CHOICE: Blood.

SPECIMEN PROCESSING: Giemsa's or Hematoxylin/Eosin stains.

Figure 4-43. Information on Wuchereria bancrofti.

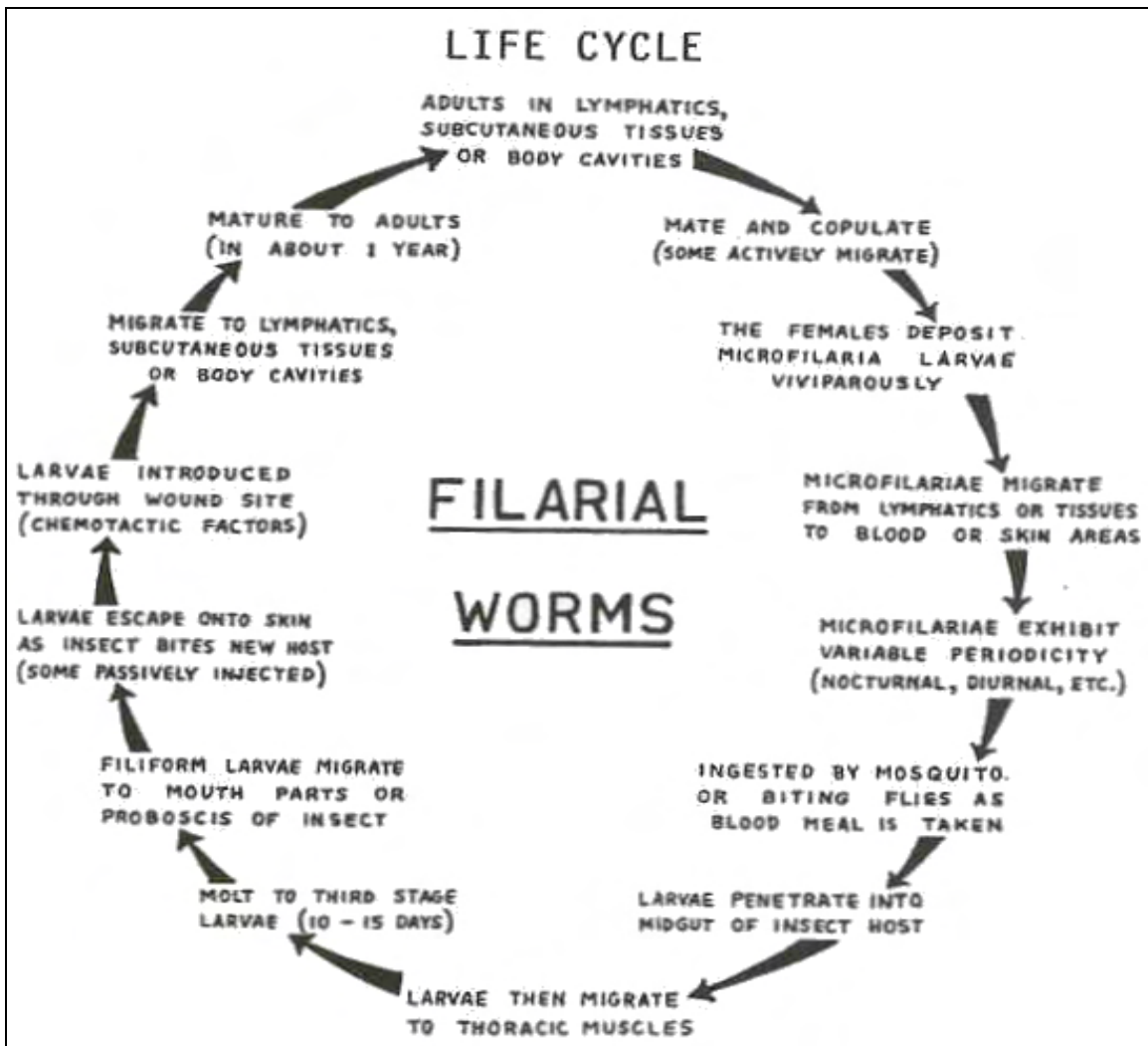


Figure 4-44. Life cycle of Wuchereria bancrofti.

Wuchereria bancrofti

MICROFILARIA

SIZE: 230 to 296 μ .

SHEATH: Present.

TAIL: Blunt.

TERMINAL NUCLEI: Do not extend to the tip of the tail.

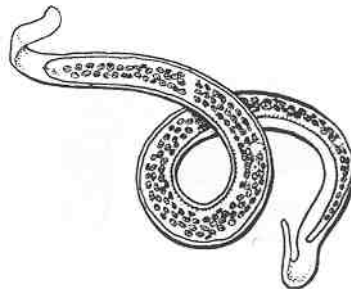


Figure 4-45. Microfilaria stage of Wuchereria bancrofti.

ORGANISM 2: Brugia malayi

GENERAL CHARACTERISTICS

COMMON NAME: Malayan filariasis, elephantiasis worm.

GEOGRAPHICAL DISTRIBUTION: Worldwide, prevalent in tropics and subtropics.

PATHOGENESIS: Elephantiasis, fibrosis, thrombi, lymphatic inflammation, granulomatous infiltration.

HABITAT: Lymphatic system.

VECTOR: Mosquitoes.

RESERVOIR HOST: None.

INFECTIVE FORM: Filariform larva.

MODE OF INFECTION: Inoculation.

PERIODICITY: Nocturnal with some subperiodic strains.

SPECIMEN OF CHOICE: Blood.

SPECIMEN PROCESSING: Giemsa's or Hematoxylin/Eosin stains.

Figure 4-46. Information on Brugia malayi.

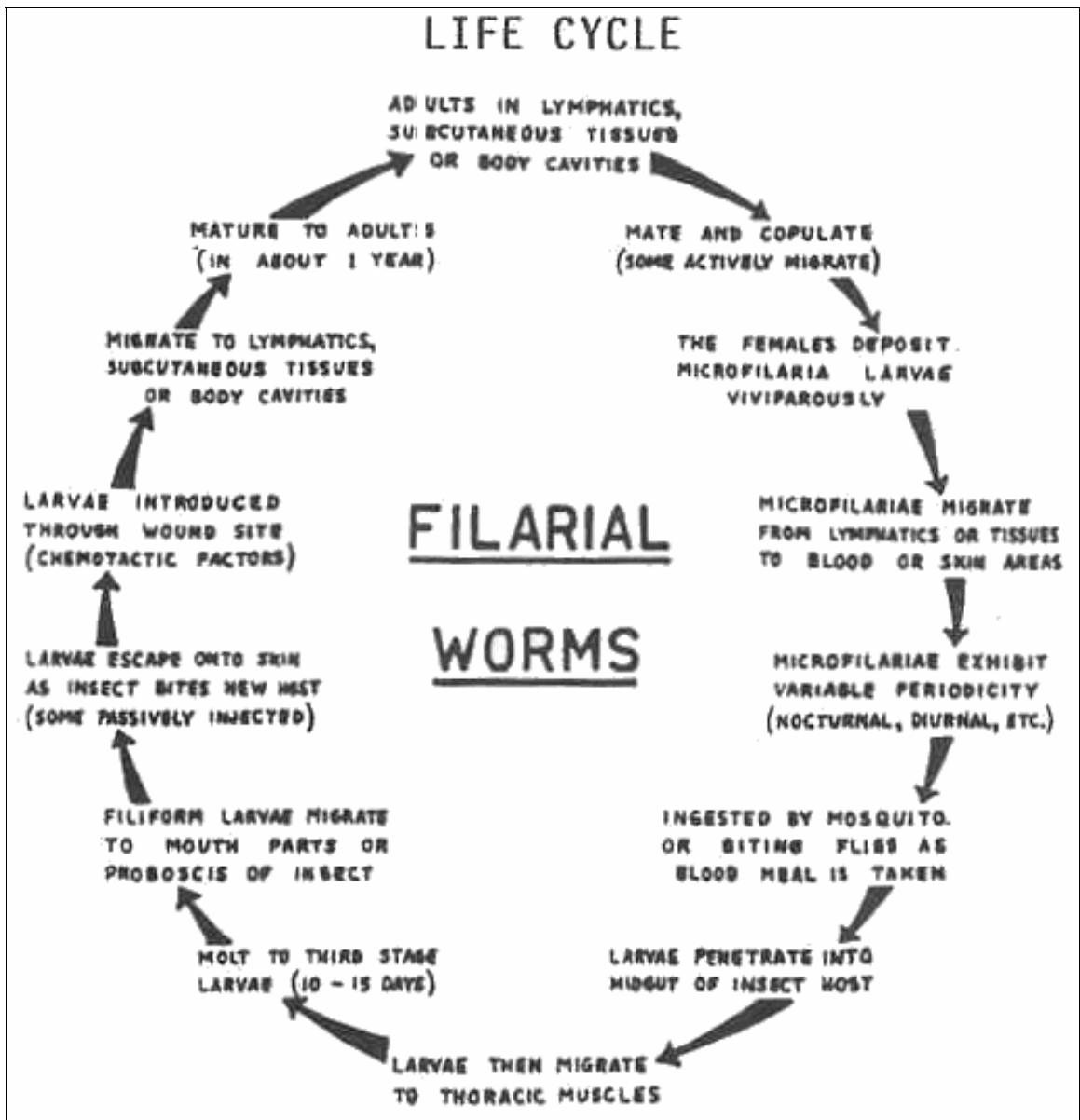


Figure 4-47. Life cycle of Brugia malayi.

Brugia malayi

MICROFILARIA

SIZE: 177 to 260 μ .

SHEATH: Present.

TAIL: Swollen tip.

TERMINAL NUCLEI: Two terminal, separated nuclei.

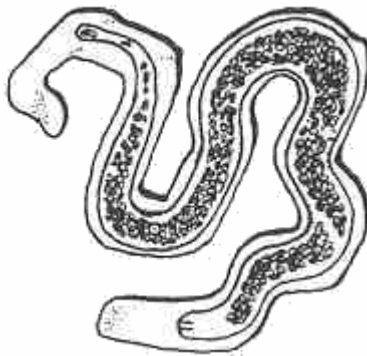


Figure 4-48. Microfilaria stage of Brugia malayi.

ORGANISM 3: Loa loa

GENERAL CHARACTERISTICS

COMMON NAME: Eyeworm.

GEOGRAPHICAL DISTRIBUTION: Africa.

PATHOGENESIS: Swelling, urticaria, fever, neurologic symptoms, allergic responses, irritation and destruction of ocular tissues.

HABITAT: Lymphatic system.

VECTOR: Chrysops species.

RESERVOIR HOST: Monkeys.

INFECTIVE FORM: Filariform larva.

MODE OF INFECTION: Inoculation.

PERIODICITY: Diurnal.

SPECIMEN OF CHOICE: Blood.

SPECIMEN PROCESSING: Giemsa's or Hematoxylin/Eosin stains.

Figure 4-49. Information on Loa loa.

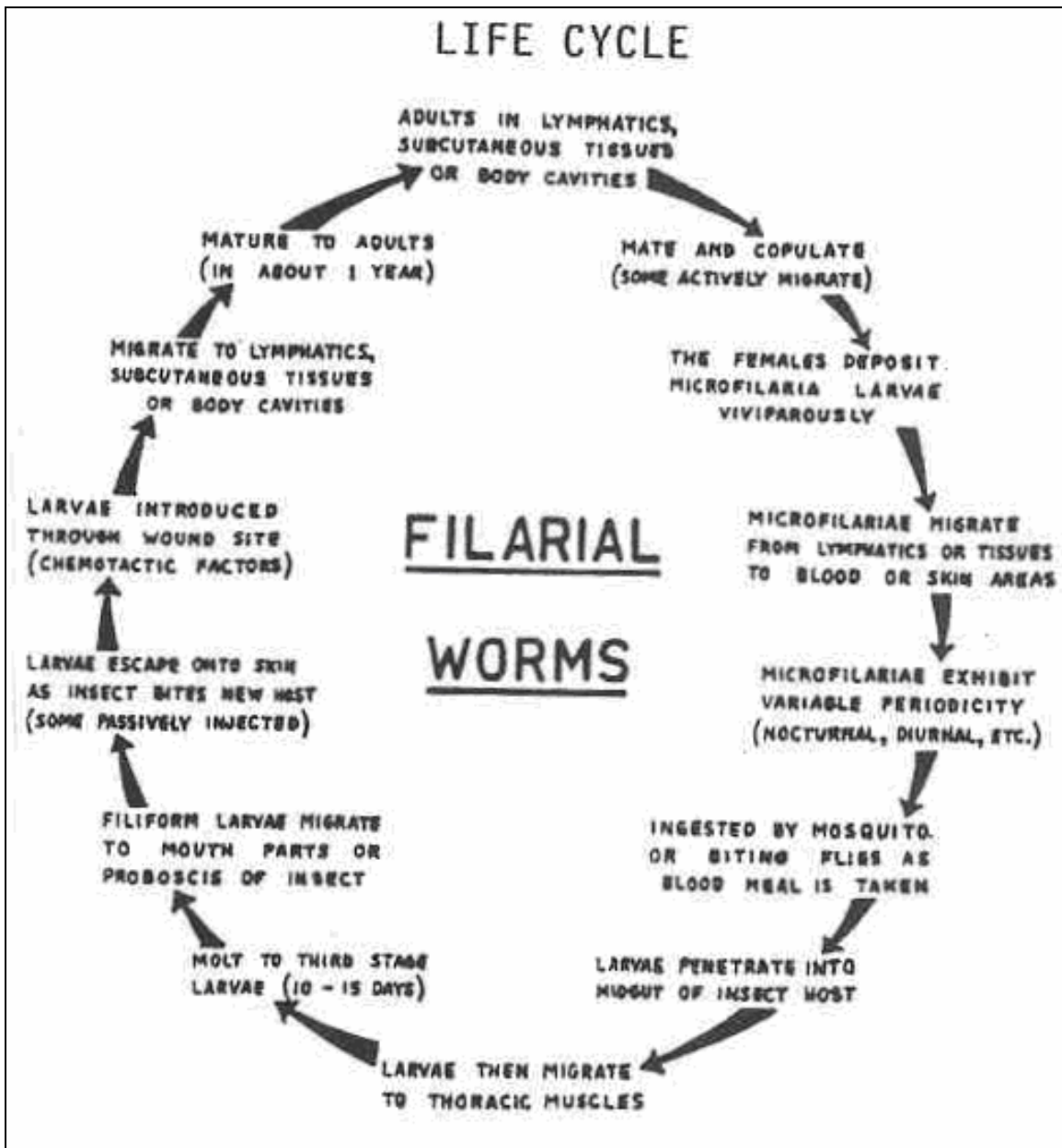


Figure 4-50. Life cycle of Loa loa.

Loa loa

MICROFILARIA

SIZE: 250 to 300 μ .

SHEATH: Present.

TAIL: Pointed.

TERMINAL NUCLEI: Unbroken line of nuclei to the tip of the tail.

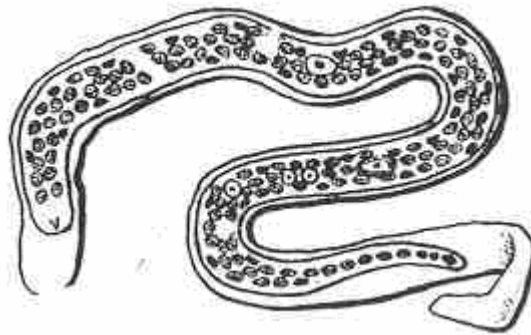


Figure 4-51. Microfilaria stage of Loa loa.

ORGANISM 4: Mansonella ozzardi

GENERAL CHARACTERISTICS

COMMON NAME: None.

GEOGRAPHICAL DISTRIBUTION: Central and South America.

PATHOGENESIS: Usually asymptomatic, mild discomfort with eosinophilia and articular pain.

HABITAT: Mesenteries and fatty tissue of the body cavities.

VECTOR: Culicoides species.

RESERVOIR HOST: None.

INFECTIVE FORM: Filariform larva.

MODE OF INFECTION: Inoculation.

PERIODICITY: None.

SPECIMEN OF CHOICE: Blood.

SPECIMEN PROCESSING: Giemsa's or Hematoxylin/Eosin stains.

Figure 4-52. Information on Mansonella ozzardi.

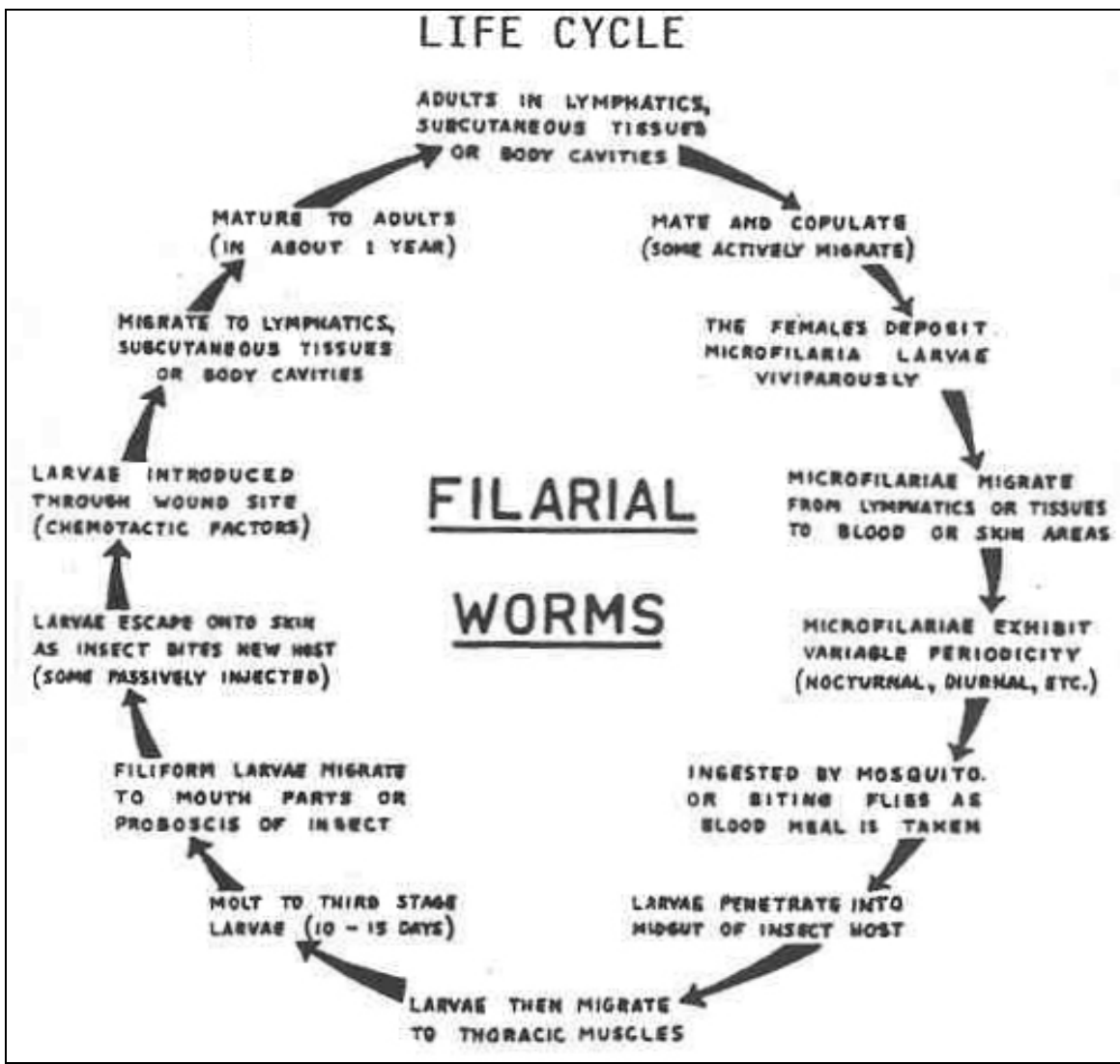


Figure 4-53. Life cycle of Mansonella ozzardi.

Mansonella ozzardi

MICROFILARIA

SIZE: 173 to 240 μ .

SHEATH: Absent.

TAIL: Blunt.

TERMINAL NUCLEI: Do not extend to the tip of the tail.




Figure 4-54. Microfilaria stage of Mansonella ozzardi.

ORGANISM 5: Mansonella perstans

GENERAL CHARACTERISTICS

COMMON NAME: None.

GEOGRAPHICAL DISTRIBUTION: South America and African tropics.

PATHOGENESIS: Mild vertigo, fever, edema, and abdominal and pectoral pain.

HABITAT: Deep connective tissue of the body cavity.

VECTOR: Culicoides species.

RESERVOIR HOST: Chimps and gorillas.

INFECTIVE FORM: Filariform larva.

MODE OF INFECTION: Inoculation.

PERIODICITY: None.

SPECIMEN OF CHOICE: Blood.

SPECIMEN PROCESSING: Giemsa's or Hematoxylin/Eosin stains.

Figure 4-55. Information on Mansonella perstans.

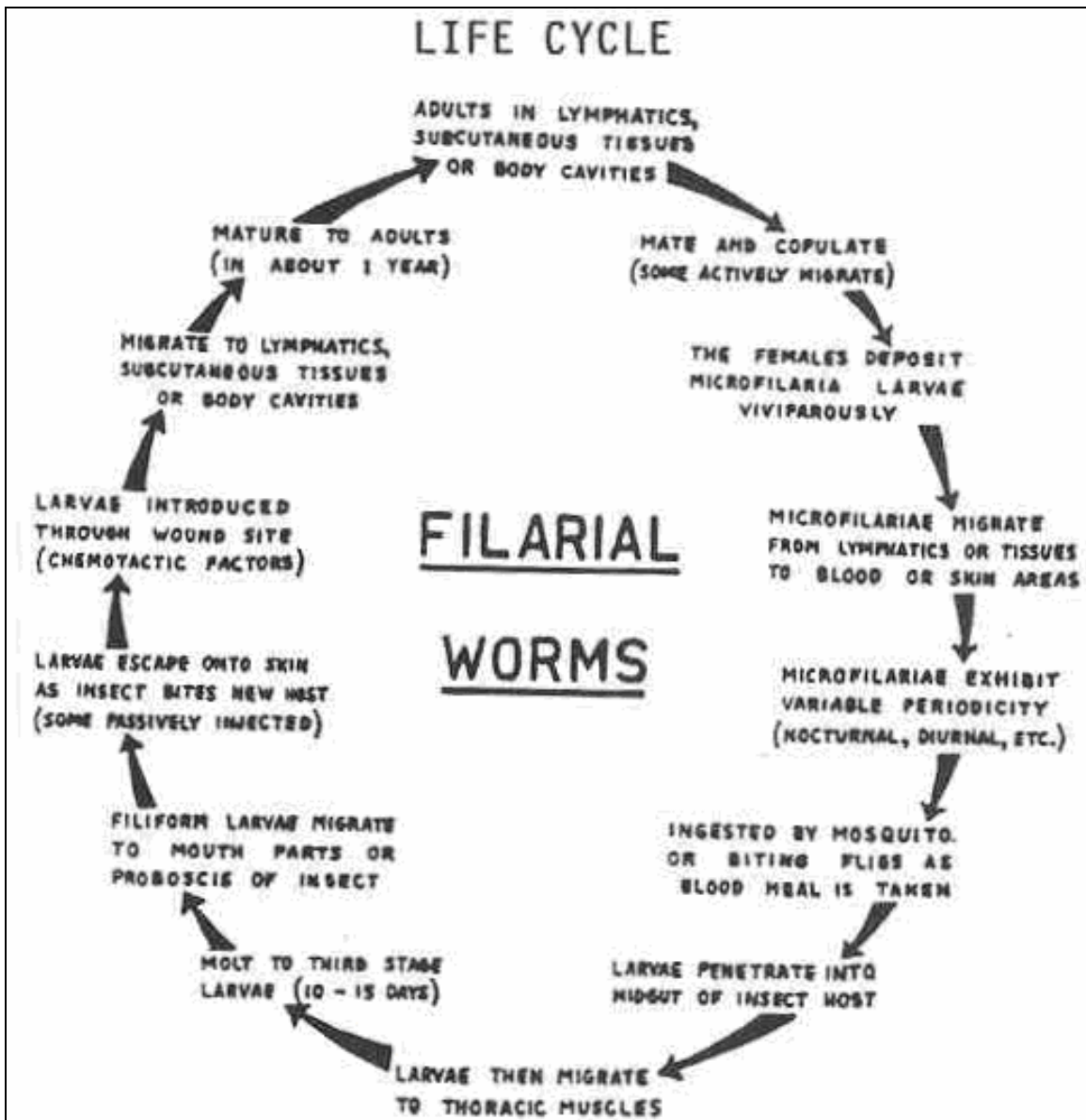


Figure 4-56. Life cycle of Mansonella perstans.

Mansonella perstans

MICROFILARIA

SIZE: 190 to 200 μ .

SHEATH: Absent.

TAIL: Blunt.

TERMINAL NUCLEI: Extend to the tip of the tail.

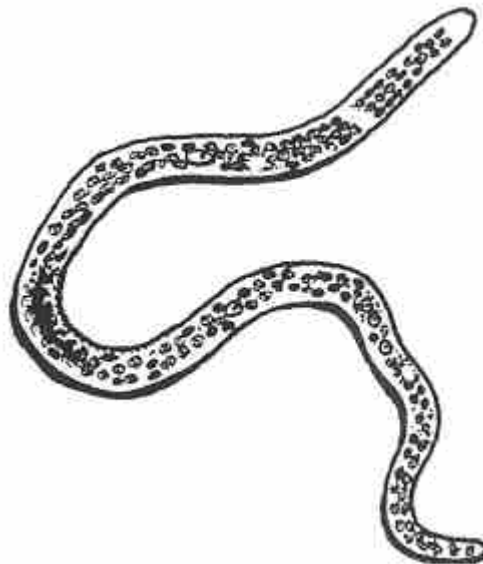


Figure 4-57. Microfilaria stage of Mansonella perstans.

ORGANISM 6: Mansonella streptocerca

GENERAL CHARACTERISTICS

COMMON NAME: None.

GEOGRAPHICAL DISTRIBUTION: West Africa.

PATHOGENESIS: Pruritic rash.

HABITAT: Cutaneous tissue of the body trunk.

VECTOR: Culicoides species.

RESERVOIR HOST: Chimpanzees.

INFECTIVE FORM: Filariform larva.

MODE OF INFECTION: Inoculation.

PERIODICITY: None.

SPECIMEN OF CHOICE: Skin biopsies.

SPECIMEN PROCESSING: Giemsa's.or Hematoxylin/Eosin stains.

Figure 4-58. Information on Mansonella streptocerca.

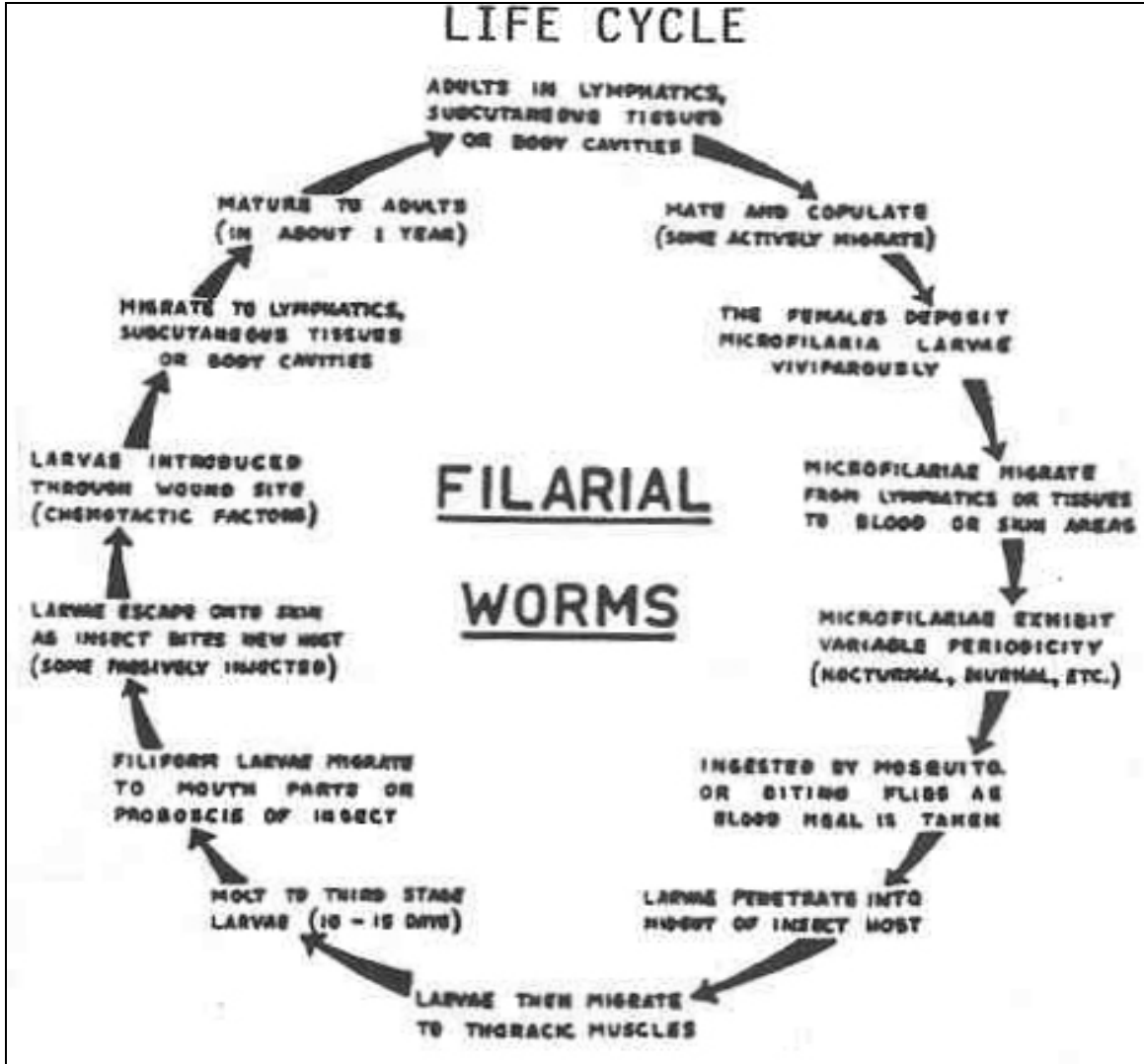


Figure 4-59. Life cycle of Mansonella streptocerca.

Mansonella streptocerca

MICROFILARIA

SIZE: 180 to 240 μ .

SHEATH: Absent.

TAIL: Blunt, bent in a shepherd's.crook.

TERMINAL NUCLEI: Extend to.the tip of the tail.




Figure 4-60. Microfilaria stage of Mansonella streptocerca.

ORGANISM 7: Onchocerca volvulus

GENERAL CHARACTERISTICS

COMMON NAME: Blinding filariasis, river blindness.

GEOGRAPHICAL DISTRIBUTION: Central and northern South America and Africa.

PATHOGENESIS: Cutaneous nodules, ocular lesions, pectoral pain, blindness.

HABITAT: Cutaneous and subcutaneous tissues.

VECTOR: Simulium species.

RESERVOIR HOST: None.

INFECTIVE FORM: Filariform larva.

MODE OF INFECTION: Inoculation.

PERIODICITY: None.

SPECIMEN OF CHOICE: Tissue biopsies.

SPECIMEN PROCESSING: Giemsa's or Hematoxylin/Eosin stains.

Figure 4-61. Information on Onchocerca volvulus.

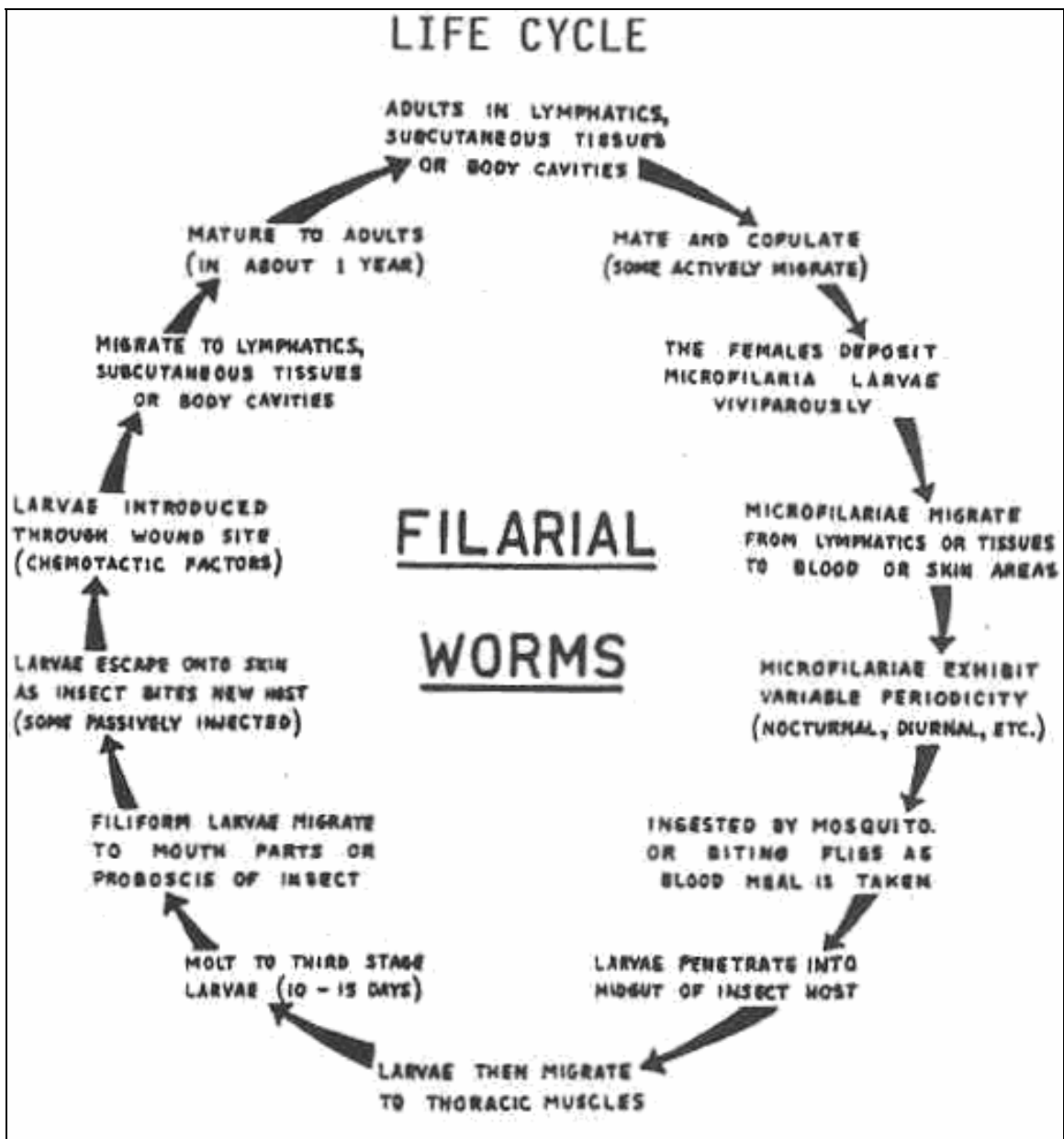


Figure 4-62. Life cycle of Onchocerca volvulus.

Onchocerca volvulus

MICROFILARIA

SIZE: 220 to 260 μ .

SHEATH: Absent.

TAIL: Blunt and slightly curved.

TERMINAL NUCLEI: Do not extend to the tip of the tail.




Figure 4-63. Microfilaria stage of Mansonella streptocerca.

ORGANISM 8: Dirofilaria immitis

GENERAL CHARACTERISTICS

COMMON NAME: Dog heartworm.

GEOGRAPHICAL DISTRIBUTION: Worldwide, prevalent in tropics and subtropics.

PATHOGENESIS: In dogs: chronic endocarditis; in humans: granulomas and pneumonitis.

HABITAT: Heart and lungs.

VECTOR: Mosquitoes.

RESERVOIR HOST: Dogs, which are the definitive hosts.

INFECTIVE FORM: Filariform larva.

MODE OF INFECTION: Inoculation.

PERIODICITY: None.

SPECIMEN OF CHOICE: Blood.

SPECIMEN PROCESSING: Giemsa's or Hematoxylin/Eosin stains.

Figure 4-64. Information on Dirofilaria immitis.

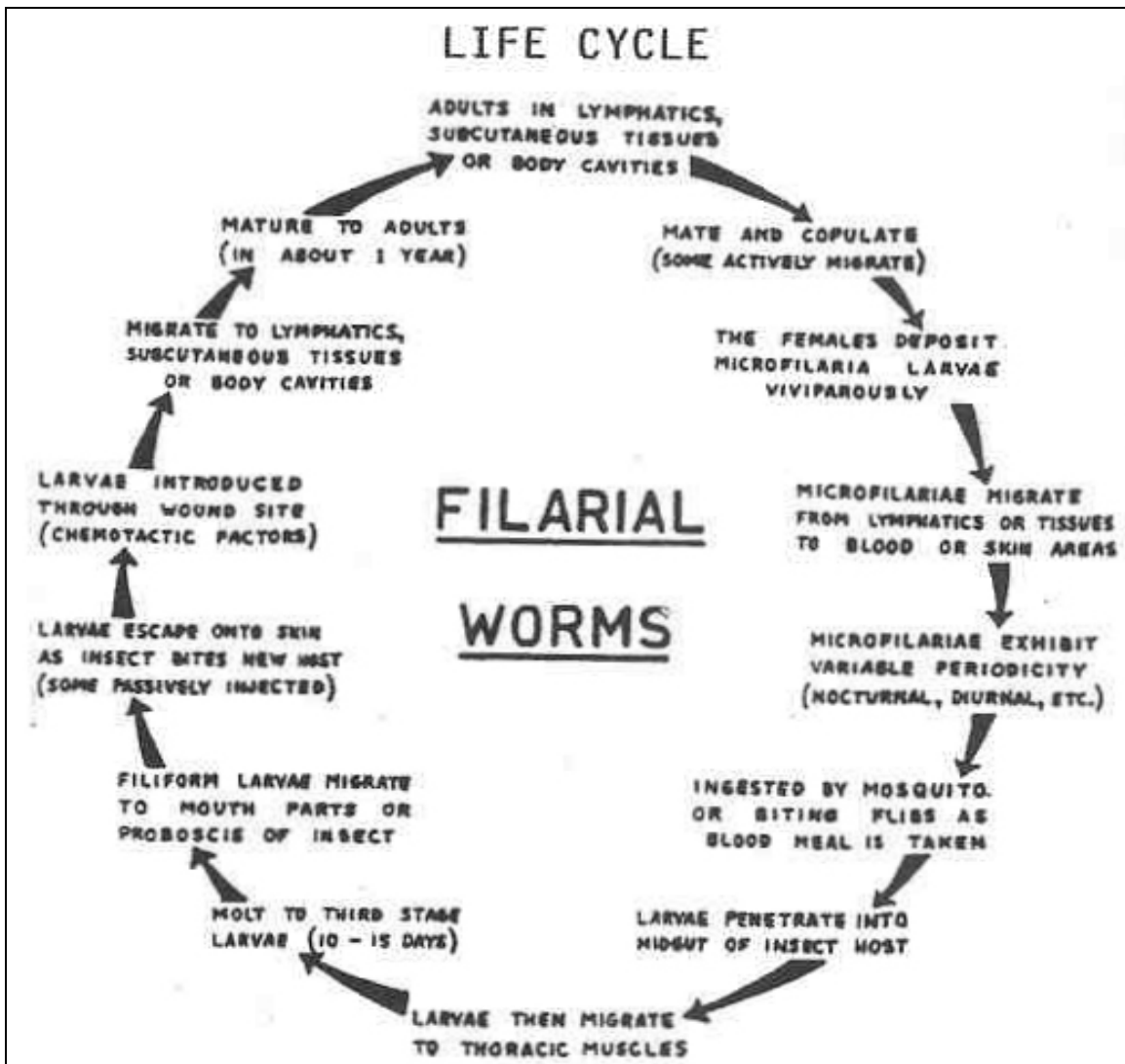


Figure 4-65. Life cycle of Dirofilaria immitis.

Dirofilaria immitis

MICROFILARIA

SIZE: 285 to 315 μ .

SHEATH: Absent.

TAIL: Slender and pointed.

TERMINAL NUCLEI: Do not extend to the tip of the tail.




Figure 4-66. Microfilaria stage of Dirofilaria immitis.

ORGANISM 9: Dirofilaria conjunctivae

GENERAL CHARACTERISTICS

A group of non-patent Dirofilariae.

COMMON NAME: None.

GEOGRAPHICAL DISTRIBUTION: Worldwide, endemic in the USA.

PATHOGENESIS: Tumors and abscesses in various anatomical sites not completely understood.

HABITAT: Various anatomical sites.

VECTOR: Mosquitoes.

RESERVOIR HOST: Raccoons and dogs, which are the definitive hosts.

INFECTIVE FORM: Filariform larva.

MODE OF INFECTION: Inoculation.

PERIODICITY: None.

SPECIMEN OF CHOICE: Biopsies.

SPECIMEN PROCESSING: Giemsa's or Hematoxylin/Eosin stains.

Figure 4-67. Information on Dirofilaria conjunctivae.

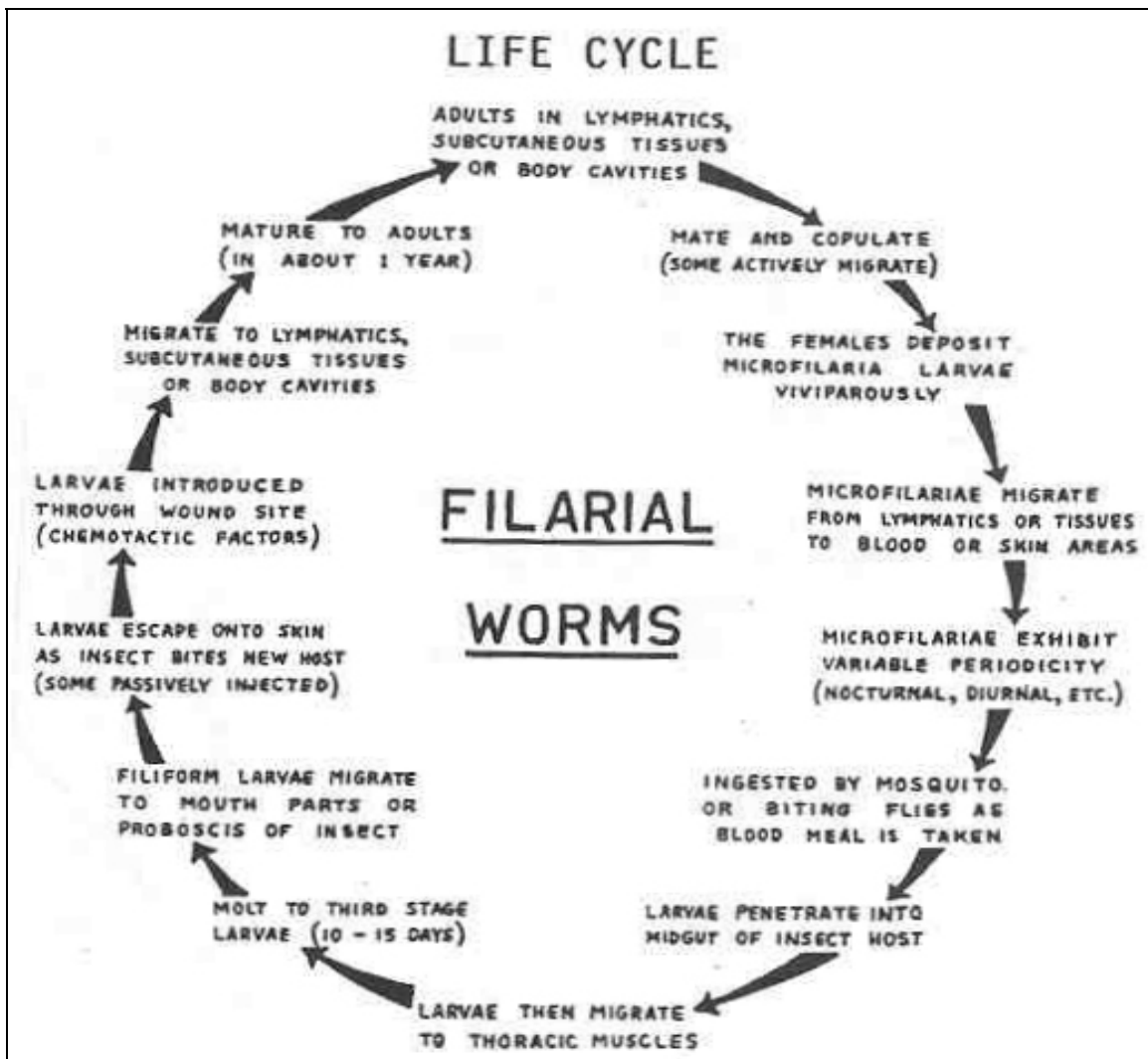


Figure 4-68. Life cycle of Dirofilaria conjunctivae.

Dirofilaria conjunctivae

MICROFILARIA

The identification criteria of this group of organisms have not been established because they vary within the species

Figure 4-69. Microfilaria stage of Dirofilaria conjunctivae.

Section II. PHYLUM ACANTHOCEPHELINTHES

4-4. GENERAL DESCRIPTION

This phylum was once considered a class of the phylum Aschelminthes. The species in this phylum are all parasitic and there are two potential pathogens to man: Macracanthorhynchus hirudinaceus, and Moniliformis moniliformis. They are commonly known as thorny headed worms. Some writers believe that this phylum is an evolutionary link between the flat and the round worms. The worms have an anterior retractile armed proboscis with 5 to 6 rows of spines. The digestive tract is absent and they absorb nutrients through the skin. The cuticle is folded and creased showing some pseudosegmentation. Only Macracanthorhynchus hirudinaceus will be presented in this text.

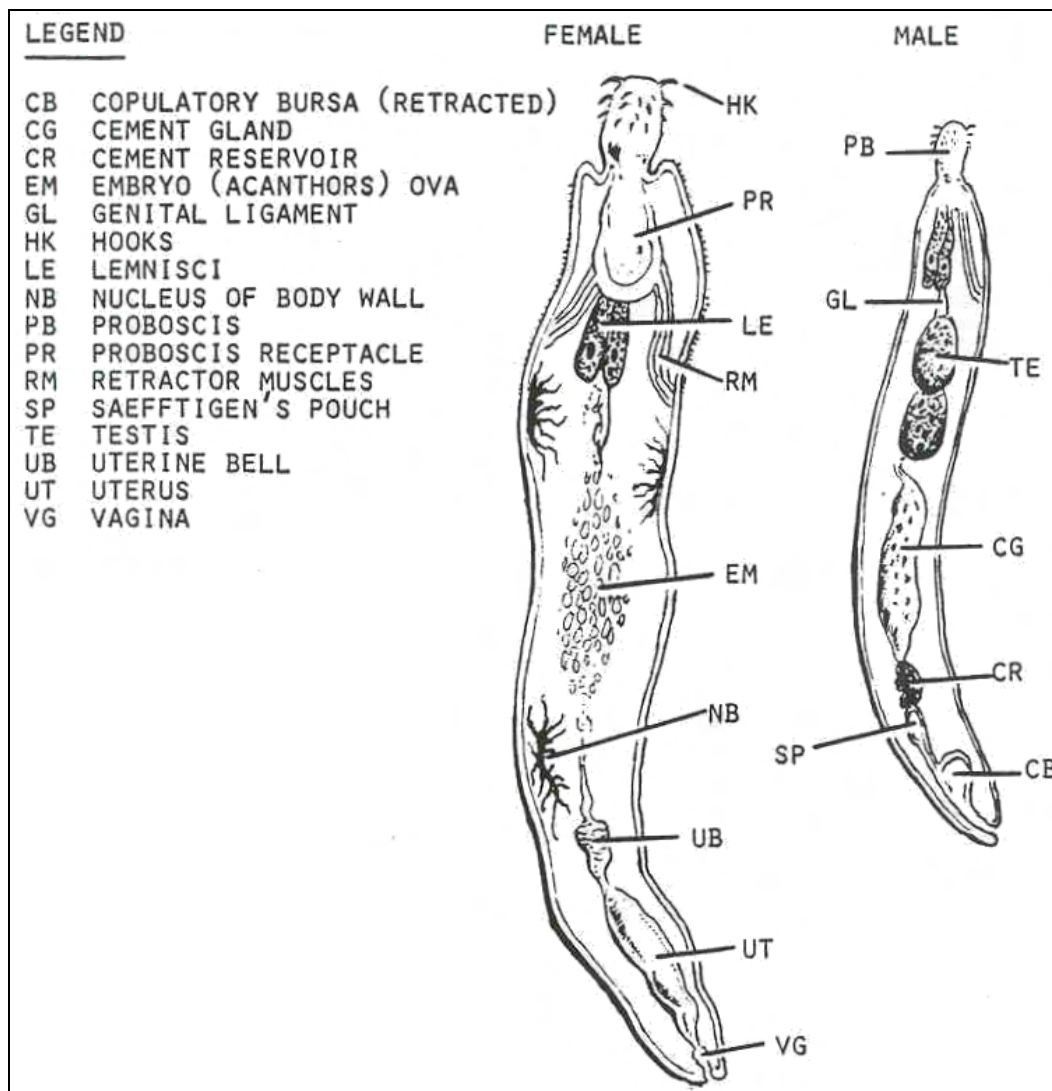


Figure 4-70. Morphology of Acanthocephalans.

4-5. MACRACANTHORHYNCHUS HIRUDINACEUS

This organism has been called the giant thorny-headed worm. Although little clinical history is available concerning acanthocephalan infections in humans, varying degrees of inflammation along the intestinal mucosa have been described. Oleoresin of aspidium has been successfully employed as a treatment for adults, while mebendazole is recommended for children. The geographical distribution of this organism is worldwide.

ORGANISM: Macracanthorhynchus hirudinaceus

GENERAL CHARACTERISTICS

HABITAT: Small intestines.

INTERMEDIATE HOST: Beetle larvae (grubs).

RESERVOIR HOST: Swine (usual definitive host).

INFECTIVE FORM: Cystacanth.

MODE OF INFECTION: Ingestion.

Figure 4-71. Information on Macracanthorhynchus hirudinaceus.

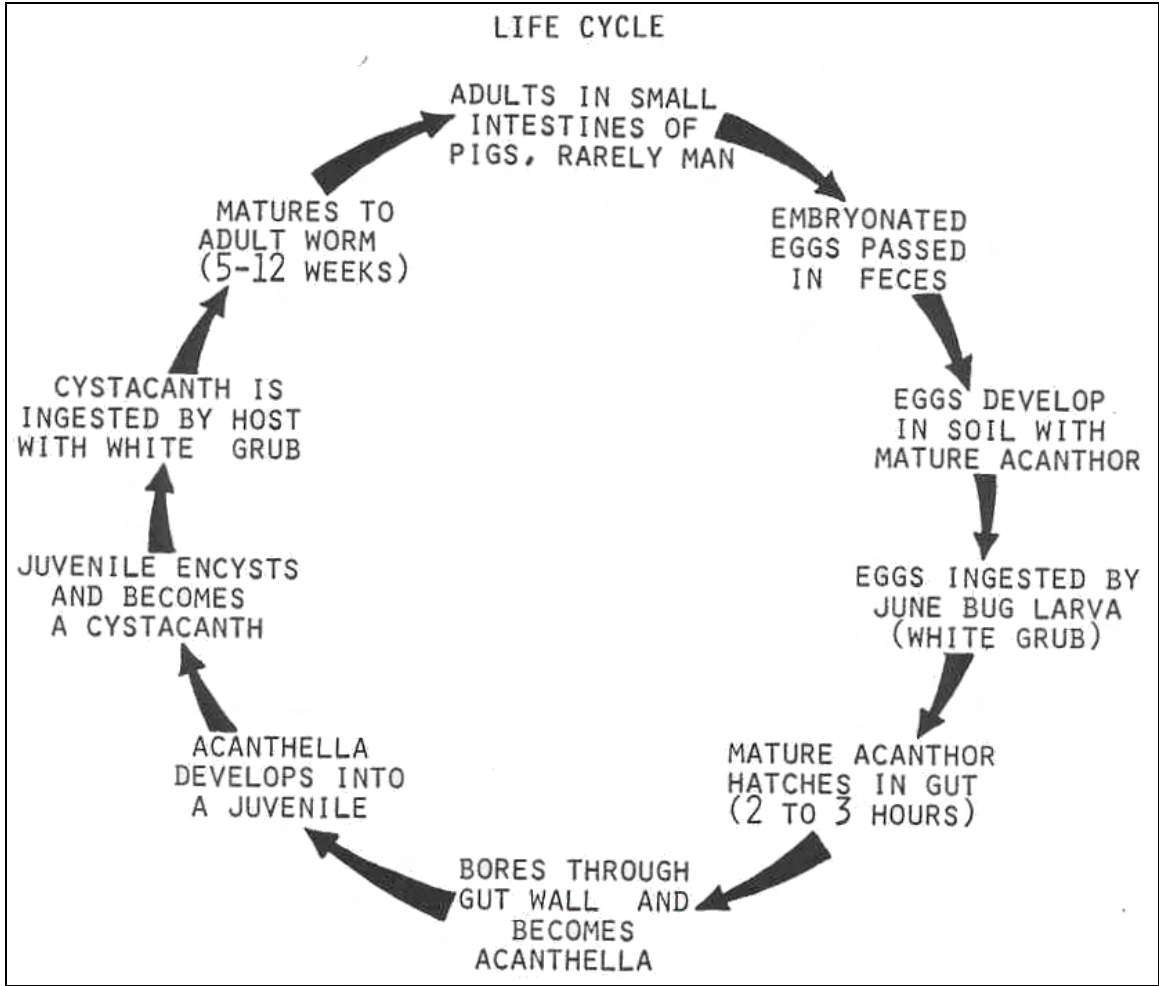


Figure 4-72. Life cycle of Macracanthorhynchus hirudinaceus.

Macracanthorhynchus hirudinaceus

OVA

SIZE: 60 x 90 μ .

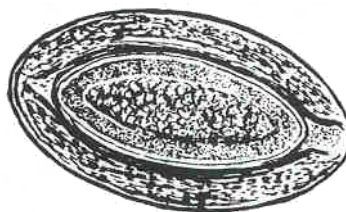
SHAPE: Ellipsoidal.

COLOR: Brown.

OPERCULUM: Absent.

CONTENT: Acanthor larva.

SHELL WALL: Heavy with three embryonic layers.



ADULT

SIZE

MALE: 50 to 100 by 4 mm.

FEMALE: 200 to 650 by 7 mm.

SHAPE: Flattened ventrodorsally; cylindrical when preserved; pseudosegmented.

COLOR: Milky white.

RETRACTILE ARMED PROBOSCIS: 5 to 6 rows of spines.

DIGESTIVE SYSTEM: Absent.

CUTICLE: Folded and creased.

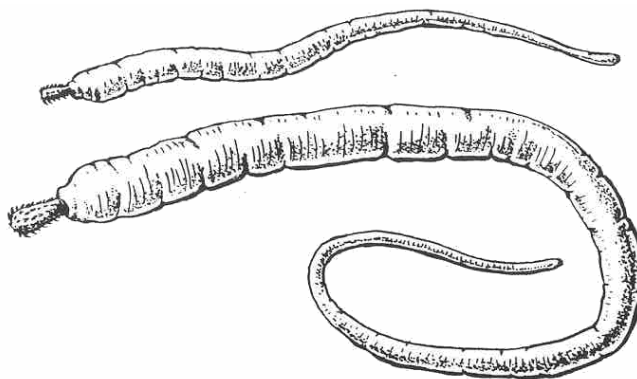


Figure 4-73. Stages of Macracanthorhynchus hirudinaceus.

Section III. ARTHROPOD AND VECTORS

4-6 GENERAL COMMENTS

The role of various species of insects, lice, ticks, mites and other arthropods as vectors of disease, or as agents directly responsible for human discomfort, is of considerable significance in the study of parasites. Indeed, many of the parasites presented in the previous sections depend solely upon arthropods as a means of transmission from one host to another. For example, copepods are the intermediate hosts in the life cycles of the fish tapeworm, Diphyllobothrium latum, Spirometra species and the guinea worm, Dracunculus medinensis; the female anopheline mosquitoes are responsible for carrying the dreaded malarial parasites; African trypanosomiasis could not be transmitted without the lowly tsetse fly, and Chagas' disease would be nearly eradicated if it were not for the blood sucking family of reduviid bugs.

4-7. MORPHOLOGICAL CHARACTERISTICS

Because of their involvement in the establishment of various disease entities, it is desirable that the parasitology technician recognizes the overt appearance of various arthropod species and be able to identify certain general morphological characteristics. The following pages contain illustrations of the prominent features of some of the most important arthropod vectors and agents. See figures 4-74 through 4-78.

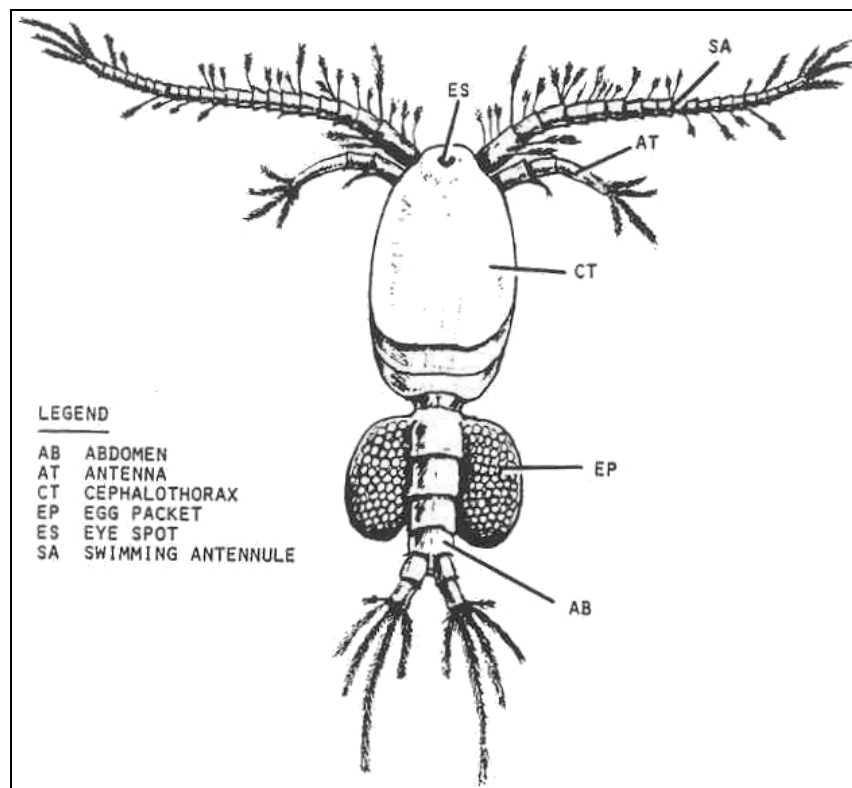


Figure 4-74. Morphology of a copepod.

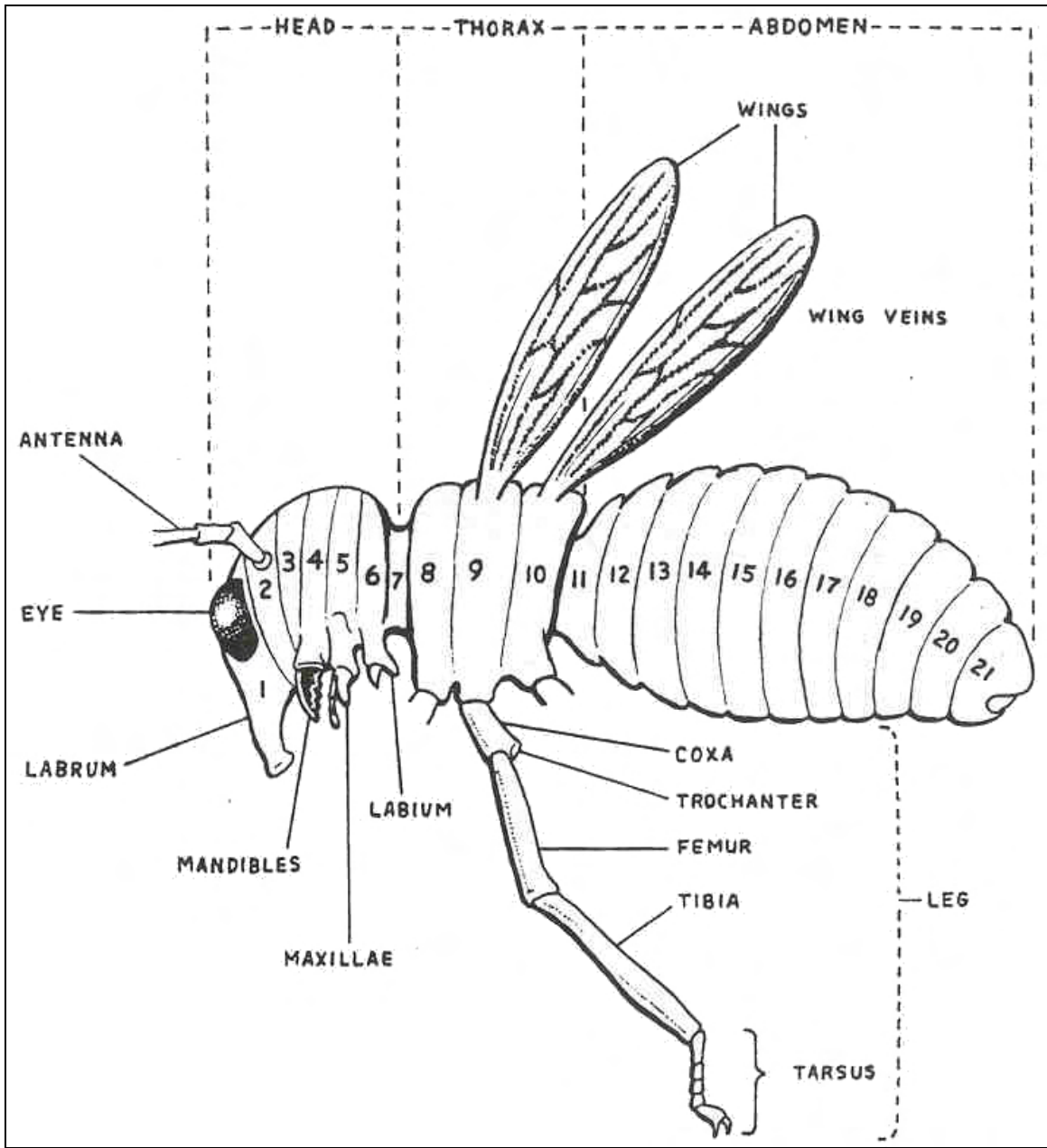


Figure 4-75. Diagram of a primitive insect.

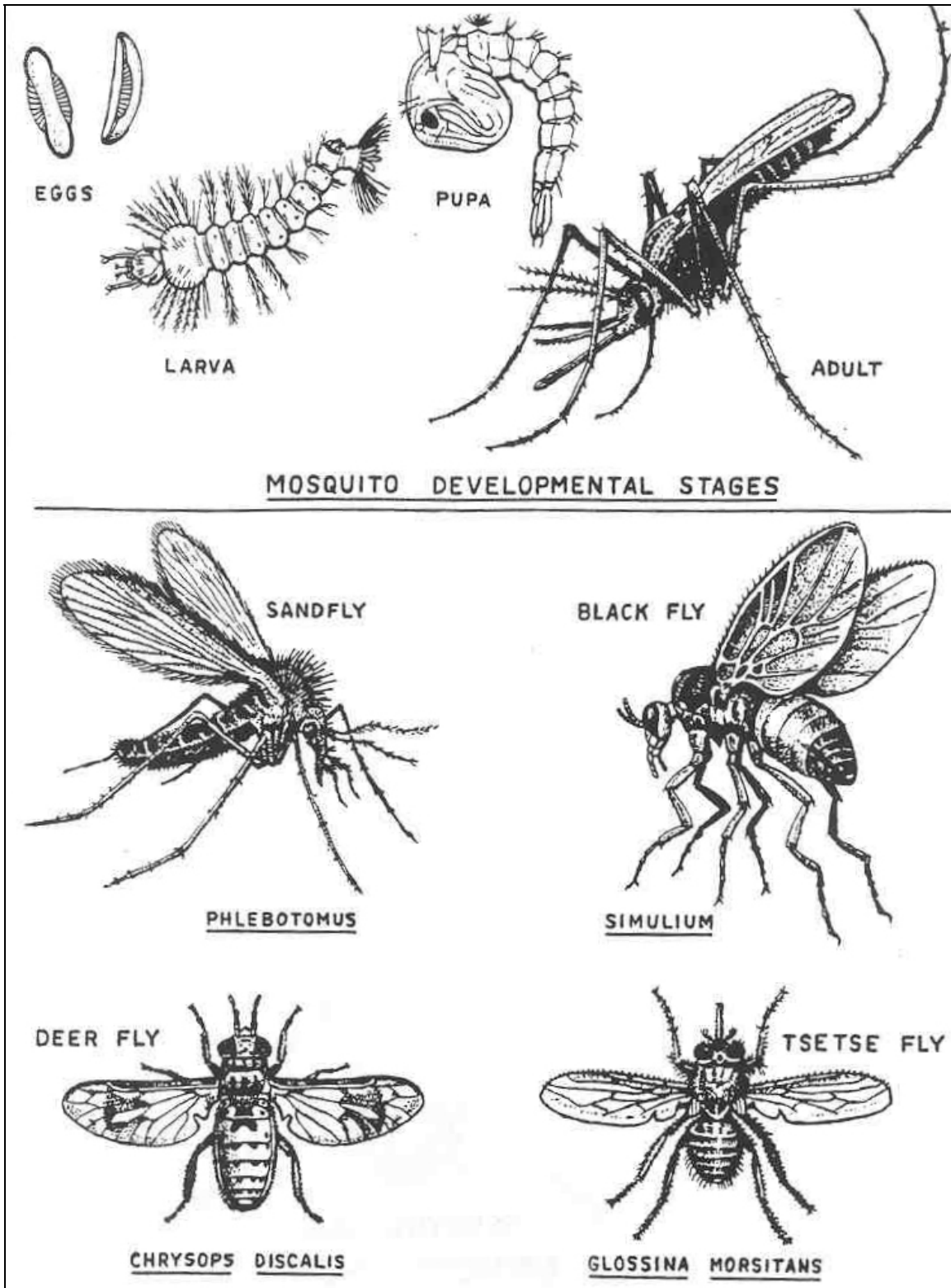


Figure 4-76. Examples of common arthropod vectors.

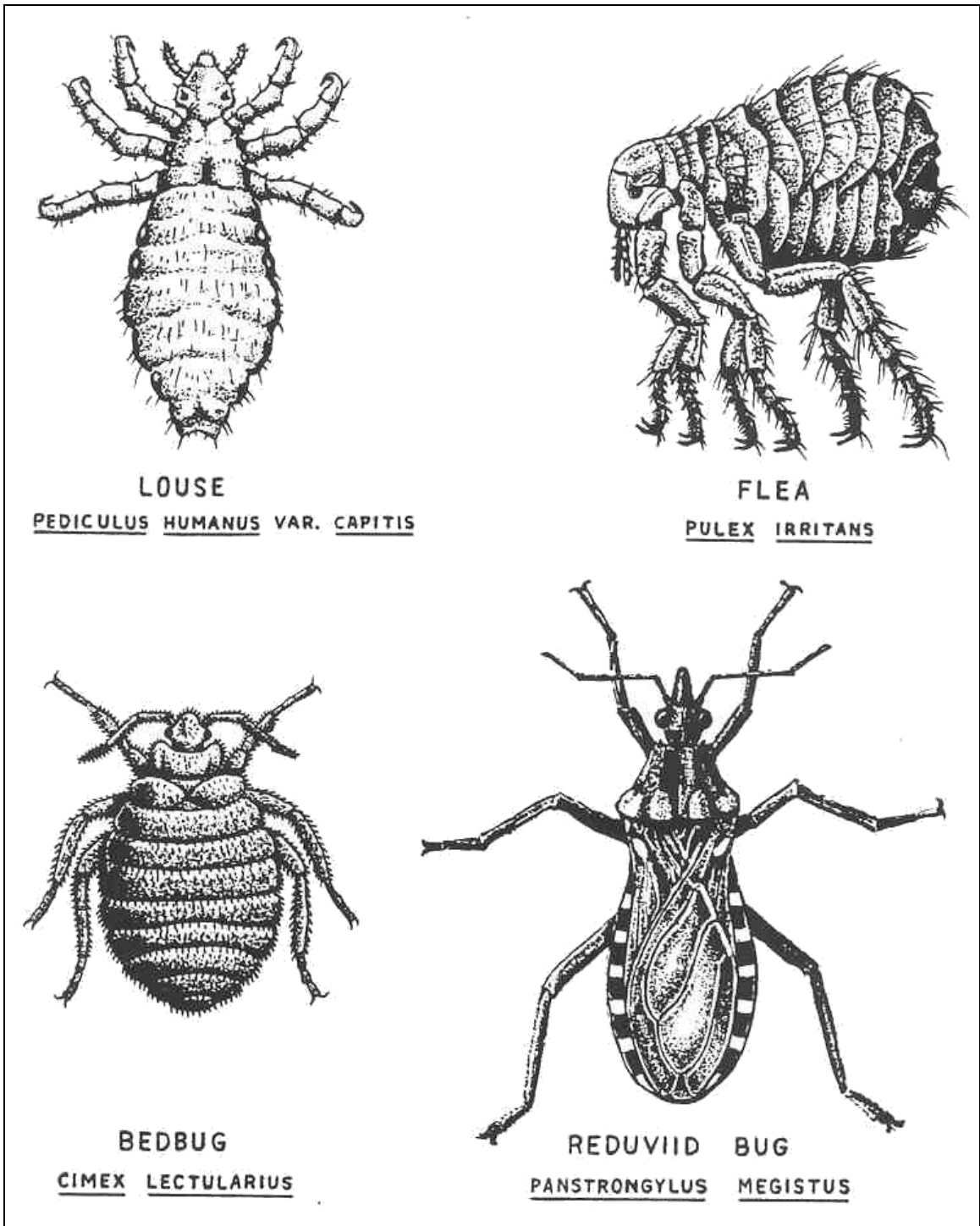


Figure 4-77. Examples of common arthropod vectors.

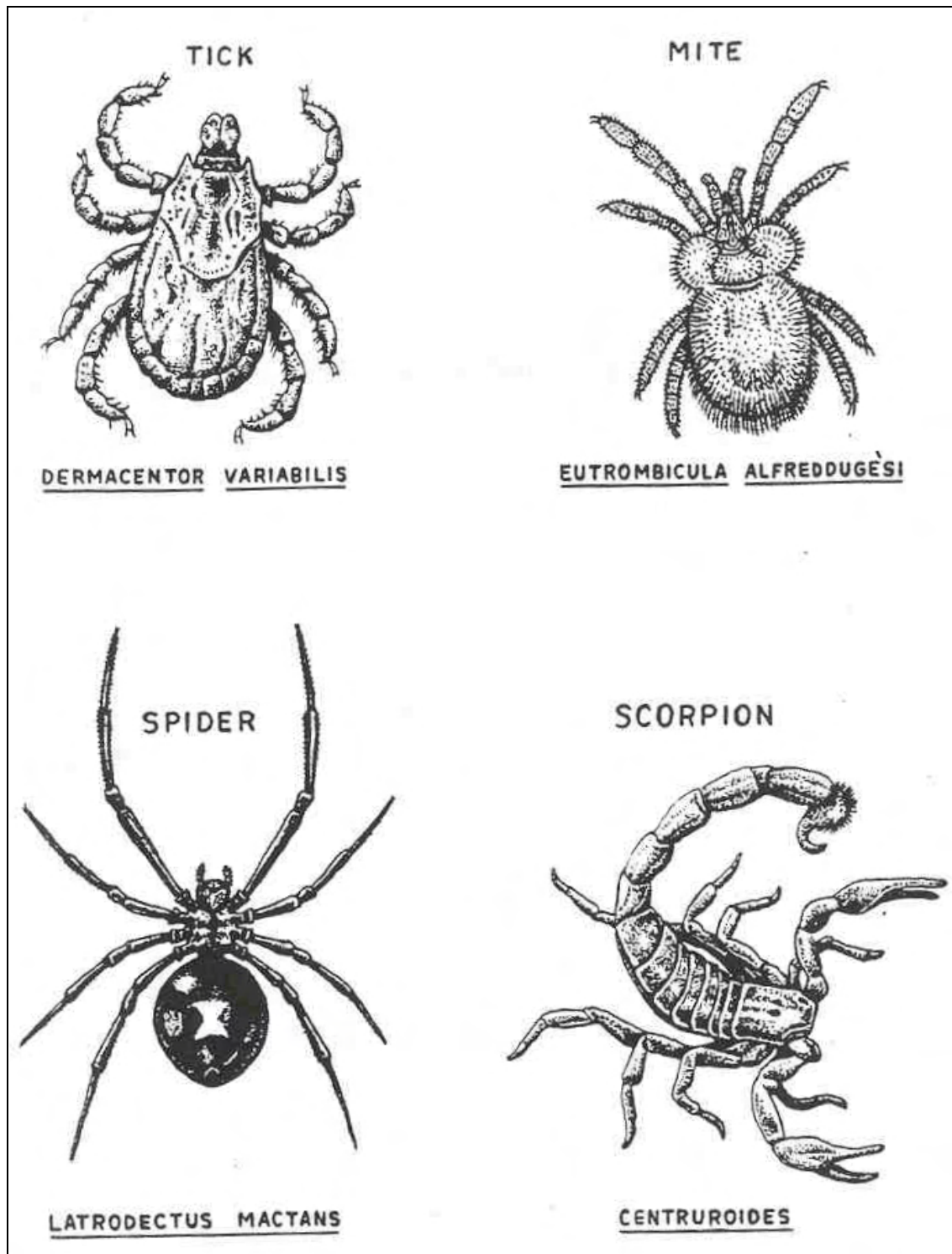


Figure 4-78. Examples of common arthropod vectors.

[Continue with Exercises](#)

EXERCISES, LESSON 4

INSTRUCTIONS: Answer the following exercises by marking the lettered response that best answers the exercise, by completing the incomplete statement, or by writing the answer in the space provided at the end of the exercise.

After you have completed all the exercises, turn to "Solutions to Exercises" at the end of the lesson and check your answers. For each exercise answered incorrectly, reread the material referenced with the solution.

1. Which of the following is true of members of the Phylum Acanthocephelminthes?
 - a. All are parasitic.
 - b. Lack digestive organs.
 - c. Are considered as a class of Phylum Aschelminthes.
 - d. All of the above.

2. The habitat of Macracanthorhynchus hirudinaceus is the:
 - a. Connective tissue.
 - b. Large intestine.
 - c. Small intestine.
 - d. Liver.

3. Familiarity with the morphology of arthropod vectors is desirable because of their role in disease transmission.
 - a. True.
 - b. False.

4. Which of the following statements best describe a characteristic of the Class Nematoda?
 - a. The reproductive system is monoecious.
 - b. Contains most of the round worms parasitic to man.
 - c. The cuticle is used for attachment to the host.
 - d. The males are smaller than the females.

5. An indication of fertilization of the eggs of Ascaris lumbricoides is:
 - a. When the eggs become corticated.
 - b. When the yolk mass is pulled away from the shell wall.
 - c. When the eggs become decorticated.
 - d. When the yolk mass fills the egg.

6. The organism which is most prevalent in helminth infections is:
 - a. Trichuris trichiura.
 - b. Ascaris lumbricoides.
 - c. Necator americanus.
 - d. Taenia solium.

7. What is the infective form of Enterobius vermicularis?
 - a. Cercaria.
 - b. Embryonated egg.
 - c. Filariform larva.
 - d. Encysted larva.

8. The common name for Trichuris trichiura is:
- Pinworm.
 - Hookworm.
 - Whipworm.
 - Threadworm.
9. The organism responsible for creeping eruption is:
- Toxocara canis.
 - Strongyloides stercoralis.
 - Trichinella spiralis.
 - Ancylostoma species.
10. Which of the following organisms is frequently associated with visceral larval migrans?
- Trichinella spiralis.
 - Toxocara species.
 - Dracunculus medinensis.
 - Trichostrongylus species.
11. A characteristic of blood and tissue nematodes is:
- Specificity for human intestines.
 - A microfilaria stage.
 - A rhabditiform stage.
 - Cephalic cone.

12. The definitive host of Dirofilaria conjunctivae is a:
- a. Raccoon.
 - b. Gorilla.
 - c. Mosquito.
 - d. Monkey.
13. Man acquires an infection of Necator americanus by:
- a. Ingestion.
 - b. Inoculation.
 - c. Active penetration.
 - d. All of the above.
14. The nematode which is capable of two different life cycles is:
- a. Strongyloides stercoralis.
 - b. Toxocara species.
 - c. Loa loa.
 - d. Taenia solium.
15. Trichinella spiralis infections are most likely to occur in:
- a. Tropical climates.
 - b. Pork eating countries.
 - c. The Western hemisphere.
 - d. Cold climates.

16. Which of the following characteristics helps to distinguish the filariform larvae of Trichostrongylus species?
- a. A large genital primordium.
 - b. The caudal bulb.
 - c. A short buccal cavity.
 - d. None of the above.
17. Which of the following is a morphological characteristic of adult males of Capillaria philippinensis?
- a. A light yellow color of the cuticle.
 - b. A sharp anterior spear process.
 - c. Caudal alae.
 - d. All of the above.
18. What is the specimen source required to recover the eggs of Capillaria hepatica?
- a. Sputum.
 - b. Feces.
 - c. Perianal swab.
 - d. Liver biopsy.
19. Adults of Ancylostoma duodenale exhibit:
- a. Three prominent tips.
 - b. A pair of cutting plates.
 - c. Two prominent pairs of teeth.
 - d. All of the above.

20. What specimen would you obtain to recover identification forms of Dracunculus medinensis?
- Exudate from irrigated lesions.
 - Liver biopsy.
 - Random fecal specimen.
 - None of the above.
21. One of the classic signs of disease caused by Bancroft's filaria is:
- Periorbital edema.
 - Elephantiasis.
 - Creeping eruption.
 - Perianal irritation.
22. Specimens being processed for the identification of blood or tissue nematodes are frequently stained with:
- Hematoxylin/Eosin stain.
 - Giemsa stain.
 - Hematoxylin/Eosin or Giemsa stain.
 - Hematoxylin/Eosin followed by Giemsa stain.
23. An unsheathed microfilaria with no somatic nuclei in the tip of the tail would be:
- Mansonella ozzardi.
 - Brugia malayi.
 - Mansonella streptocerca.
 - Mansonella perstans.

24. The specimen of choice for the recovery of microfilaria of Mansonella streptocerca is:
- a. Venous blood.
 - b. Skin biopsies.
 - c. Capillary blood.
 - d. Duodenal aspirates.
25. Which of the following characteristics aids in distinguishing adults of Macracanthorhynchus hirudinaceus from Ascaris lumbricoides?
- a. Body shape tapers to a slender posterior region.
 - b. Proboscis with 5 to 6 rows of spines.
 - c. Cuticle with folds and creases.
 - d. All of the above.

Check Your Answers on Next Page

SOLUTIONS TO EXERCISES, LESSON 4

1. a (para 4-4)
2. c (para 4-5)
3. a (para 4-6)
4. d (para 4-1)
5. b (para 4-2A; org 1)
6. b (para 4-2A; org 1)
7. b (para 4-2A; org 3)
8. c (para 4-2A; org 2)
9. d (para 4-2B; org 2)
10. b (para 4-2B; org 1)
11. b (para 4-3)
12. a (para 4-3; org 9)
13. c (para 4-2A; org 7)
14. a (para 4-2A; org 8)
15. b (para 4-2B; org 4)
16. b (para 4-2A; org 4)
17. d (para 4-2A; org 5)
18. d (para 4-2B; org 3)
19. c (para 4-2A; org 6)
20. a (para 4-3; org 5)

21. b (para 4-3; org 1)
22. c (para 4-3; org 1-5)
23. a (para 4-3; org 46)
24. b (para 4-3; org 66)
25. d (para 4-5)

End of Lesson 4

APPENDIX A

Clinical Manifestations and Treatment of the Common Parasitic Diseases

DISEASE	CAUSATIVE AGENT	SYMPTOMATOLOGY	PATHOLOGY	TREATMENT
INTESTINAL AND ATRIAL PROTOZOAN INFECTIONS				
Amoebiasis amoebic dysentery.	<u>Entamoeba</u> <u>histolytica</u> (amoeba)	<u>Asymptomatic</u> (carriers) <u>Incubation period</u> (1-14 weeks) vague unlocalized discomfort. <u>Intestinal symptoms</u> : abdominal pain, alternating diarrhea and constipation, dysentery (stools with blood, mucous). <u>Chronic-ulcerative colitis</u> : recurrent dysentery, gastrointestinal disturbances <u>Extraintestinal symptoms</u> : Fever (100 ^o to 102 ^o F), dehydration, toxemia, tenderness.	<u>Intestinal lesions</u> : ulcerative process (flask-like), regenerative proliferation of cells, secondary bacterial infection; amoebic granulomas (amoebomas). <u>Extraintestinal</u> : systemic amoebiasis, amoebic hepatitis (85 percent in right lobe), pulmonary abscess, fistulas, fissures, abscesses of brain and spleen.	Metronidazole (Flagyl), tetracycline, diiodohydroxyquin. Metronidazole dehydroemistine, emetine, plus chloroquine.
Amoebic dysentery.	<u>Dientamoeba</u> <u>fragilis</u> (flagellate)	Usually asymptomatic. Gastrointestinal disturbances. Persistent diarrhea.	Inflammation of intestinal mucosa.	Diiodohydroxyquin tetracycline.
Giardiasis.	<u>Giardia</u> <u>lamblia</u> (flagellate)	Usually asymptomatic, may be varied gastrointestinal symptoms, weight loss.	Catarrhal inflammation of mucosa, inhibits absorption of vitamin A and fats.	Quinacrine Metronidazole.
Trichomoniasis.	<u>Trichomonas</u> <u>vaginalis</u> (flagellate)	Usually asymptomatic, may be burning sensation, itching, frothy-creamy discharge.	Persistent vaginitis (toxicity), nonspecific urethritis, prostatovesiculitis.	Metronidazole (Flagyl).
Balantidiasis.	<u>Balantidium</u> <u>coli</u> (ciliate)	Alternating diarrhea and constipation, mucous, blood, pus, tender colon.	Necrotic ulcers (flask-like) abscesses of mucosa and submucosa, anemia.	Oxytetracycline, Diiodohydroxyquinoline, carbarsome or chlorotetracycline.
Coccidiosis.	<u>Isospora</u> <u>belli</u> (coccidians)	Usually asymptomatic, may be abdominal pain and discomfort, diarrhea, undigested food, steatorrhea, fever and weakness.	Inflammation of the intestinal mucosa.	No chemotherapy. Rest and bland diet.

DISEASE	CAUSATIVE AGENT	SYMPTOMATOLOGY	PATHOLOGY	TREATMENT
BLOOD AND TISSUE PROTOZOAN INFECTIONS				
Visceral leishmaniasis/kala-azar.	<u>Leishmania donovani</u> (flagellate)	Chills, fever, vomiting, malaise, protrusion of the abdomen, dyspnea.	Anemia, edema, hemorrhage of mucous membranes, hepatosplenomegaly, leukopenia.	Antimony compounds, stibogluconate, pentamidine.
Cutaneous leishmaniasis, oriental sore.	<u>Leishmania tropica</u> (flagellate)	Chills and fever, skin irritation.	Small, red papule; plague-like lesions, diffused; nodules; cellular infiltration; secondary lesions.	Quinacrine (early), Neostibosan (advanced).
Mucocutaneous leishmaniasis, Espundia, uta, Chiclero ulcer.	<u>Leishmania braziliensis</u> (flagellate)	Malaise, itching, fever, nasal obstruction.	Small red papule, granular lesion, lesions on the ear, ulceration of mucous membranes, necrosis, hyperchromic anemia.	Neostibosan. Pentamidine.
African trypanosomiasis; sleeping sickness.	<u>Trypanosoma brucei</u> (gambiense and rhodesiense) (flagellate)	Generalized pain, headache, fever, cramps, weakness, swollen lymph nodes, Winterbottoms' sign, retardation, lethargy.	Central Nervous System disorders, paralysis, convulsions, infiltration of tissue cells, diffused meningoencephalitis and meningomyelitis, heart failure.	Arsenicals, pentamidine or suramin (early), melarsoprol or tryparsamide (late).
American trypanosomiasis; Chagas' disease.	<u>Trypanosoma cruzi</u> (flagellate)	Chills; loss of strength, muscle and bone pain; swollen regional lymph nodes; swelling of preauricular lymph nodes (Romana's sign).	Proliferative inflammatory reactions; anemia; nervous disorders; edema of eyelid and conjunctiva; megaesophagus or megacolon; heart failure.	Chemotherapy not effective against tissue forms. Aminoquinolines (blood forms); Bayer 2502 and nitrofurans, amphotericin B (promising).
Toxoplasmosis.	<u>Toxoplasma gondii</u> (coccidian)	Usually asymptomatic. Congenital: stiff neck, retraction of head, spasticity, paralysis. Mild form: malaise, muscle pain, low fever, Acute: rash, high fever, chills, prostration, Chronic: vague, weakness, weight loss, headache, diarrhea.	Chorioretinitis, hydrocephaly, microcephaly, psychomotor disturbances, convulsions. Anemia, lymphadenopathy, lymphocytosis. Meningoencephalitis, hepatitis, pneumonitis, myocarditis. Retinochoroiditis, posterior uveitis.	Pyrimethamine plus Trisulfapyrimidines.

DISEASE	CAUSATIVE AGENT	SYMPTOMATOLOGY	PATHOLOGY	TREATMENT
BLOOD AND TISSUE PROTOZOAN INFECTIONS				
Primary Amebic Meningoencephalitis.	<u>Naegleria</u> spp. <u>Hartmanella</u> spp. <u>Acanthamoeba</u> spp. (Amoeba)	Severe frontal headache, sore throat, fever, blocked nose, stiff neck, Kernings sign; high WBC count.	CNS involvement with mortality in from 2-7 days; necrotic areas of meninges, brain and perivascular spaces.	Amphotericin B
Malaria, ague, paludism, intermittent fevers, marsh fever.	<u>Plasmodium</u> <u>vivax</u> <u>ovale</u> <u>malariae</u> <u>falciparum</u> (sporozoan)	<u>Acute stage</u> --intermittent febrile paroxysms (fever-chill cycle). <u>P. vivax</u> - 45 hours <u>P. ovale</u> - 49 hours <u>P. malariae</u> - 72 hours <u>P. falciparum</u> - 36-48 hours; temperature 103°-106°; headache (periocular pain); lethargy; lack of appetite, vague pains (joints). <u>Pernicious malaria</u> -- <u>P. falciparum</u> : nausea; vomiting, cyanosis, kidney dysfunction (oliguria or anuria); hematuria (blackwater-fever); Hemorrhages, cerebral involvement (coma, convulsions). <u>Chronic stages</u> : relapses, latency (benign), acquired immunity.	<u>Vascular Disorders</u> : erythrocytic destruction, anemia, blockages of capillaries, anoxemia. <u>Tissue disorders</u> : splenomegaly, impairment of parenchymal cells, edematous lesions (kidney, brain, cardiac muscles).	<u>Suppressive</u> : Chloroquine or amodiaquine and primaquine. <u>Uncomplicated</u> : Chloroquine or amodiaquine. <u>Severe</u> : Chloroquine hydrochloride or quinine dihydrochloride. <u>Prevention of relapses</u> : Primaquine. <u>Drug resistant</u> : Quinine sulfate plus pyrimethamine. Sulfadiazine. Dapsone. Fansidar. Mefloquine.
CESTODE INFECTIONS				
Taeniasis, beef tapeworm infection.	<u>Taeniarhynchus</u> <u>saginitatus</u> (tapeworm)	Frequently asymptomatic. Intestinal manifestations: abdominal pain and discomfort, diarrhea, loss of appetite (usually), nausea, vomiting.	Appendiceal mucosal lesions with secondary appendicitis, rare intestinal obstruction, moderate eosinophilia.	Niclosamide, or Quinacrine hydrochloride.

DISEASE	CAUSATIVE AGENT	SYMPTOMATOLOGY	PATHOLOGY	TREATMENT
CESTODE INFECTIONS				
Taeniasis, pork tapeworm infection, Cysticercosis.	<u>Taenia solium</u> (tapeworm and its larva)	Frequently asymptomatic. Intestinal manifestations: abdominal pain and discomfort, alternating diarrhea and constipation, loss of appetite Extraintestinal manifestations: faulty nutrition; headache; nervous disorders. Cysticercosis: vague symptoms; muscular pain; disorientation; epilepsy.	Inflammation of intestinal mucosa, intestinal perforation, anemia, eosinophilia, toxemia Cysticercal lesions (sequellae) fibrous capsules, CNS malfunction; chorioretinitis, blindness, lesions of brain; calcification in tissues.	Niclosamide, or Quinacrine hydrochloride, Compazine as antiemetic, Paramomycin, Surgery for cysticercal lesions when possible.
Dwarf tapeworm infection.	<u>Hymenolepis nana</u> (tapeworm)	Often asymptomatic. Intestinal manifestations: abdominal pain; vomiting; lack of appetite. Extraintestinal manifestations: general weakness (asthenia) headache and nervous disturbances.	Variable enteritis, secondary anemia, eosinophilia.	Niclosamide, Paramomycin.
Rat tapeworm infection.	<u>Hymenolepis diminuta</u> (tapeworm)	Generally asymptomatic. Vague intestinal disturbances of short duration.	No significant pathology.	Niclosamide, vermifuges.
Dipylidiasis, dog tapeworm infection ..	<u>Dipylidium caninum</u> (tapeworm)	Usually asymptomatic, Occassionally vague symptoms in children.	No significant pathology.	Niclosamide, vermifuges.
Hydatid disease, Echinococcosis.	<u>Echinococcus granulosus</u> (unilocular larval cyst) <u>Echinococcus multilocularis</u> (alveolar larval cyst) (tapeworm larva)	Benign in early disease. Increasing discomfort, dependent on location of cyst; Upper epigastric pain with the liver cysts; Coughing, dyspnea, thoracic pain with the lung cysts; intracranial pressure, epilepsy with cyst in the brain, kidney dysfunction, intermittent pain and hematuria with renal cysts. Anaphylactic symptoms with ruptured cysts.	Varies with the location of cysts. Inflammatory reactions, fibrous cysts; hemorrhage; pressure necrosis of tissue, hepatic cysts often in the right lobe; cysts also in lung, kidneys, bones, brain, and other organs; may metastasize like a cancer; secondary infections, eosinophilia. Prognosis-grave.	Surgery with accessible unilocular cysts, Chemotherapy and radiology ineffective.

DISEASE	CAUSATIVE AGENT	SYMPTOMATOLOGY	PATHOLOGY	TREATMENT
CESTODE INFECTIONS				
Diphyllobothriasis, fish tapeworm infection, dibothriocephalus anemia.	<u>Diphyllobothrium latum</u> (tapeworm)	Frequently asymptomatic. Intestinal manifestations: abdominal pain and discomfort digestive disorders, loss of appetite, nausea, vomiting. Extraintestinal manifestations: nervous disturbances, weakness, weight loss.	Intestinal obstruction, eosinophilia, toxemia, malnutrition, vitamin B ₁₂ deficiency, pernicious anemia.	Niclosamide, Quinacrine hydrochloride.
Sparganosis.	<u>Spirometra</u> spp. (tapeworm larva)	Localized pain in surrounding tissues, urticaria; erythema; chills and fever;	Inflammatory edema and necrosis of adjacent tissues; conjunctivitis; ocular inflammation, eosinophilia.	Surgical removal of plerocercoid larva.
TREMATODE INFECTIONS				
Opisthorchiasis.	<u>Opisthorchis</u> spp. (flukes)	Indigestion, epigastric discomfort, weakness; loss of weight, anemia; liver enlarged and tender; diarrhea.	Mechanical and toxic irritations, destruction of hepatic parenchyma, liver dysfunction, jaundice, adenomatous proliferation of tissue cells; liver cirrhosis.	Chloroquine phosphate (inhibits egg production), Chemotherapy not satisfactory in heavy infections.
Heterophyiasis.	<u>Heterophyes heterophyes</u> (fluke)	Usually mild symptoms. In heavy infections: abdominal pain, diarrhea.	In heavy infections: necrosis of intestinal mucosa; eosinophilia; egg embolis of heart or brain with varied tissue reactions.	Tetrachlorethylene; bephenium-hydroxynaphthoate.
Metagonimiasis.	<u>Metagonimus yokogawai</u> (fluke)	Similar to <u>H. heterophyes</u> . In heavy infection; abdominal discomfort, diarrhea.	Occasionally eggs may enter lymphatics or mesenteric venules causing granulomatous lesions in heart and nervous system.	Tetrachlorethylene; bephenium-hydroxynaphthoate.
Dicrocoeliasis.	<u>Dicrocoelium dentriticum</u> (fluke)	Digestive disturbances, flatulence; vomiting, biliary colic; epigastric pain; chronic constipation or diarrhea.	Inflammation of biliary epithelium; biliary dysfunction, edema, toxemia.	Chloroquine or Dehydroemetine.
Paragonimiasis pulmonary distomiasis.	<u>Paragonimus westermani</u> (fluke)	Dry cough (early), pulmonary pain; rusty brown sputum (hemoptysis); low-grade fever.	Eosinophilia, fibrous tissue capsule, pleurisy, pneumonitis;	Bithonol, chloroquine-phosphate.

DISEASE	CAUSATIVE AGENT	SYMPTOMATOLOGY	PATHOLOGY	TREATMENT
TREMATODE INFECTIONS				
Fascioliasis, liver rot.	<u>Fasciola hepatica</u> (fluke)	Multiplicity of symptoms. Acute stage; headache, chills, fever, urticaria, tender liver. Chronic stage; substernal pain, digestive disturbances, enlarged liver, jaundice.	Eosinophilia; anemia (0.2 ml blood loss per worm per day), biliary obstruction, metabolic toxicity, adenomatous and fibrotic changes, parenchymal atrophy, cirrhosis (periportal).	Bitinol, dehydroemetine dihydrochloride.
Fasciolopsiasis.	<u>Fasciolopsis buski</u> (fluke)	Epigastric pain, nausea, vomiting, diarrhea.	Local inflammation, ulceration and abscesses; generalized massive edema obstruction; eosinophilia up to 35%.	Tetrachlorethylene; Hexylresorcinol.
Amphistomiasis.	<u>Gastrodicoides hominis</u> (fluke)	Mild irritations, diarrhea.	Mucosal inflammation of cecum and ascending colon.	Tetrachlorethylene.
Echinostomiasis.	<u>Echinostoma</u> spp. (fluke)	Generally, no significant symptoms. Occasional abdominal pain and diarrhea.	Heavy infections induce catarrhal inflammation.	Tetrachlorethylene.
Schistosomiasis, Intestinal bilharziasis, Schistosomal dysentery.	<u>Schistosoma mansoni</u> (blood fluke)	Skin penetration--initial signs: itching ("swimmers itch"), rash. Intestinal manifestations: abdominal discomfort, diarrhea, occult blood. Chronic disease: varied symptoms, weight loss, lack of appetite, chills, fever, sweating, liver and spleen tenderness.	Initial phase: transient pruritis, toxemia, eosinophilia. Infiltration of vital organs: hemorrhages, anemia (hypochromic) hepatomegaly, liver cirrhosis, splenomegaly, cellular infiltration; fibrous tissue proliferation; ulcerations.	Antimonials except in hepatic disease, Potassium or sodium antimony tartrate, Stibophen.
Oriental schistosomiasis, Katayama disease.	<u>Schistosoma japonicum</u> (blood fluke)	Skin penetration: dermatitis Intestinal manifestations: abdominal discomfort, diarrhea, occult blood. Chronic disease: varied symptoms, weight loss, anemia, liver and spleen involvement, neurological and pulmonary symptoms from invading eggs.	Initial phase: transient pruritis, toxic and allergic reactions, subcutaneous edema, eosinophilia Infiltration of vital organs: eggs, severe lesions (more severe than with <u>S. mansoni</u>), liver fibrosis, splenomegaly, systemic involvement (embolic eggs), cellular infiltration, ulcerations.	Antimonials, Potassium antimony tartrate.

DISEASE	CAUSATIVE AGENT	SYMPTOMATOLOGY	PATHOLOGY	TREATMENT
CESTODE INFECTIONS				
Vesical schistosomiasis, urinary bilharziasis, Schistosomal hematuria.	<u>Schistosoma haematobium</u> (blood fluke)	Skin penetration: itching, suprapubic-urinary signs: pain, painful micturition. Chronic disease: temperature, varied symptoms.	Toxic irritations, eosinophilia, tissue changes, lesions of urinary bladder and genitalia; cystitis; occlusions (ureters, urethra), hematuria.	Niridazole, Antimony sodium dimercaptosuccinate, Stibophen.
Schistosome dermatitis, Swimmer's itch, Clam digger's itch.	<u>Schistosoma</u> spp. <u>Trichobilharzia</u> spp. <u>Microbilharzia</u> spp. (larva of avian blood flukes)	Skin irritation, severe itching.	Urticaria, acute inflammation in epithelial layers. Secondary bacterial infection.	Antipruritic and antihistaminic lotions.
NEMATODE INFECTIONS				
Enterobiasis, Pinworm infection.	<u>Enterobius vermicularis</u> (roundworm)	Perianal irritation, itching abdominal discomfort, weight loss.	Slight eosinophilia (4-12 percent); secondary infections.	Pyrantel pamoate, Piperazine citrate, or Pyrvinium pamoate.
Ascariasis, Roundworm infection.	<u>Ascaris lumbricoides</u> (roundworm)	Frequently asymptomatic. Intestinal manifestations: loss of appetite, abdominal pain and discomfort, nausea and vomiting, diarrhea or constipation, loss of weight.	Enteritis-inflammation, obstruction; toxicity, eosinophilia, hemorrhage, trauma by penetrating adults.	Piperazine citrate, Pyrantel pamoate.
Visceral larval migrans.	<u>Ascaris</u> spp. <u>Toxocara</u> (roundworm larva)	Intermittent abdominal pain, chest pains; pain associated with other varied sites, fever, nausea and vomiting.	Granulomatous lesions of liver, lungs and other organs; Eosinophilia; anemia; hepatomegaly; pneumonitis; dermatitis, neurologic disturbances, tumors of the eyes, spinal cord and heart in severe cases.	Corticosteroids (prednisone), diethylcarbamazine or thiabendazole.
Trichuriasis, Whipworm infection.	<u>Trichuris trichiura</u> (roundworm)	Frequently asymptomatic. But headache, fever, abdominal pain, nausea, vomiting, blood streaked diarrhetic stools, and weight loss may occur in heavy infections.	Eosinophilia, severe anemia, hemorrhage, rectal prolapse in extreme cases.	Mebendazole, thiabendazole or dithiazanine enema or hexylresorsinal.

DISEASE	CAUSATIVE AGENT	SYMPTOMATOLOGY	PATHOLOGY	TREATMENT
NEMATODE INFECTIONS				
Hookworm infection, Ancylostomiasis, Necatoriasis, Uncinariasis.	<u>Ancylostoma duodenale</u> <u>Necator americanus</u> (roundworms)	At site of penetration: "ground itch," sensitization Intestinal manifestations: appetite (enormous or poor), nausea, vomiting, diarrhea or constipation, bloody stools. Extraintestinal manifestations: weakness, dizziness, pulmonary distress, allergic symptoms.	Anemia (chronic nutritional deficiency type), eosinophilia, erythema, dyspnea, bronchitis, pneumonitis.	Pyrantel pamoate; Tetrachlorethylene; or Thiabendazole; Bephenium hydroxynaphthoate when <u>Ascaris</u> is also present.
Cutaneous larval migrans, Creeping eruption.	<u>Ancylostoma braziliense</u> other <u>Ancylostoma</u> Other Hookworm species (roundworm larva)	Itching: intense irritation of the skin at the site of entry of larvae; other skin complications.	Eosinophilia; cellular infiltration, reddish serpiginous intracutaneous tunnels, secondary bacterial infections.	Thiabendazole Freezing ectopically with chloride or carbon dioxide snow.
Strongyloidiasis, Cochin China dysentery.	<u>Strongyloides stercoralis</u> (roundworm)	Often asymptomatic: Gastrointestinal manifestations: midepigastic pain, nausea, vomiting, diarrhea or constipation, chronic dysentery. Extraintestinal manifestations: weight loss, low-grade fever.	Chronic gastrointestinal inflammation, eosinophilia, anemia, secondary bacterial infections, biliary and pancreatic inflammation.	Thiabendazole; Pyrvinium pamoate.
Trichostrongyliasis.	<u>Trichostrongylus</u> species (roundworm)	Usually asymptomatic: vague abdominal disturbances in heavy infections.	In heavy infections: inflammation of the intestinal mucosa and gallbladder, secondary anemia, transient eosinophilia.	Thiabendazole; Pyrantel pamoate.
Capillariasis.	<u>Capillaria hepatica</u> <u>Capillaria philippinensis</u> (roundworm)	Diarrhea, weakness, abdominal distention and pain, malabsorption.	Inflammation of the liver (<u>C. hepatica</u>) and intestine (<u>C. philippinensis</u>), tissue destruction, cardiac abnormalities.	Thiabendazole. Mebendazole.

DISEASE	CAUSATIVE AGENT	SYMPTOMATOLOGY	PATHOLOGY	TREATMENT
NEMATODE INFECTIONS				
Trichinosis. Trichinelliasis.	<u>Trichinella spiralis</u> (roundworm larva and adults)	Varied pain and tenderness of muscles and joints; headache, fever, nausea, vomiting, diarrhea, edema, weakness; involvement of eye, heart, respiratory system, and central nervous system cause many varied symptoms.	Larval invasion of striated muscle and vital organs, eosinophilia, acute interstitial inflammation, pneumonitis, pleurisy, encephalitis, meningitis, nephritis, deafness, peritonitis, eye and brain trauma, myocarditis.	No effective chemotherapy; rest, fluids, Salicylates relieve muscle symptoms; Thiabendazole.
Bancroftian filariasis. Wuchereriasis elephantiasis.	<u>Wuchereria bancrofti</u> (blood and tissue roundworm)	Asymptomatic (early infection); Enlargement of lymph nodes. Acute stage: fever, chills, headache, vomiting; general malaise, Systemic allergic symptoms. Obstructive disease: enlargement of affected body regions usually as a result of repeated infections with fever and pain.	Eosinophilia; epididymitis; orchitis; lymphangitis; Abscesses of pelvis, kidney, scrotum, inguinal nodes and varied tissues from dead worms. Acute granulomatous inflammation in lymphatics due to worms and by products; lymphedema and lymphangitis of the genitalia, breast or extremities resulting in elephantiasis.	Diethylcarbamazine
Malayan filariasis.	<u>Brugia malayi</u> (blood and tissue roundworm)	Asymptomatic carriers; enlargement of lymph nodes and affected body regions much like <u>W. bancrofti</u> .	Eosinophilia; lymphangitis and elephantiasis as with <u>W. bancrofti</u> .	Diethylcarbamazine
Loasis, eyeworm infection, calabar.	<u>Loa, loa</u> (blood and tissue roundworm)	Migration through subcutaneous tissues and orbital conjunctiva causing irritation, pain and impaired vision; Calabar swellings.	Eosinophilia, edema, pruritis, dermatitis; abscesses from secondary pyogenic infections.	Diethylcarbamazine; surgical removal of adult.
Onchocerciasis.	<u>Onchocerca volvulus</u> (blood and tissue roundworm)	Filarial itch; thick wrinkled skin; dizziness; many varied symptoms by adult worms and trapped microfilaria eventually cause blindness; disfigurement and discoloration of the skin.	Eosinophilia; lesions of the subcutaneous tissues, skin and eyes; fibrous infiltration of host cells forming a capsule or nodule; hanging groin; elephantiasis; interference with Vitamin A metabolism.	Diethylcarbamazine plus suramin; Surgical removal of encapsulated adults.

DISEASE	CAUSATIVE AGENT	SYMPTOMATOLOGY	PATHOLOGY	TREATMENT
NEMATODE INFECTIONS				
Mansonelliasis. Ozzard's filariasis.	<u>Mansonella</u> <u>ozzardi</u> (blood and tissue round- worm)	Symptoms vague; not remarkable, Slight enlargement of lymph nodes.	Slight damage to peritoneal con- nective tissue.	Diethylcarbama- zine.
Mansonelliasis, dipetalonemiasis acanthochei- lonemiasis.	<u>Mansonella</u> <u>perstans</u> (blood and tissue round- worm)	Minor allergic phenomena, Slight enlargement of lymph nodes.	Edema, calabar swellings.	Diethylcarbama- zine.
Mansonelliasis, dipetalonemiasis.	<u>Mansonella</u> <u>streptocerca</u> (blood and tissue round- worm)	Wrinkling of the skin, itching.	Cutaneous edema.	Diethylcarbama- zine.
Dirofilariasis	<u>Dirofilaria</u> <u>immitus</u> (blood and tissue round worm)	Cough, chest pain.	Infarcted lung lesions; nodules in various sites.	Diethylcarbama- zine, Surgical removal.
Dracunculiasis, dracontiasis.	<u>Dracunculus</u> <u>medinensis</u> (tissue roundworm)	Urticaria, erythema, dyspnea, vomiting, pruritis.	Eosinophilia, subcutaneous blisters, edema, abscesses, extensive ulce- ration, necrosis.	Removal of adult (Xray to Locate). Thiabendazole. Niridazole.
ACANTHOCEPHALID INFECTIONS				
Acanthocephalitis, acanthocephali- asis.	<u>Macracantho-</u> <u>rhynchus</u> <u>hirudinaceus</u> (Thorny- headed roundworm)	Vague abdominal cramps.	Inflammation of the intestinal mucosa.	Oleoresin of aspidium, Mebendazole (children).

End of Appendix A

APPENDIX B

REFERENCES

This subcourse can provide you with a basic background/review of parasitology. During your study of the subcourse, you may identify topics which greatly interest you or pertain especially to your job. In these cases, you may wish to perform an in depth study on that topic on your own.

This APPENDIX is a listing of references which might prove useful to you as you begin these learning efforts. You must evaluate each reference in terms of the level it is written, the amount of technical language it uses, and how current the information it contains is.

Belding, D. L. Textbook of Parasitology, 3d ed. New York: Appleton-Century-Crofts, Inc., 1965.

Brooke, M. M. and Melvin, D. M. Common Intestinal Protozoa of Man; Life Cycle Charts. Public Health Service Publication No. 1140, U.S. Government Printing Office, Washington, D.C., reprinted 1976.

Brown, H. W. and Neva, F. A. Basic Clinical Parasitology, 5th ed. Norwalk, Conn.: Appleton-Century-Crofts, Inc., 1983.

Cheng, T. C. General Parasitology, New York: Academic Press, Inc., 1973.

Faust, E. C., Beaver, P. C. and Jung, R. C. Animal Agents and Vectors of Human Disease, 4th ed. Philadelphia: Lea and Febiger, 1975.

Faust, E. C., Russell, P. F. and Jung, R. C. Craig and Faust's Clinical Parasitology, 8th ed. Philadelphia: Lea and Febiger, 1970.

Garnham, P. C. C. Malaria Parasites and Other Haemosporidia, Oxford: Blackwell Scientific Publications, 1966.

GR 72-198-3, Medical Entomology, U.S. Army Medical Field Service School,

Hunter, G. W., III, Frye, W. W., and Swartzwelder, J. C. A Manual of Tropical Medicine, 4th ed. Philadelphia: W. B. Saunders, 1966.

Kenny, M. Scope Monograph on Pathoparasitology. Kalamazoo, Michigan: Upjohn Company, 1973.

Lapage, G. Monig's Veterinary Helminthology and Entomology, 5th ed. Baltimore: Williams and Wilkins Company, 1962.

Lennette, Edwin, et. al. Manual of Clinical Microbiology, 3rd ed. Washington, D.C.: American Society for Microbiology, 1980.

Markell, E. K. and Voge, M. Medical Parasitology, 5th ed. Philadelphia: W. B. Saunders, 1981.

Medical Protozoology and Helminthology, U.S. Naval Medical School, National Naval Medical Center, Bethesda, Maryland, U. S. Government Printing Office Washington, D.C., 1965.

Melvin, D. M. and Brooke, M. M. Laboratory Procedures for the Diagnosis of Intestinal Parasites, U.S. Department of H. E. W., Public Health Services, Public Health Service Publication No. 1969, U.S. Government Printing Office, Washington, D.C., 1969.

Noble, E. R. and Noble, G. A. Parasitology, The Biology of Animal Parasites, 5th ed. Philadelphia: Lea and Febiger, 1982.

Schmidt, G. P. and Roberts, L. S. Foundations of Parasitology, St. Louis : C. V. Mosby, 1977.

Spencer, F. M. and Monroe, L. S. The Color Atlas of Intestinal Parasites, revised ed. Springfield, Illinois: Charles C. Thomas, 1975.

Washington, John A. Laboratory Procedures in Clinical Microbiology, New York: Springer Verlag, 1981.

Wilcox, A. Manual for the Microscopical Diagnosis of Malaria in Man, U.S . Department of H. E. W., Public Health Service Publication No. 796, U. S. Government Printing Office, Washington, D.C., 1960.

Yamaguchi, T. Color Atlas of Clinical Parasitology, Philadelphia: Lea and Febiger, 1981.

End of Appendix B

MEDICAL PARASITOLOGY

APPENDIX C

Color Plates - Plasmodium species

Table of Contents

Plasmodium vivax.

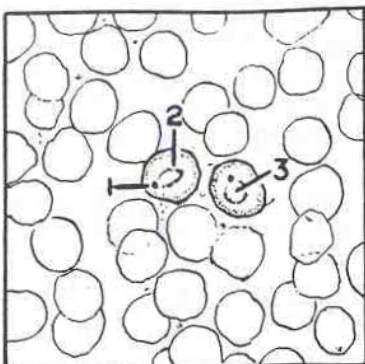
Plasmodium ovale.

Plasmodium malariae.

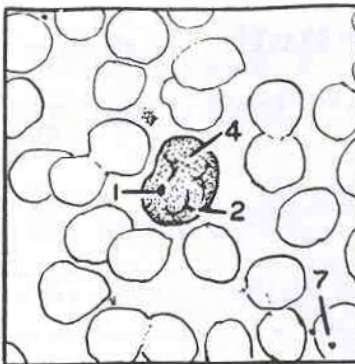
Plasmodium falciparum.

PLASMODIUM VIVAX

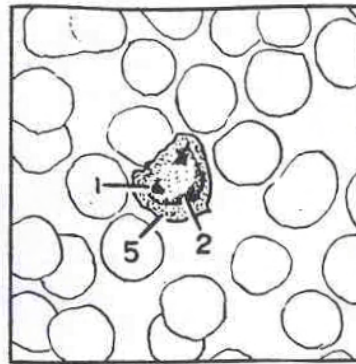
PLATE 1



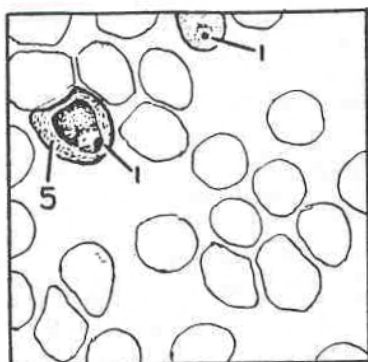
1-1 ring forms



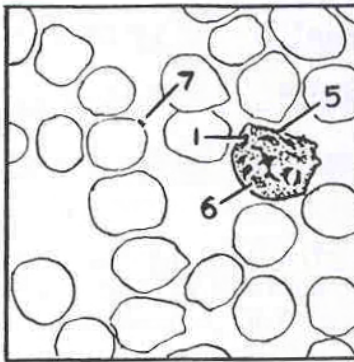
1-2 amoeboid trophozoite



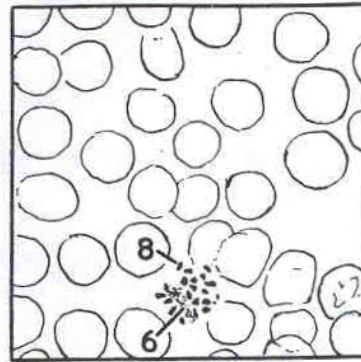
1-3 growing trophozoite



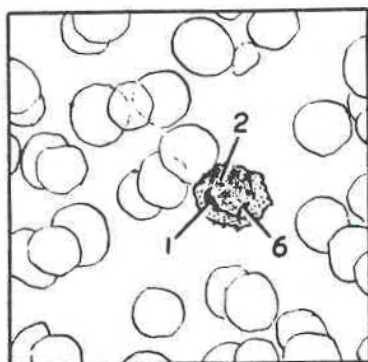
1-4 mature trophozoite



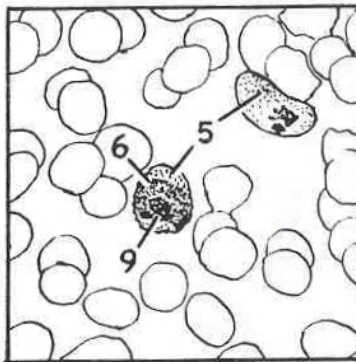
1-5 immature schizont



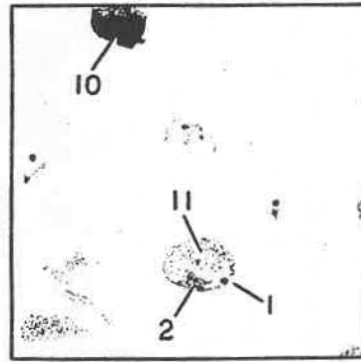
1-6 mature schizont



1-7 macrogametocyte



1-8 microgametocyte

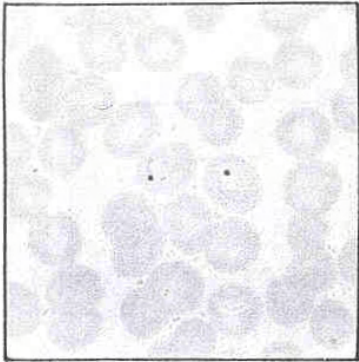


1-9 thick smear


LEGEND

- | | |
|------------------------------------|--------------------------------|
| 1. nuclear chromatin (condensed) | 7. artifact |
| 2. cytoplasm of parasite (ameboid) | 8. merozoites (17) |
| 3. vacuole | 9. diffused chromatin |
| 4. enlarged RBC (pale) | 10. nucleus of WBC |
| 5. Schuffner's granules | 11. ghost of RBC (Schuffner's) |
| 6. hemozoin pigment | |

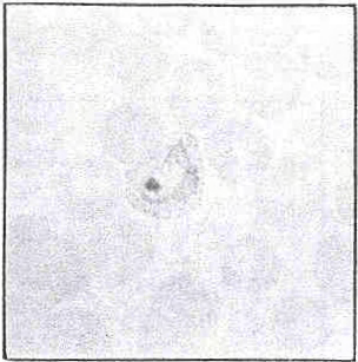PLASMODIUM VIVAX
PLATE 1




1-1 ring forms



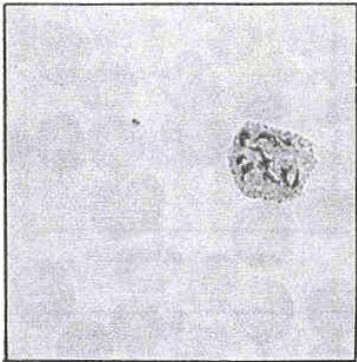
1-2 amoeboid trophozoite



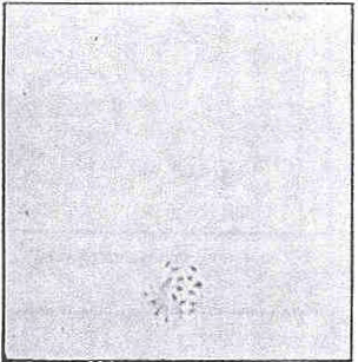
1-3 growing trophozoite



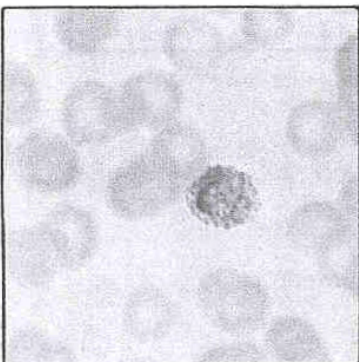
1-4 mature trophozoite



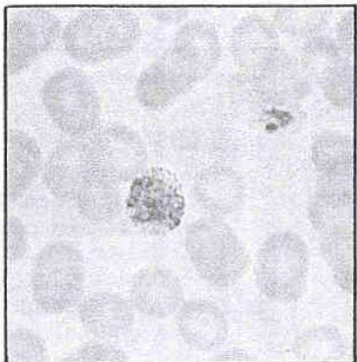
1-5 immature schizont



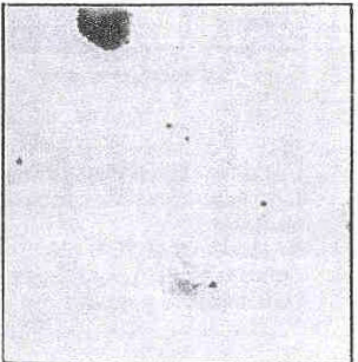1-6 mature schizont



1-7 macrogametocyte

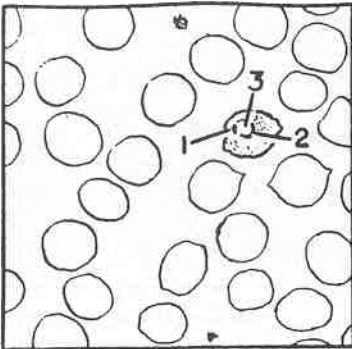


1-8 microgametocyte

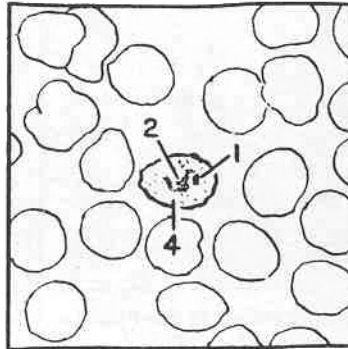


1-9 thick smear

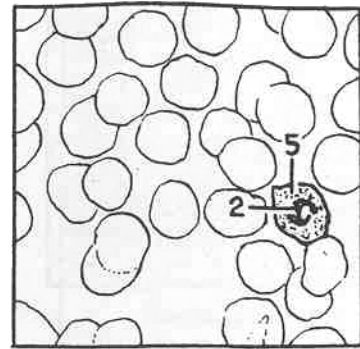
PLASMODIUM OVALE PLATE 2



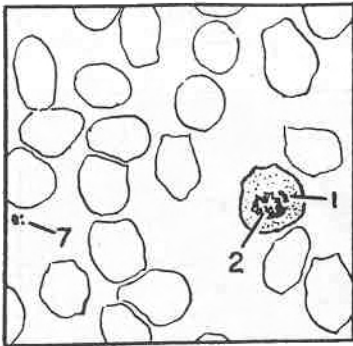
2-1 ring form



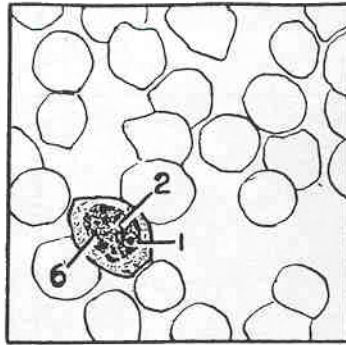
2-2 growing trophozoite



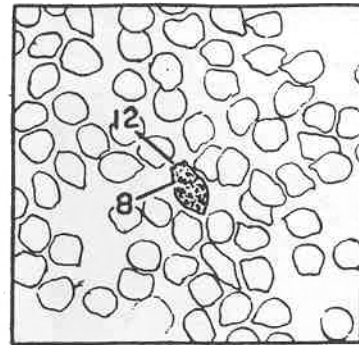
2-3 growing trophozoite



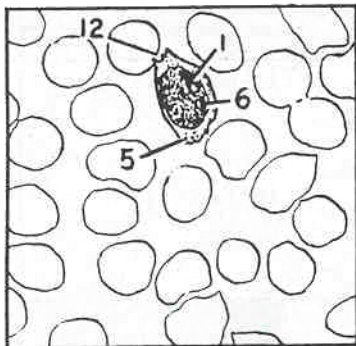
2-4 mature trophozoite



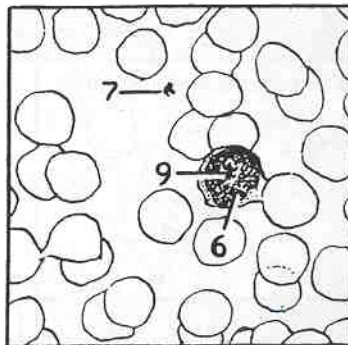
2-5 immature schizont



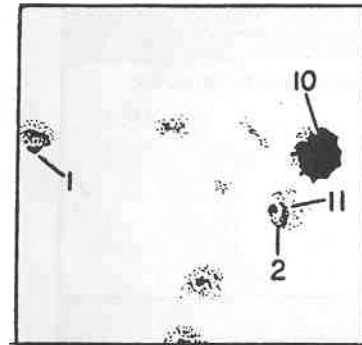
2-6 mature schizont



2-7 macrogametocyte



2-8 microgametocyte

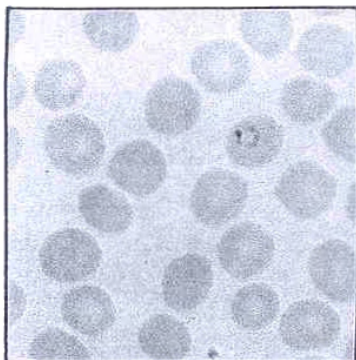


2-9 thick smear

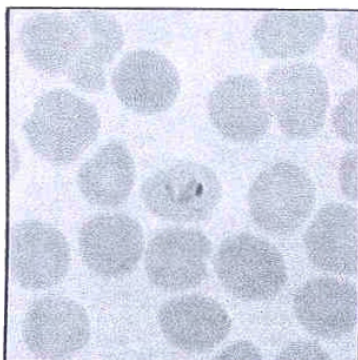
LEGEND

- | | |
|------------------------------------|--------------------------------|
| 1. nuclear chromatin (condensed) | 7. platelets |
| 2. cytoplasm of parasite (compact) | 8. merozoites (8) |
| 3. vacuole | 9. diffused chromatin |
| 4. typical oval RBC | 10. nucleus of WBC |
| 5. Schuffner's granules (course) | 11. ghost of RBC (Schuffner's) |
| 6. hemozoin pigment | 12. fimbriation |


PLASMODIUM OVALE
PLATE 2



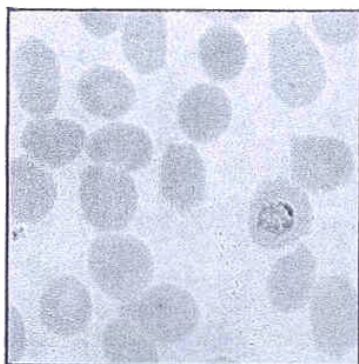
2-1 ring form



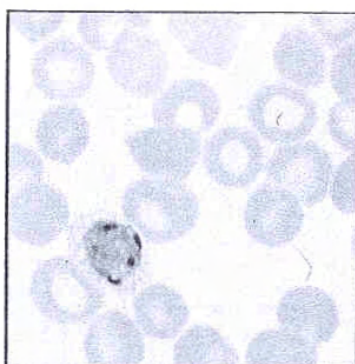
2-2 growing trophozoite



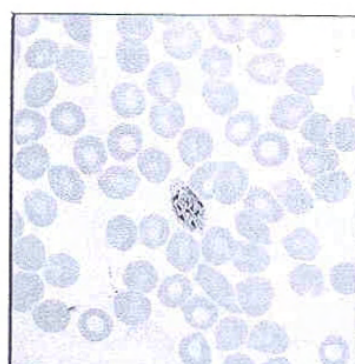
2-3 growing trophozoite



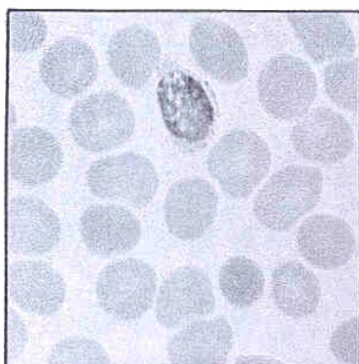
2-4 mature trophozoite



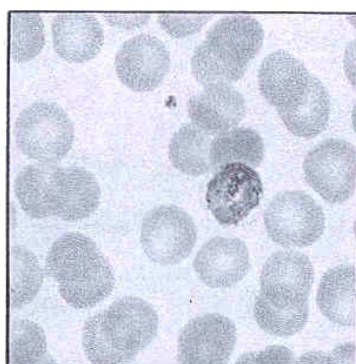
2-5 immature schizont




2-6 mature schizont



2-7 macrogametocyte



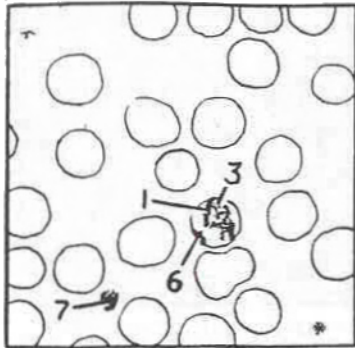
2-8 microgametocyte



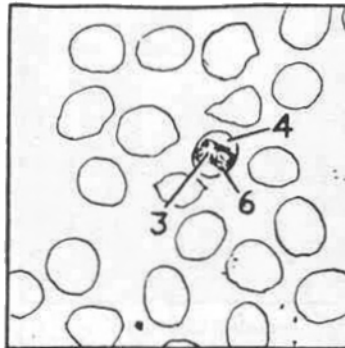
2-9 thick smear

PLASMODIUM MALARIAE

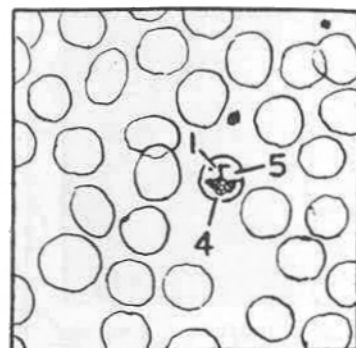
PLATE 3



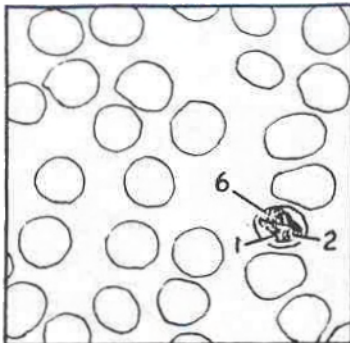
3-1 growing trophozoite



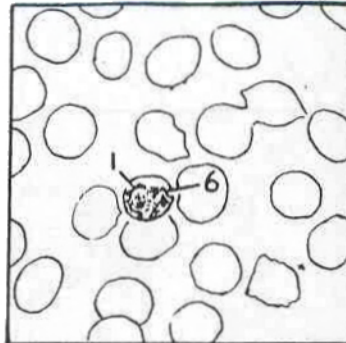
3-2 band form



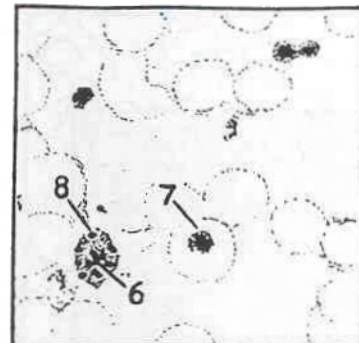
3-3 basket form



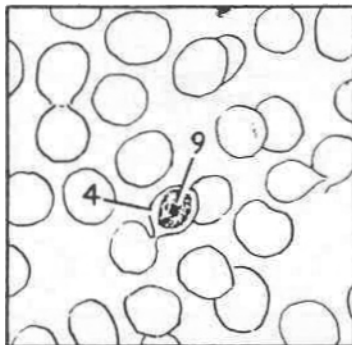
3-4 mature trophozoite



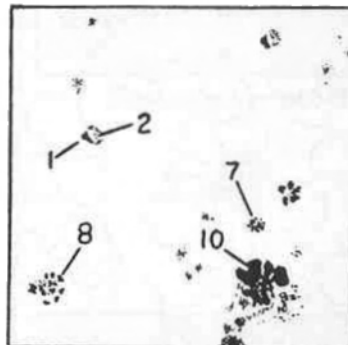
3-5 immature schizont



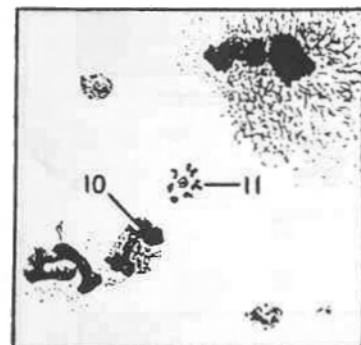
3-6 mature schizont



3-7 microgametocyte



3-8 thick smear

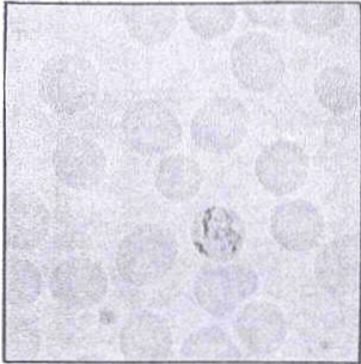


3-9 thick smear

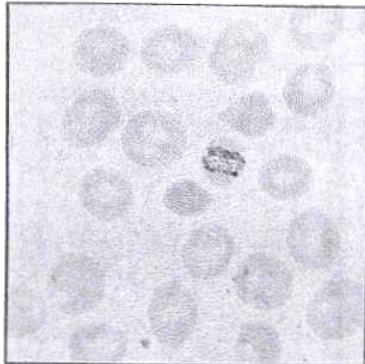
LEGEND

- | | |
|------------------------------------|------------------------------------|
| 1. nuclear chromatin | 7. platelets |
| 2. cytoplasm of parasite (compact) | 8. merozoites (8-10) |
| 3. vacuole indistinct | 9. diffused chromatin |
| 4. infected RBC (microcytic) | 10. nucleus of WBC |
| 5. RBC normal palor | 11. schizont (rosette arrangement) |
| 6. hemozoin pigment (dark) | |

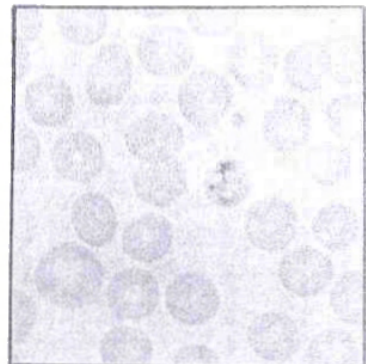
PLASMODIUM MALARIAE
PLATE 3



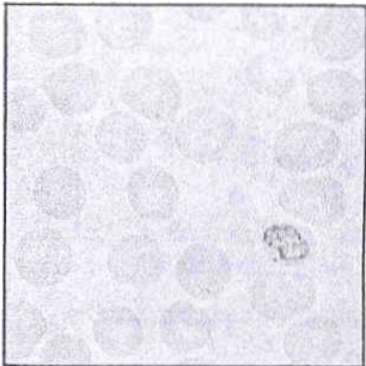
3-1 growing trophozoite



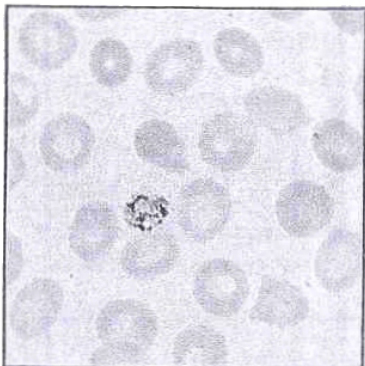
3-2 band form



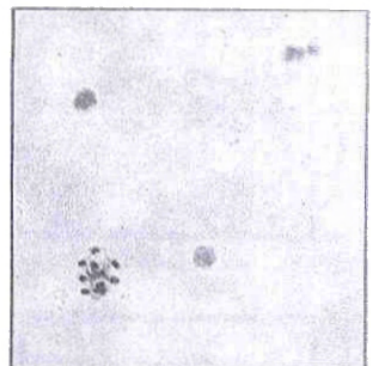3-3 basket form



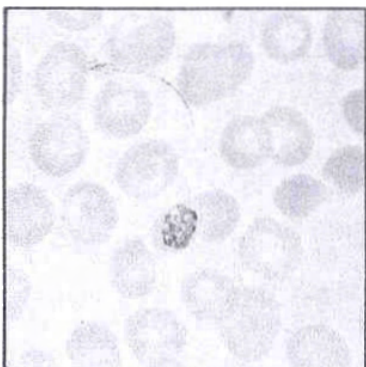
3-4 mature trophozoite



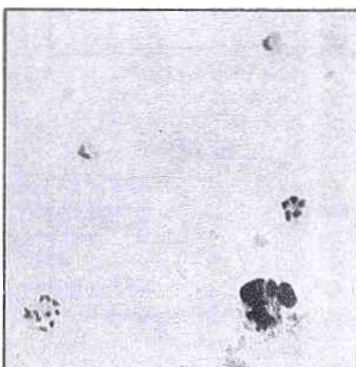3-5 immature schizont



3-6 mature schizont



3-7 microgametocyte



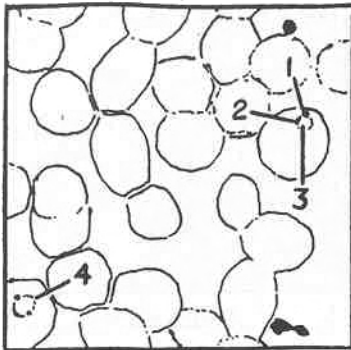
3-8 thick smear



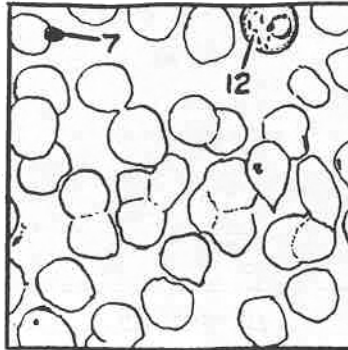
3-9 thick smear

PLASMODIUM FALCIPARUM

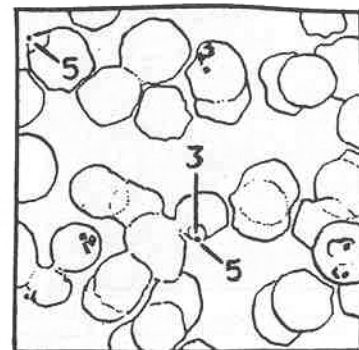
PLATE 4



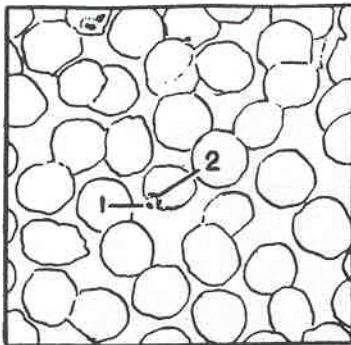
4-1 ring forms



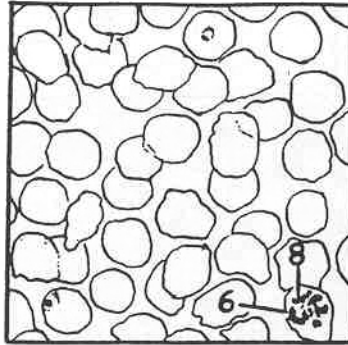
4-2 older ring forms



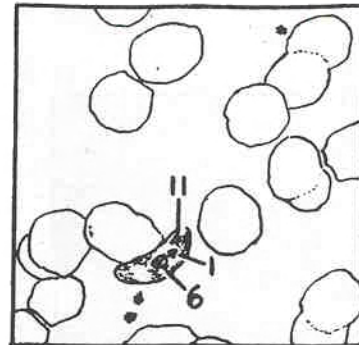
4-3 many ring forms



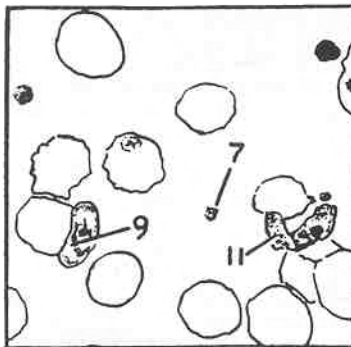
4-4 trophozoites



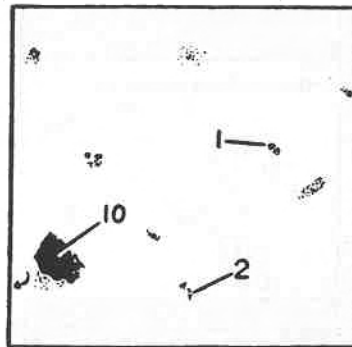
4-5 immature schizont



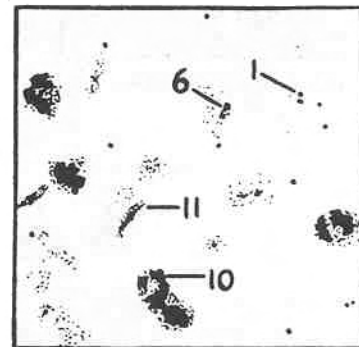
4-6 macrogametocyte



4-7 microgametocyte



4-8 thick smear




4-9 thick smear


LEGEND

- | | |
|-------------------------------------|-----------------------------------|
| 1. nuclear chromatin ((small) | 7. platelet |
| 2. cytoplasm of parasite (delicate) | 8. merozoites (8-32) |
| 3. vacuole | 9. diffused chromatin |
| 4. double signet ring | 10. nucleus of WBC |
| 5. applique or accolé' form | 11. crescentic shape (diagnostic) |
| 6. hemozoin pigment (dark) | 12. Maurer's clefts |


PLASMODIUM FALCIPARUM
PLATE 4




4-1 ring forms




4-2 older ring forms



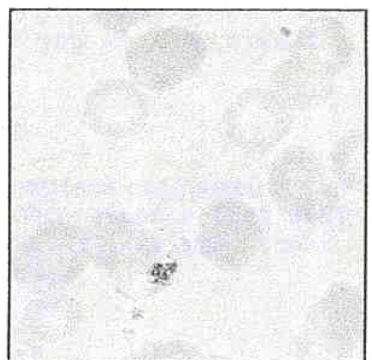
4-3 many ring forms



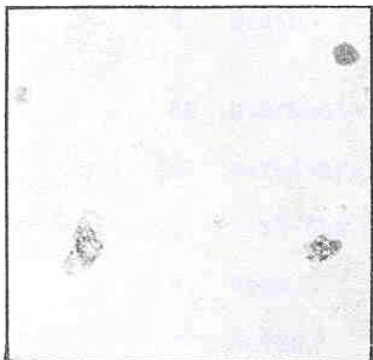
4-4 trophozoites




4-5 immature schizont



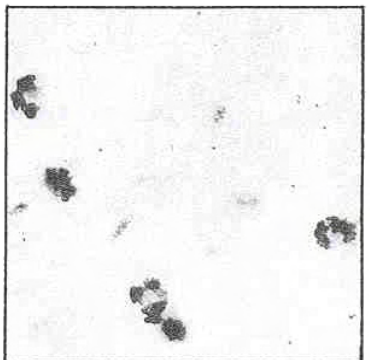
4-6 macrogametocyte



4-7 microgametocyte



4-8 thick smear



4-9 thick smear

End of Appendix C